

OPINIONI A CONFRONTO IN CARDIOLOGIA. INSUFFICIENZA VALVOLARE AORTICA: RECENTI TENDENZE TERAPEUTICHE E RUOLO DELL'ECOCARDIOGRAFIA.

Dott. Alessandro Cialfi
U.O. Cardiologia
Azienda Osp. "L.Sacco"
MILANO



RIPARAZIONE VALVOLARE

La chirurgia riparativa della valvola **mitrale** è tecnica diffusamente accettata nell'IM da degenerazione mixomatosa e seppure con "luci e ombre" nell'IM ischemica e reumatica.

La riparazione della valvola **aorta** sembrava confinata a interventi saltuari per es. IAO secondaria a dissezione aortica e a DIV con prollasso cuspidi AO dx. Negli ultimi anni alcuni centri hanno ampliato queste indicazioni coinvolgendo di conseguenza il cardiologo-ecocardiografista



IMPORTANZA DIMENSIONI AORTA ASCENDENTE

Nel corso degli ultimi decenni si è giunti alla conclusione che le dimensioni dell'aorta ascendente, oltre all'entità del reflusso aortico, in alcune patologie (Ao bic e dilatazione della radice aortica nella S. di Marfan) possono essere un elemento rilevante nella storia clinica dei pazienti (rottura, dissezione, morte)

Anche un diametro Ao Asc di 40 mm soprattutto in soggetti con sup corporea ridotta merita attenzione.



METODO DI STUDIO DELL'APPARATO VALVOLARE

ECOGRAFIA TRANSTORACICA

ECOGRAFIA TRANSESOFOGEEA

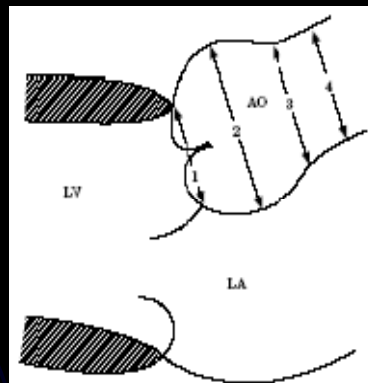
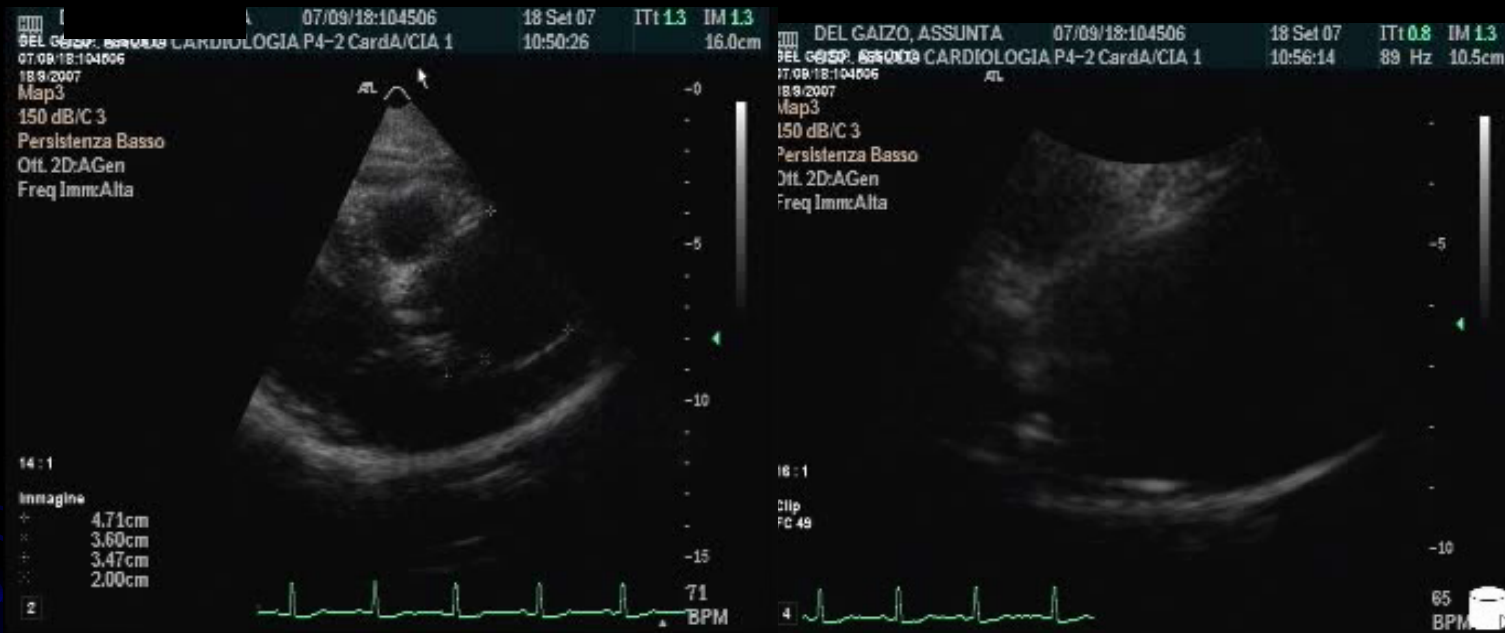TAC

RNM

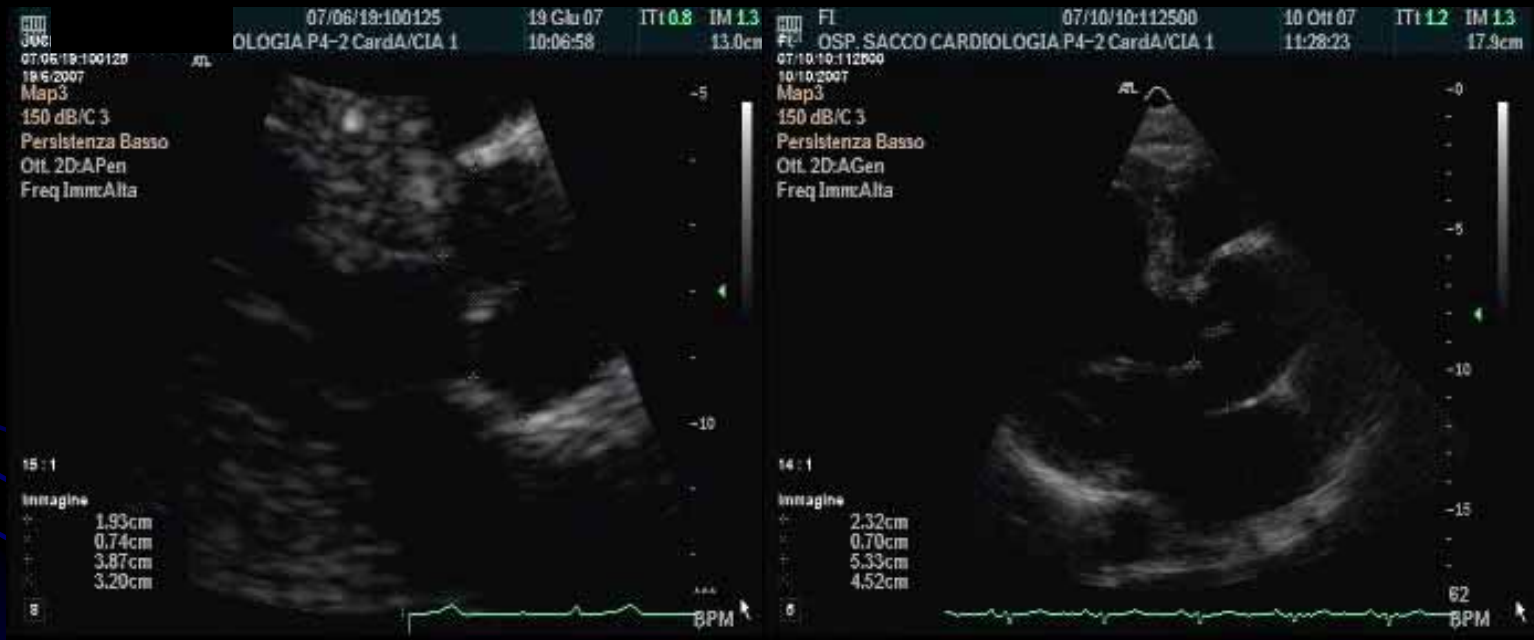

ECOGRAFIA TRANSTORACICA

MISURE PRICIPALI



ECOGRAFIA: MISURE PRICIPALI

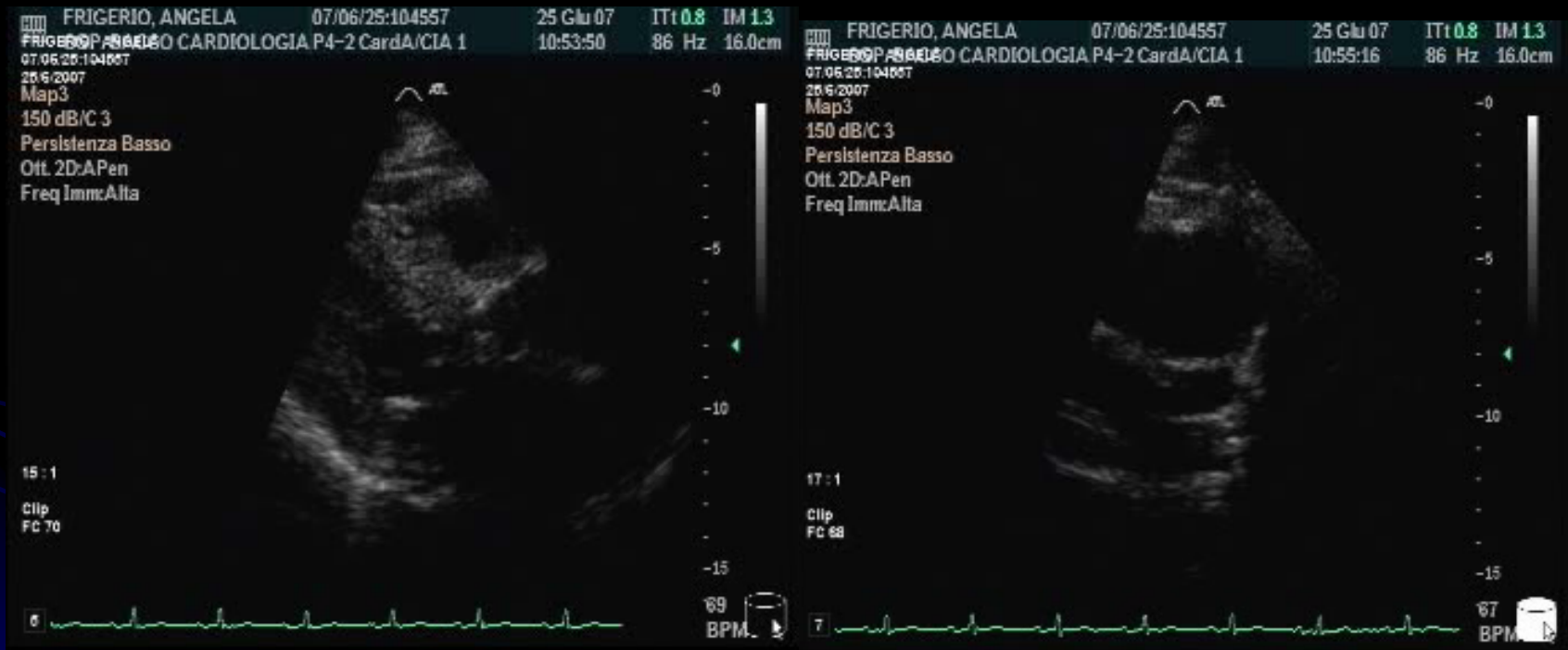

DIAM ANULUS AOR
DIAM SENI VALSALVA
DIAM GIUNZIONE S.TUB

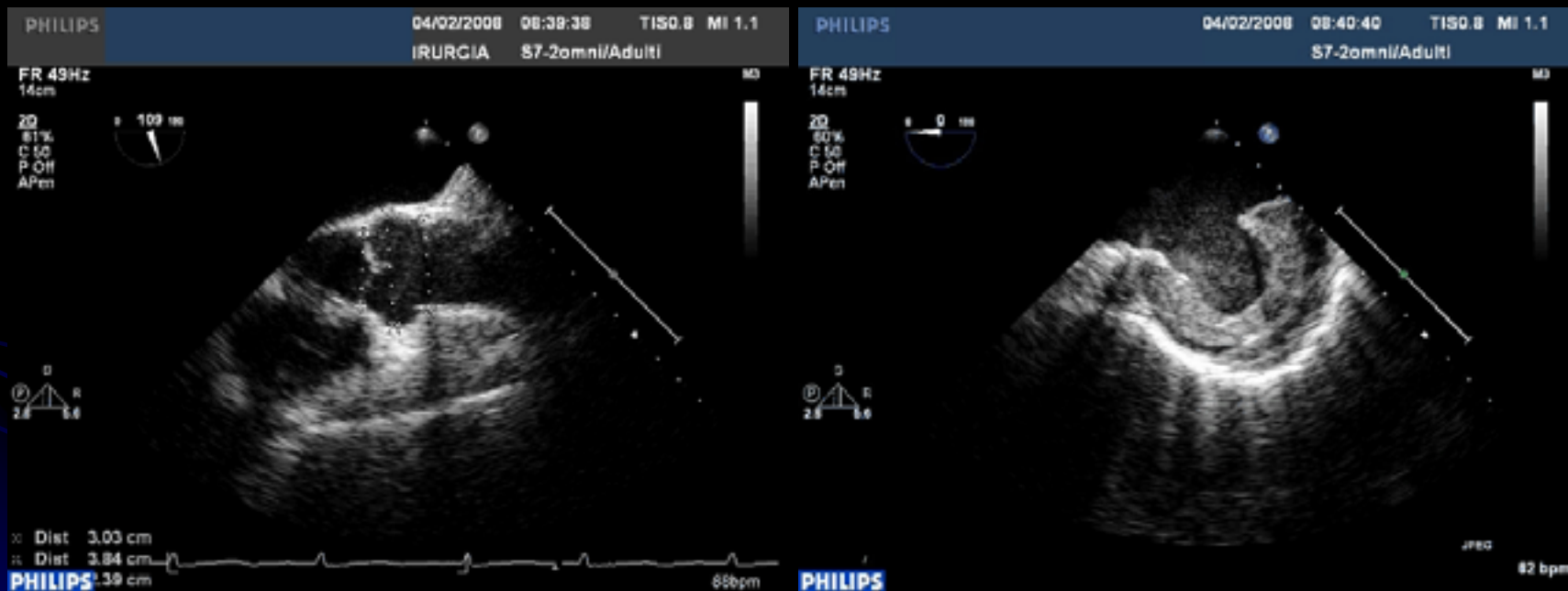DIAM MAX AO ASC
(RAPPORTO SUP CORP)
COAPTAZIONE LEMBI



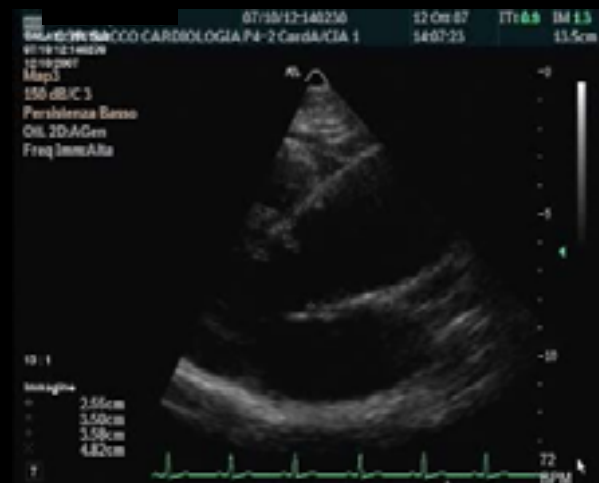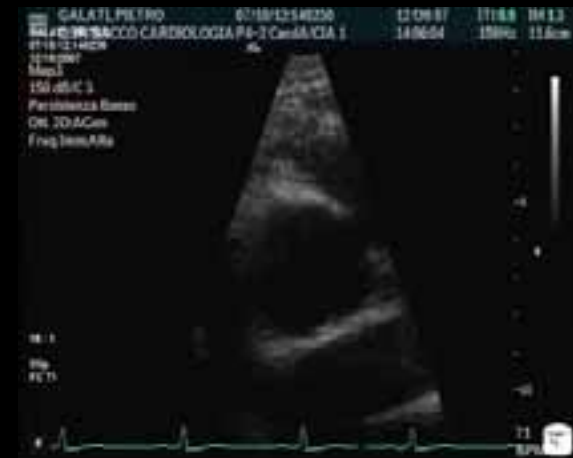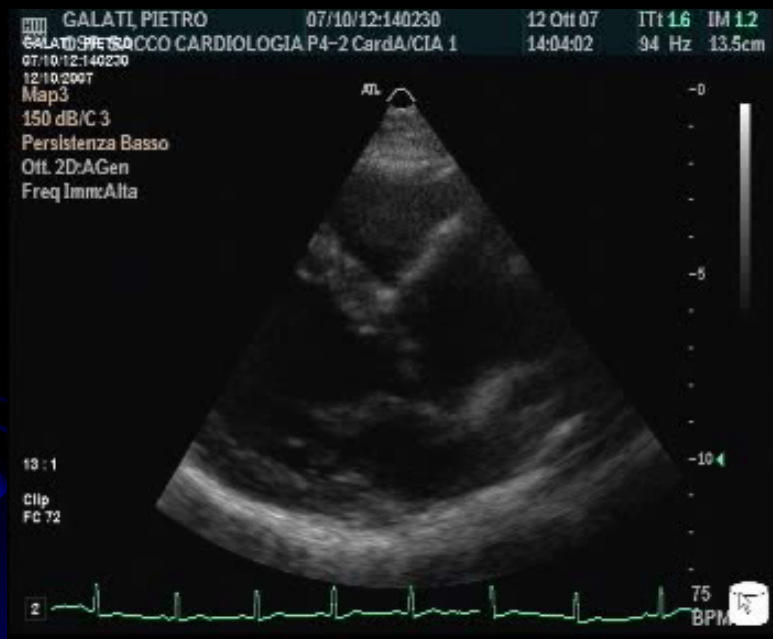LIMITI DELLO STUDIO ARCO AORTICO MEDIANTE ECO TTE



LIMITI DELLO STUDIO ARCO AORTICO MEDIANTE ECO TTE

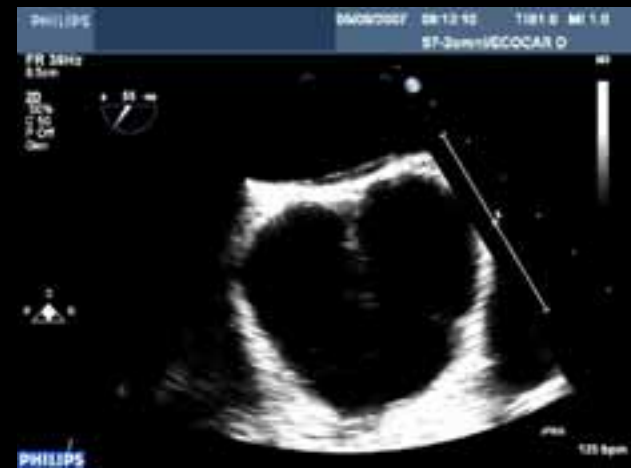
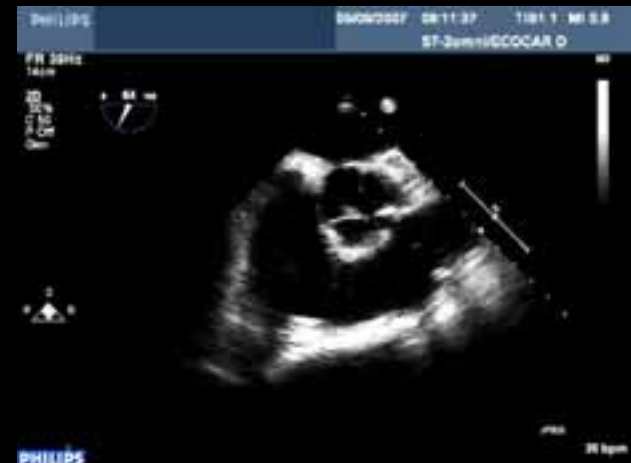
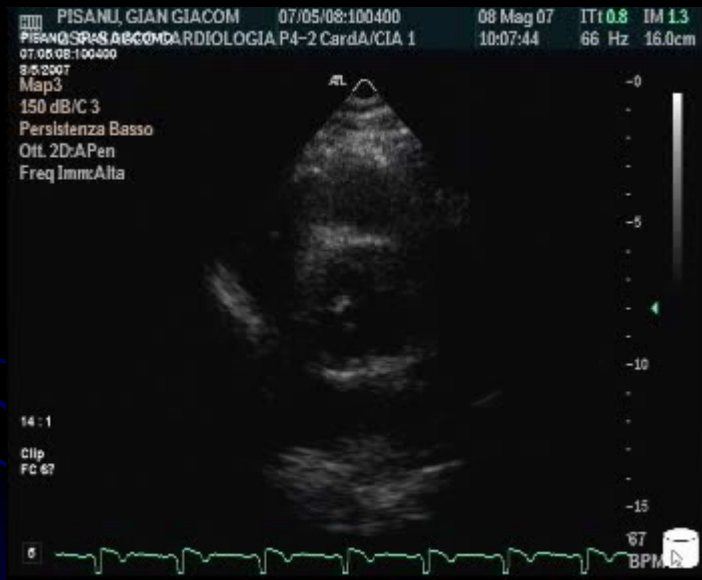VALVOLA AORTA BICUSPIDE



RICONOSCIMENTO V BICUSPIDE

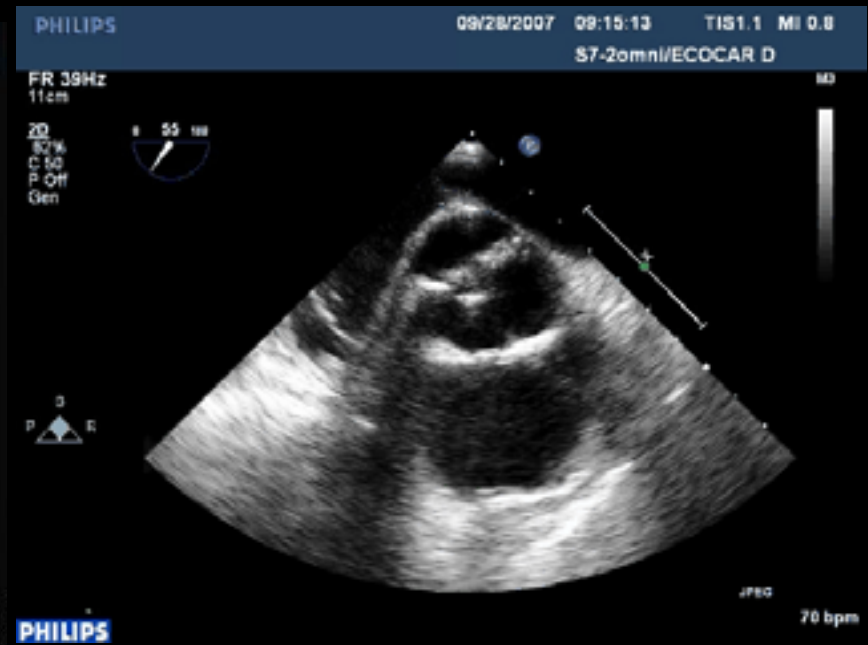
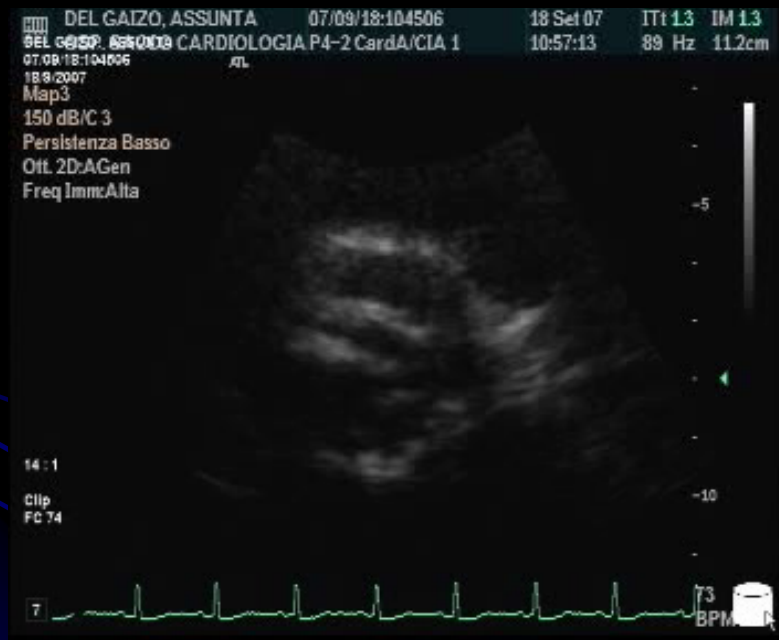
TTE: V BICUSPIDE?



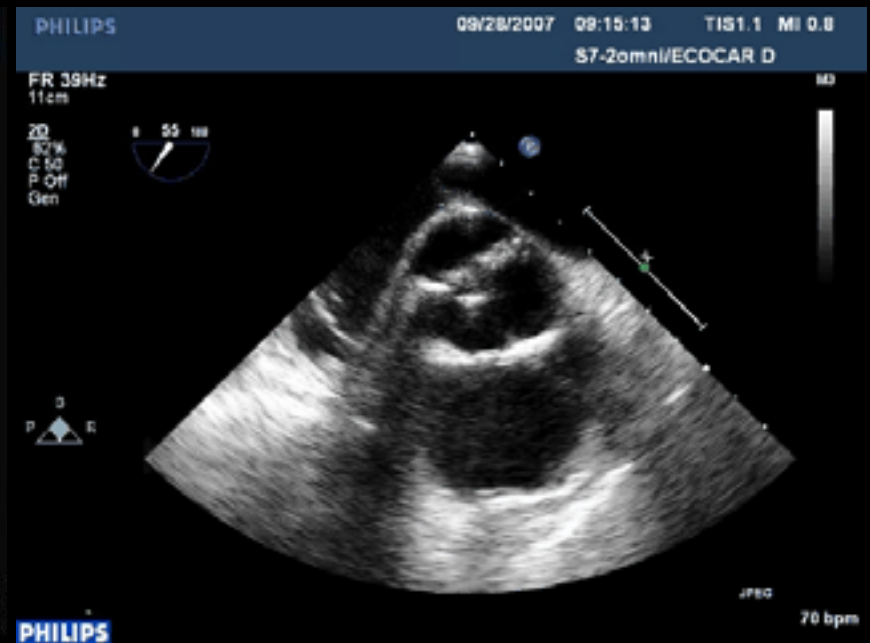
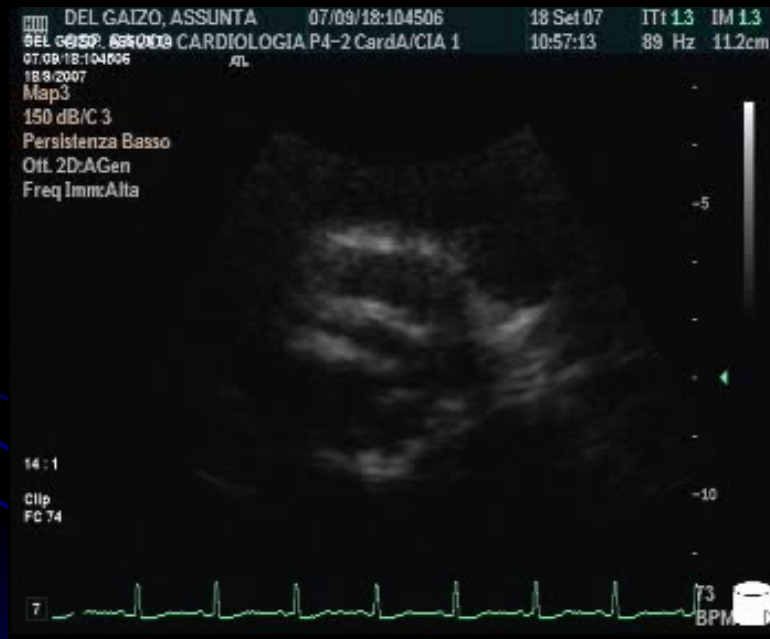←
T
E
E
B
I
C
+
R
A
F
E



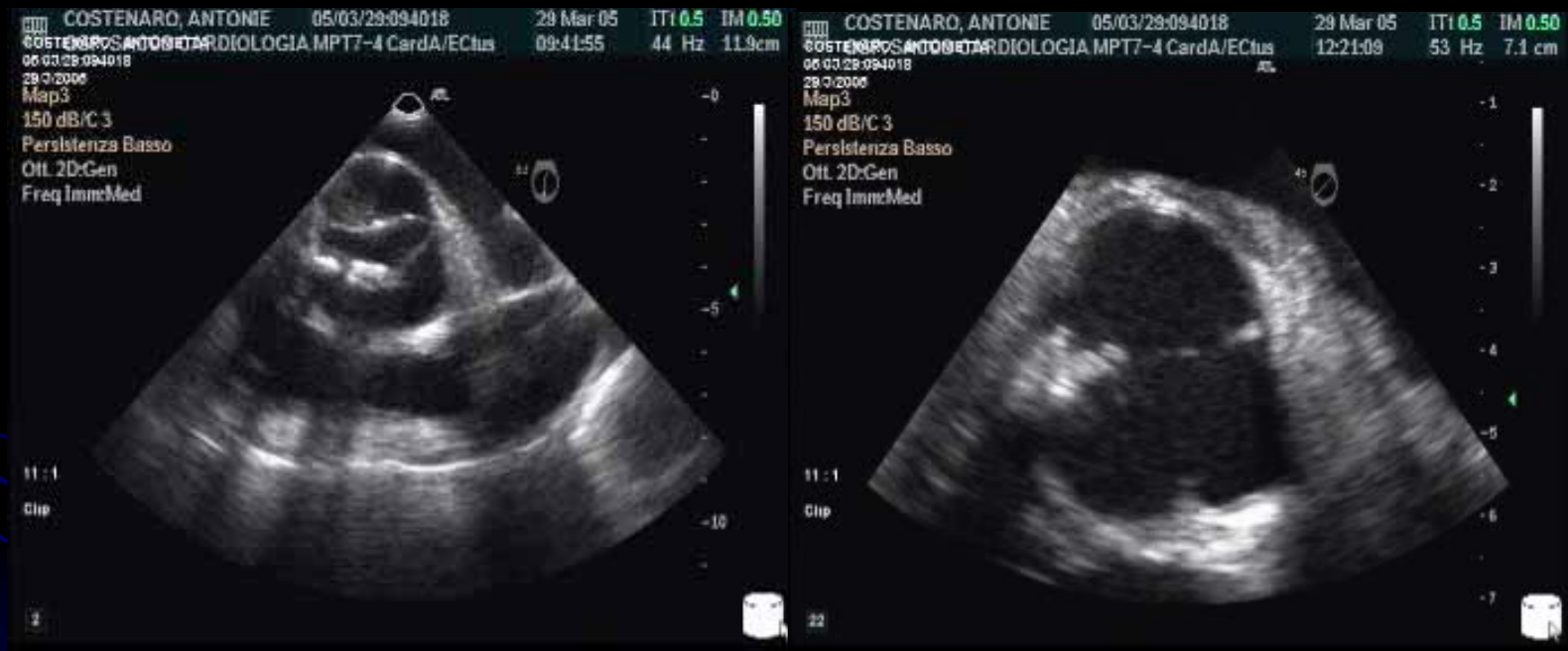RICONOSCIMENTO V BICUSPIDE



RICONOSCIMENTO V BICUSPIDE



VALVOLA AO BICUSPIDE



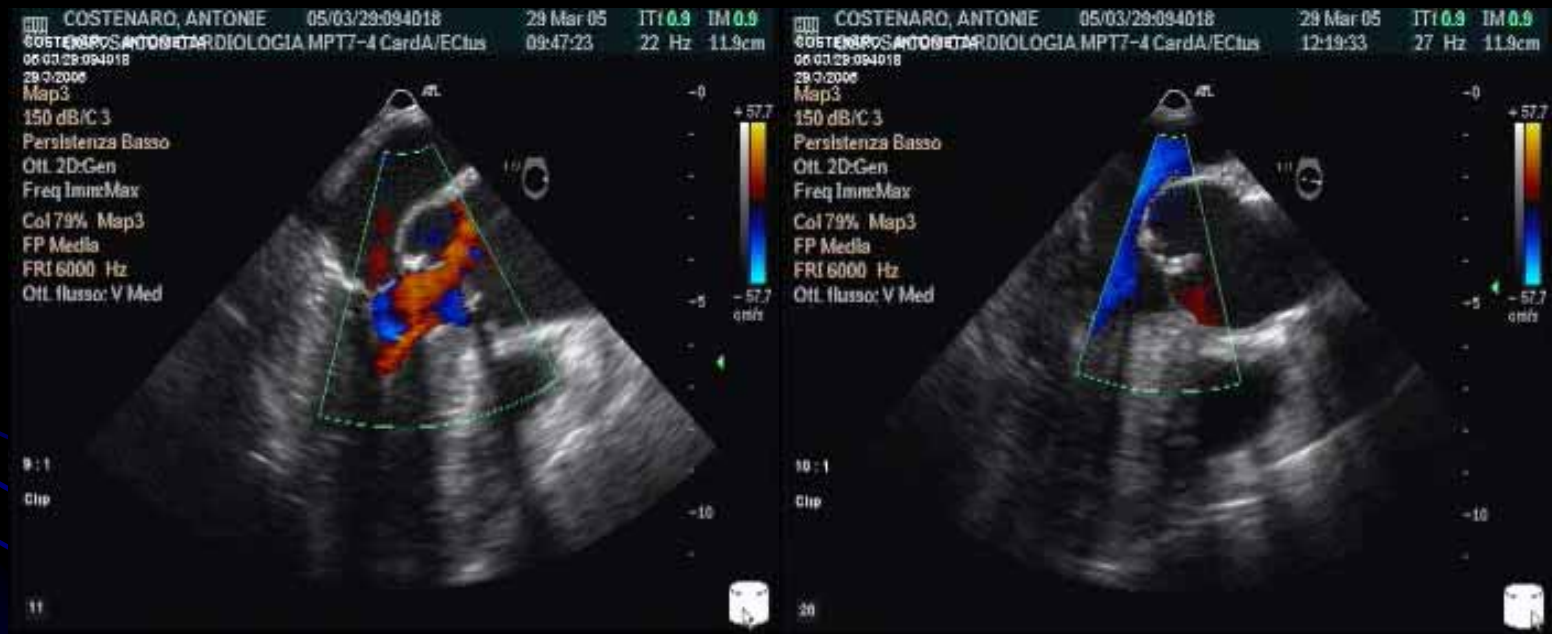VALVOLA AO BIC

RIPARAZIONE



**Fondazione
Don Carlo Gnocchi
Onlus**

VALVOLA AO BICUSPIDE

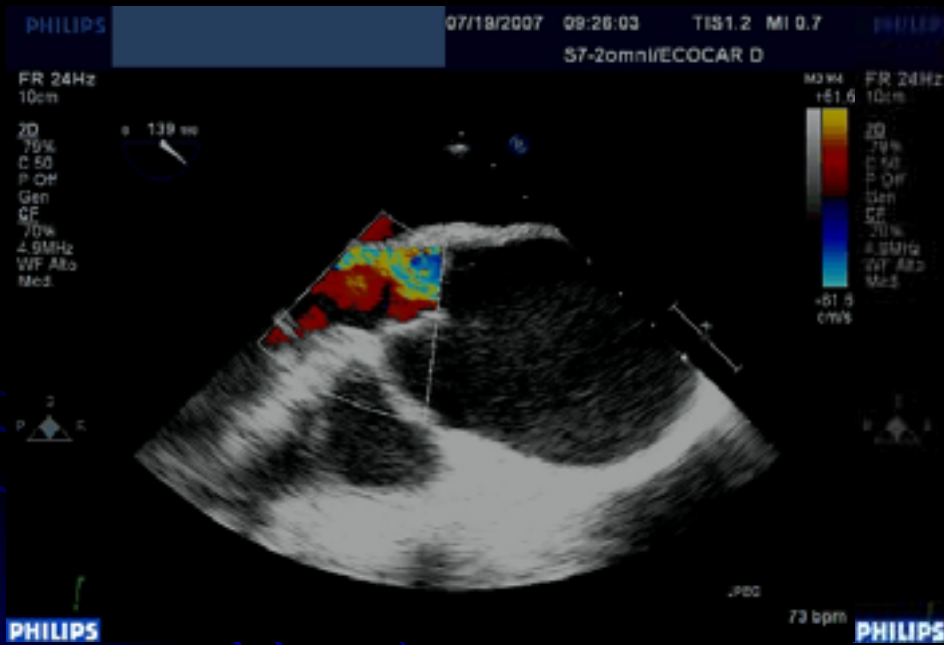


BASALE

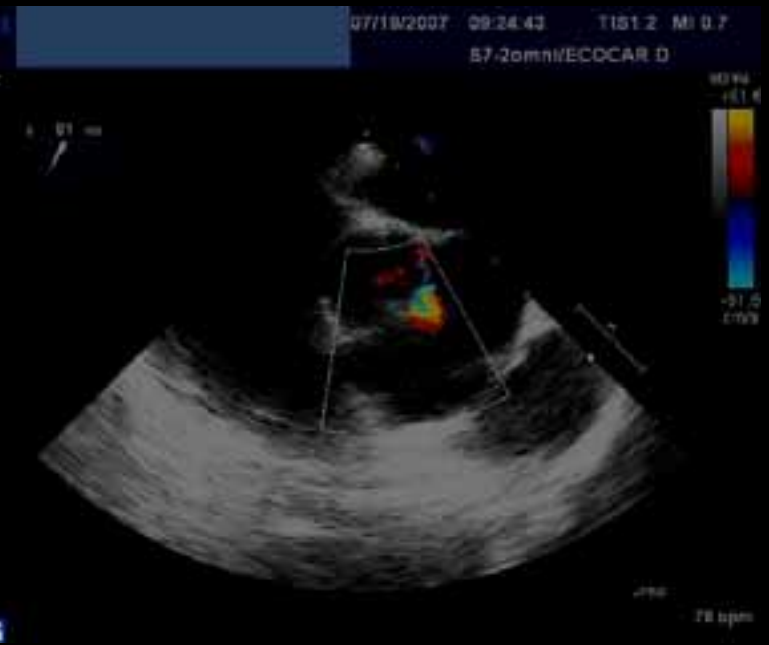RIPARAZIONE



MORFOLOGIA LEMBI, ORIGINE DEL JET

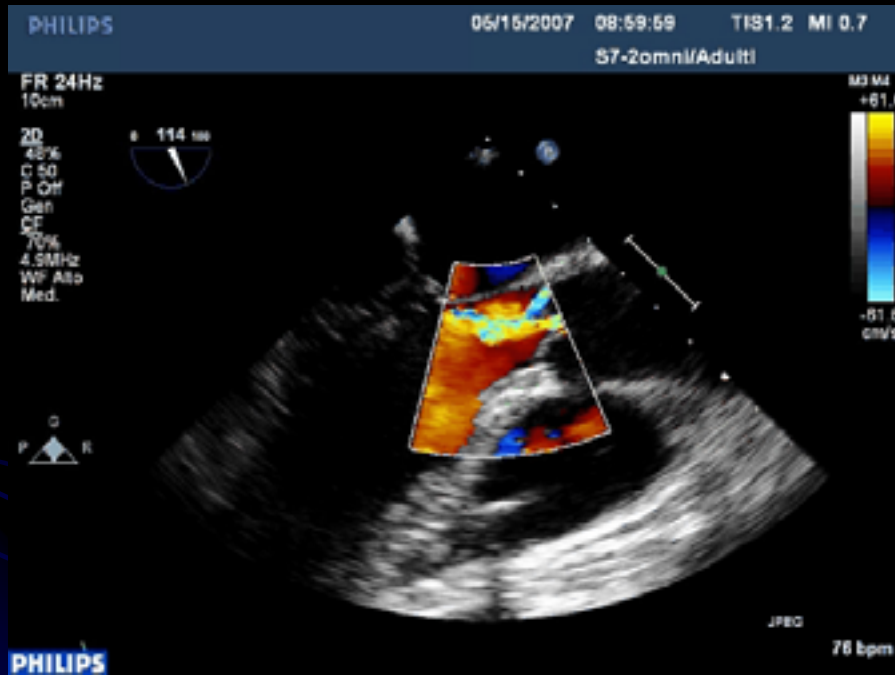


JET ECCENTRICO
DIRETTO VERSO LAM
COAPT 3-4 MM

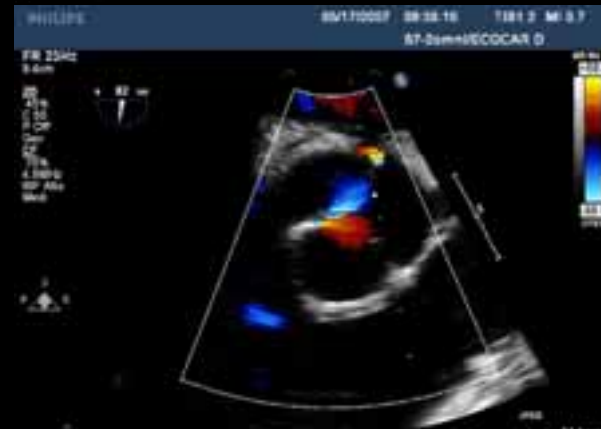


VALVOLA TRICUSPIDE CON
JET CENTRALE

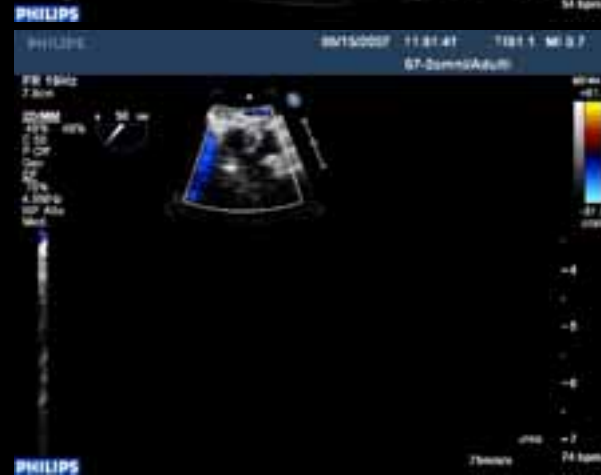ORIGINE JET REFLUSSO AORTICO



BASALE



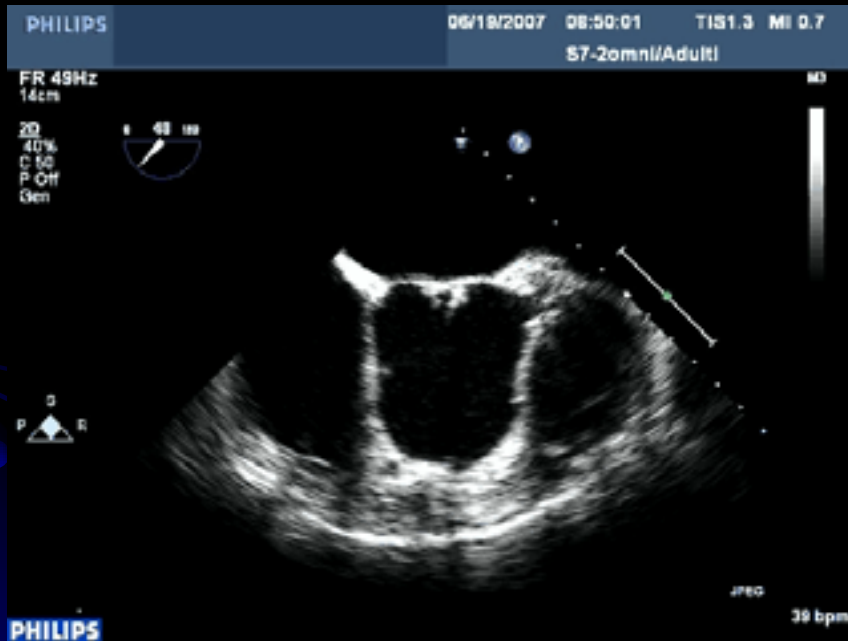
←
B
A
S



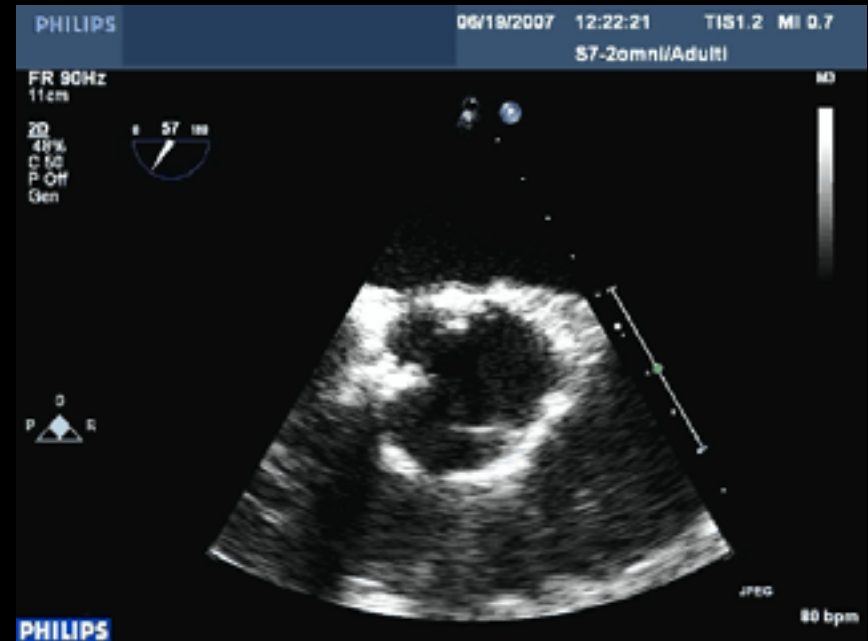
←
R
I
P



ASIMMETRIA SENI VALSALVA



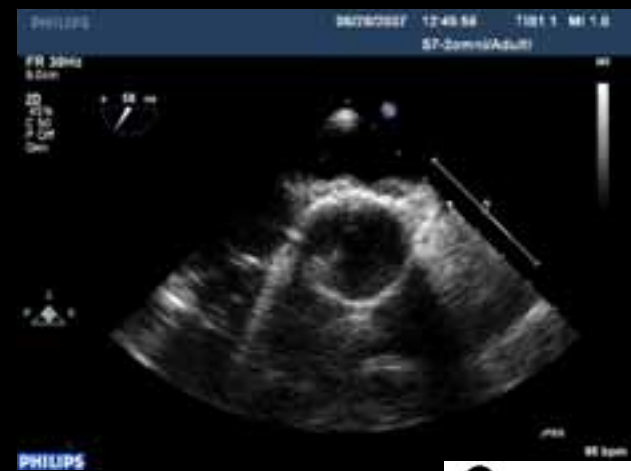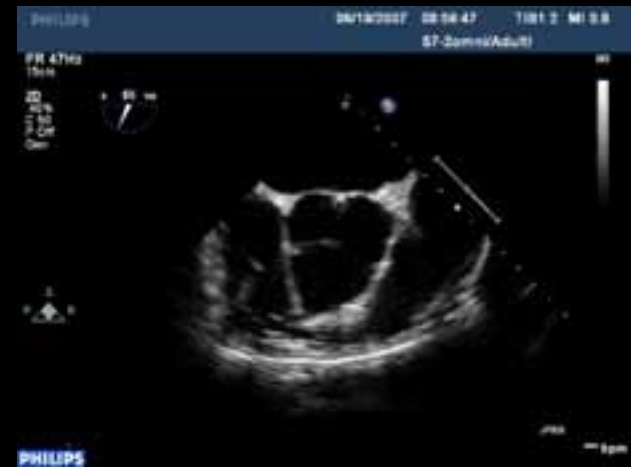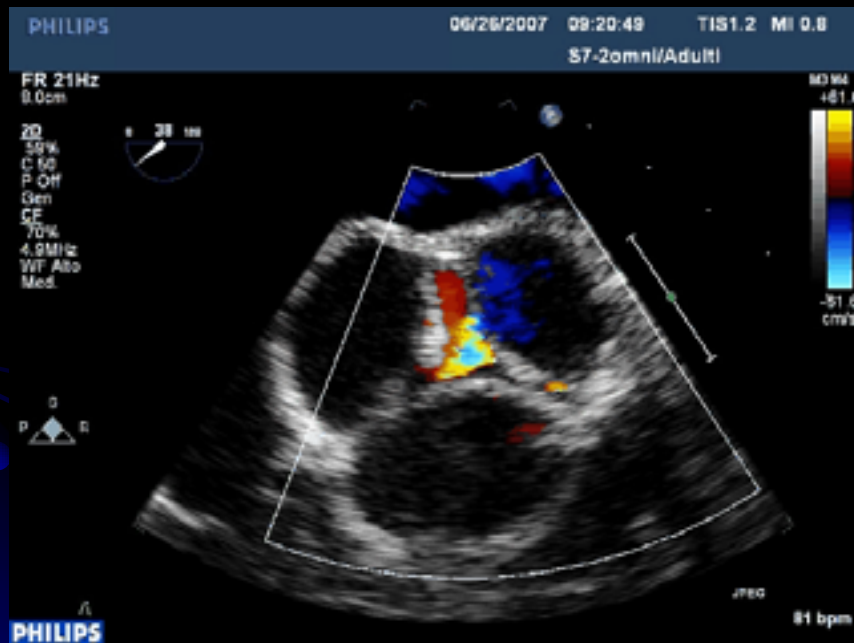
PRE RIP



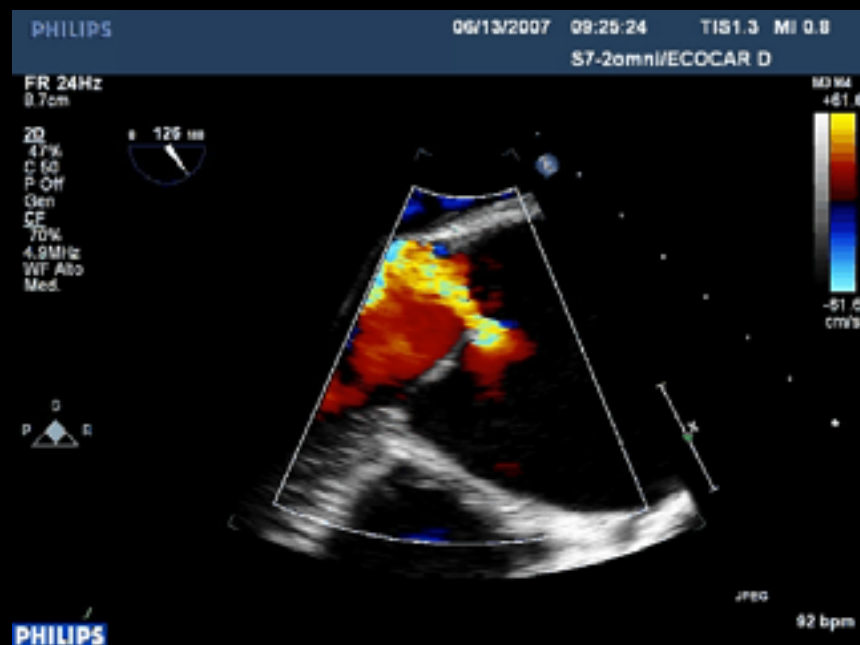
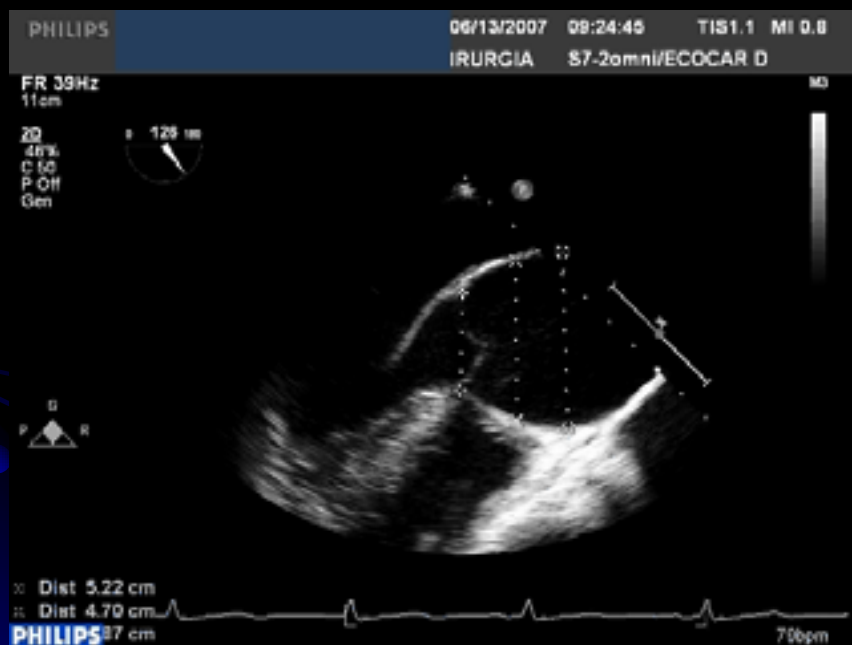
RIPARAZIONE



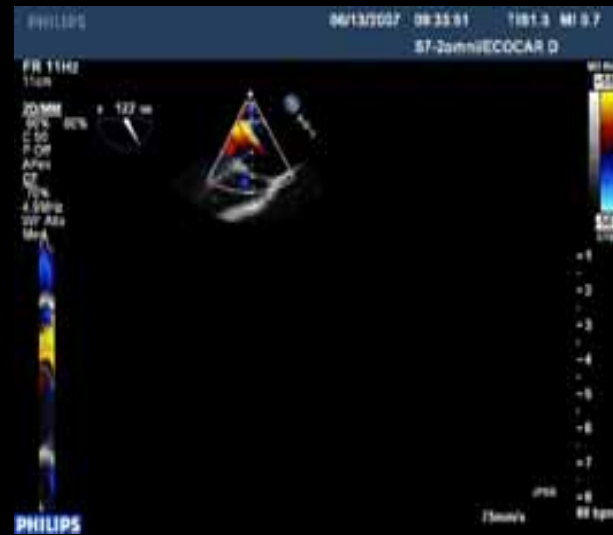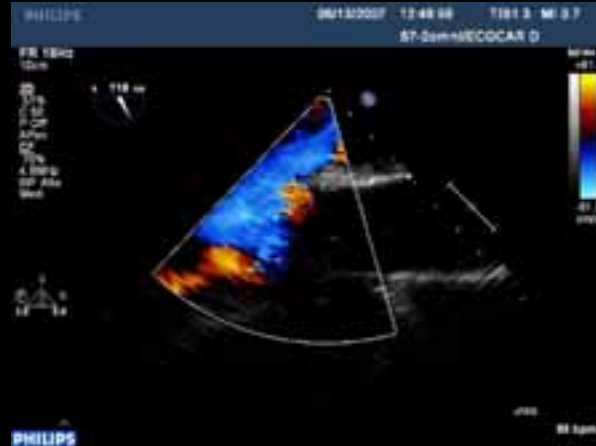
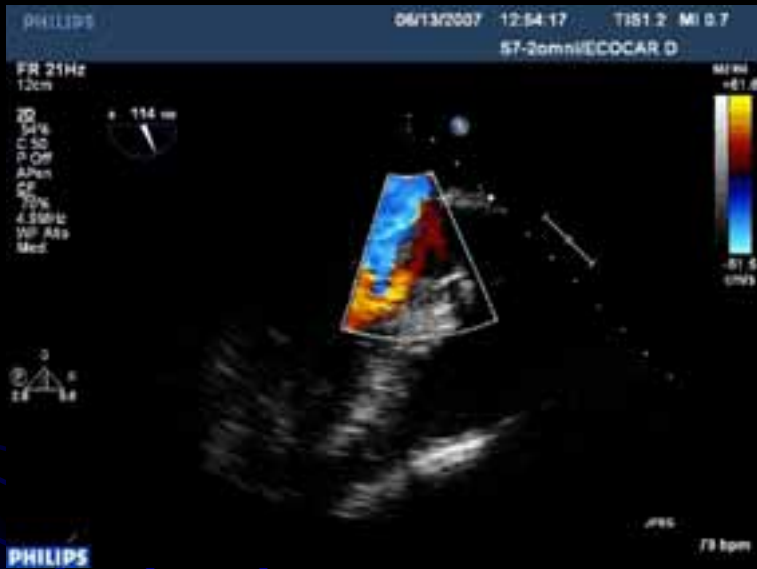ASIMMETRIA SENI VALSALVA



DILATAZIONE BULBO AORTICO



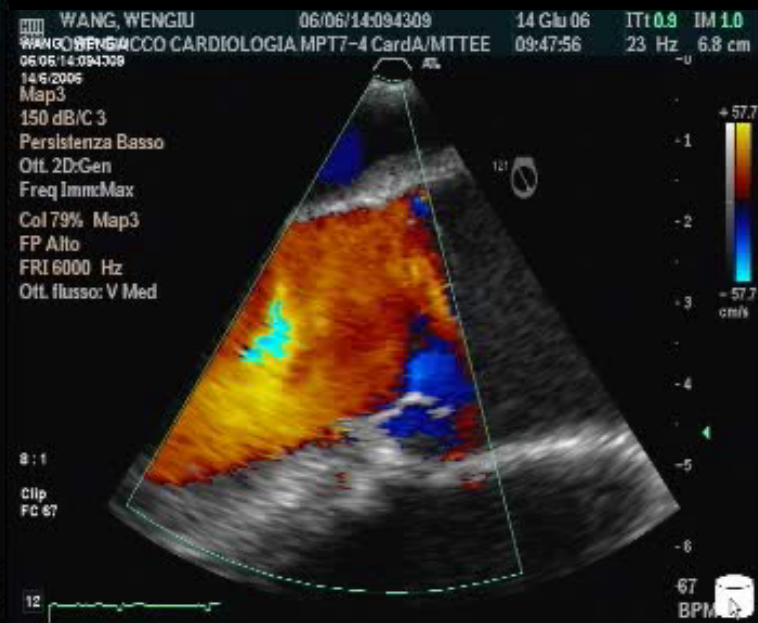
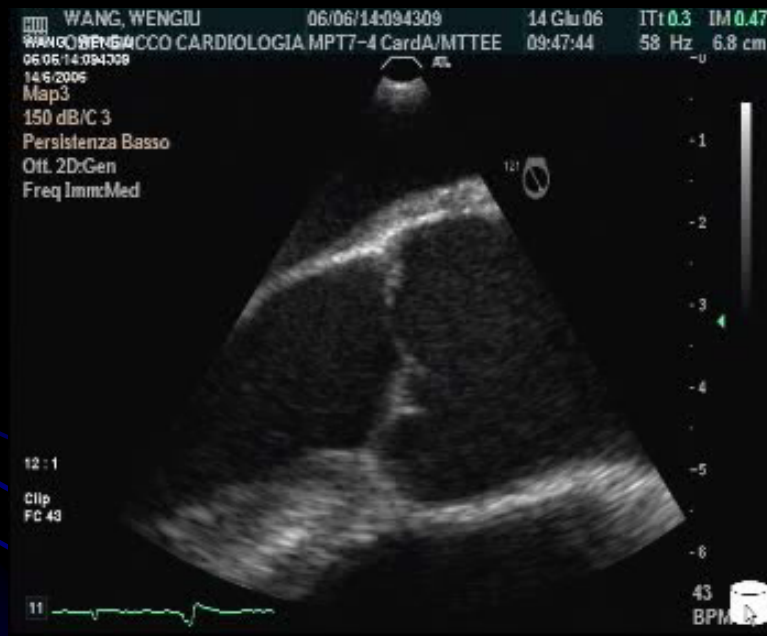RICOSTRUZIONE



B
A
S



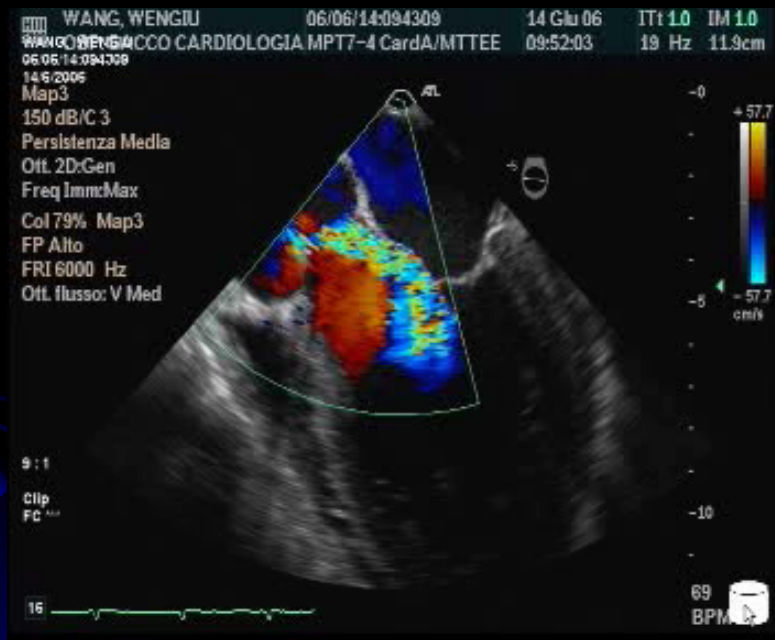
PROLASSO LEMBO V AORTA



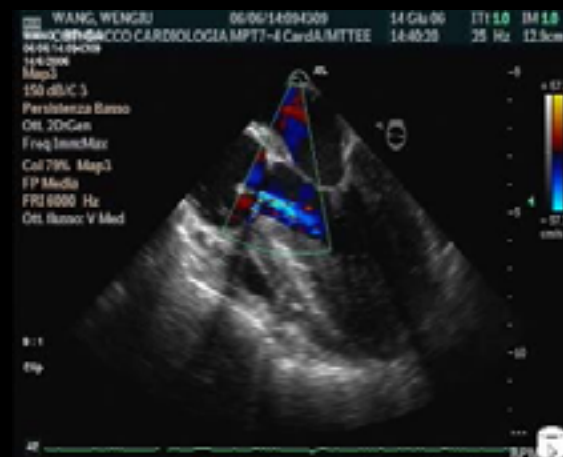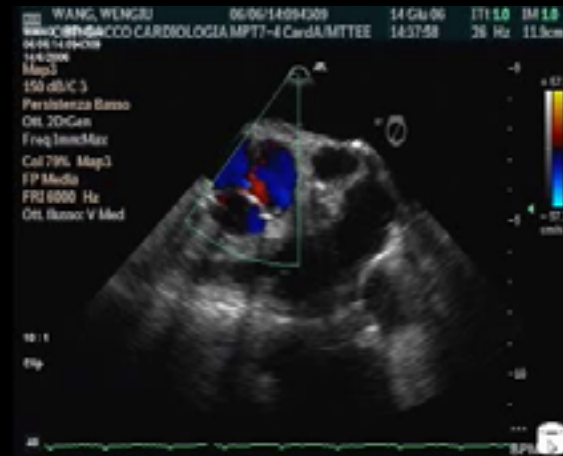ZOOM TRATTO EFFLUSSO
E VALVOLA



RIPARAZIONE PROLASSO AORTICA



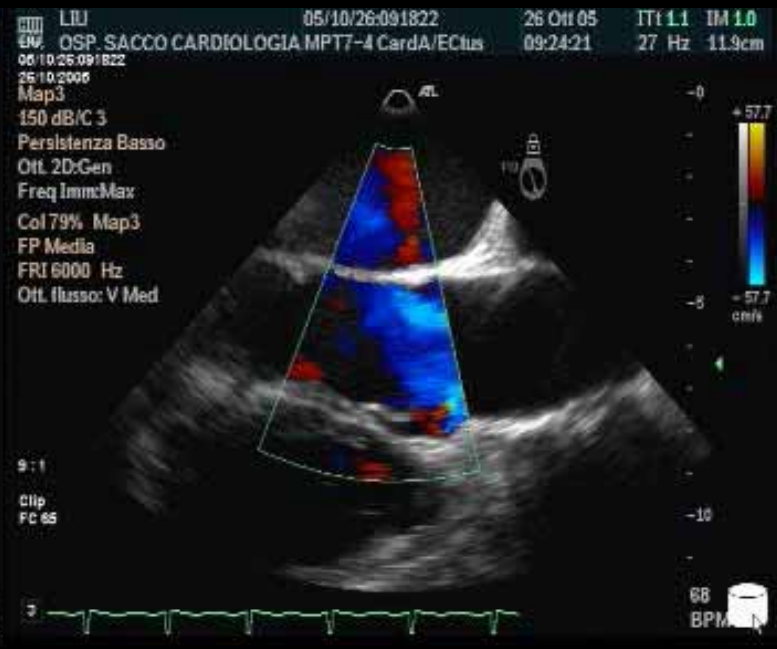
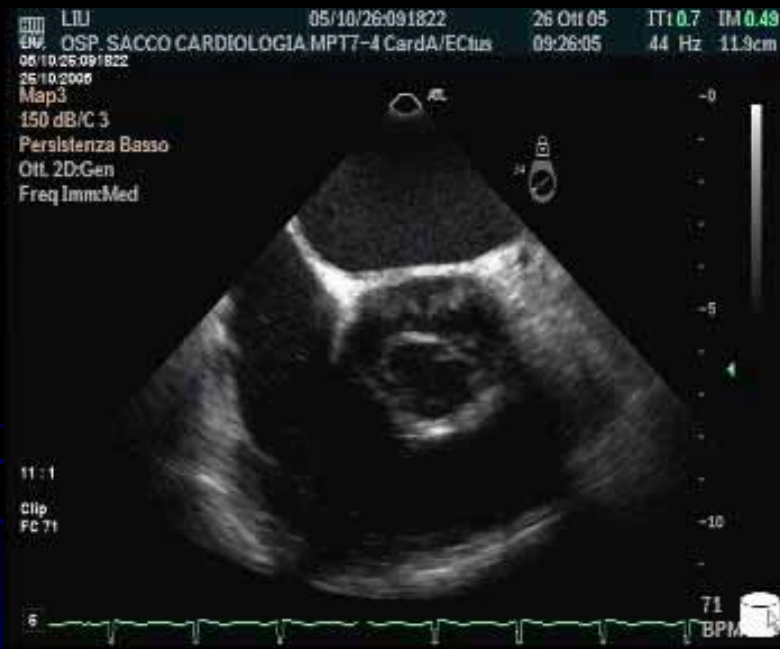BASALE



RIPARAZIONE



PROLASSO LEMBO V AORTA



CASO CLINICO: V BICUSPIDE + IAO

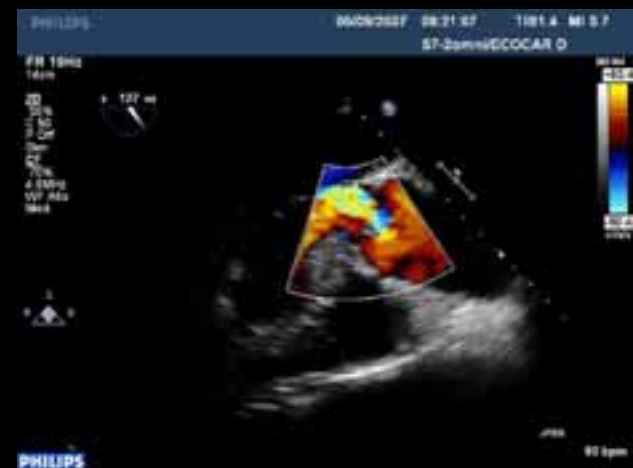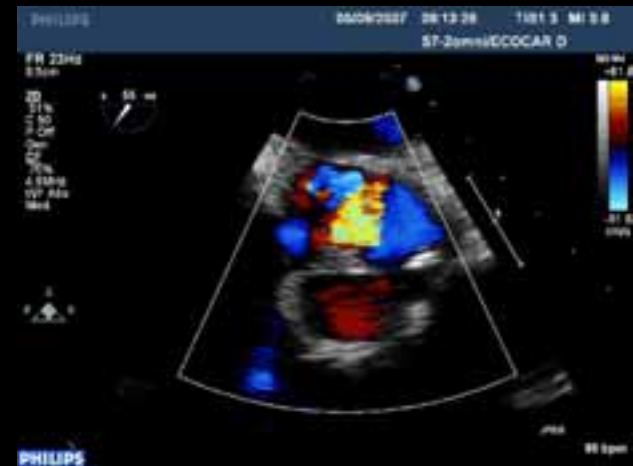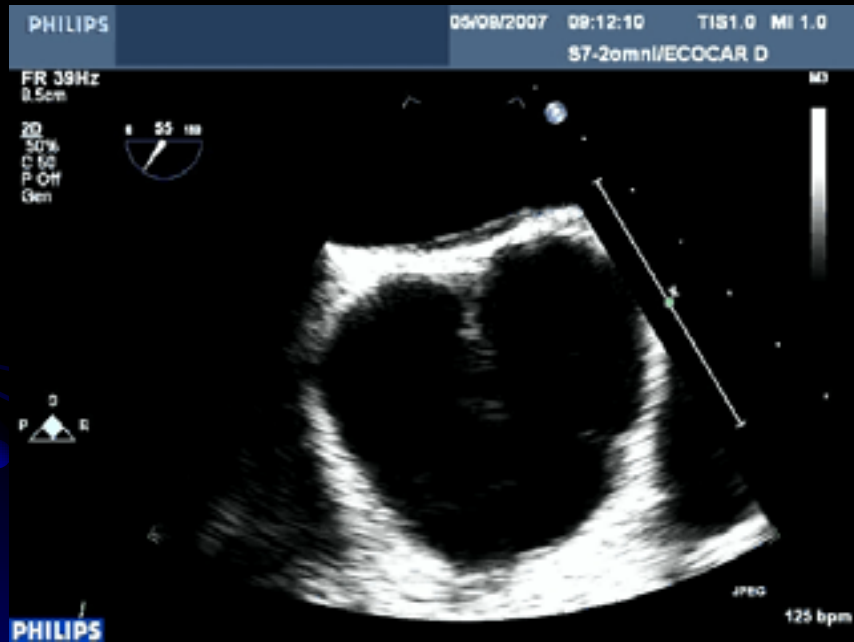
Paziente 52 anni, classe NYHA II

Valvola aorta bicuspidica con jet centrale
basale riparazione

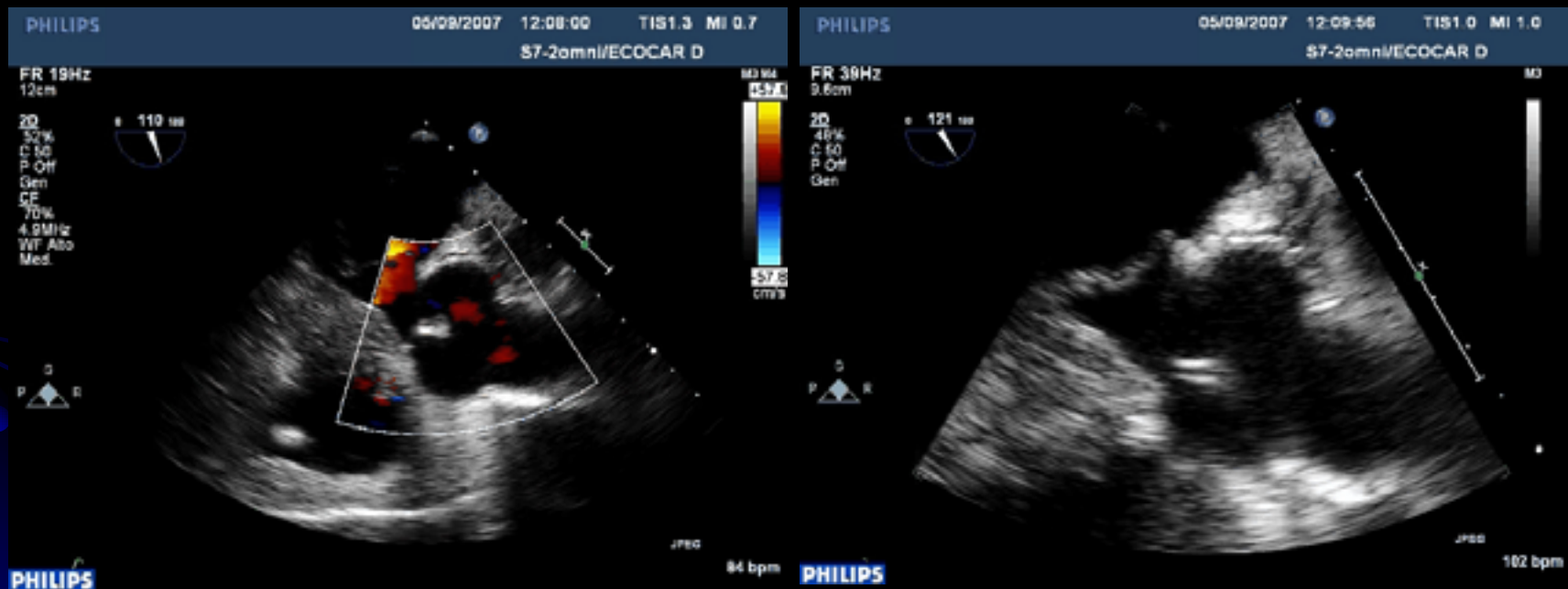
Anulus	26 mm	23 mm
Seni Valsalva	44 mm	35 mm
Coptazione	4 mm	9 mm
Giunzione	50 mm	prot tubulare
Reflusso aortico	3+/4+	0



V AO BICUSPIDE + IAO



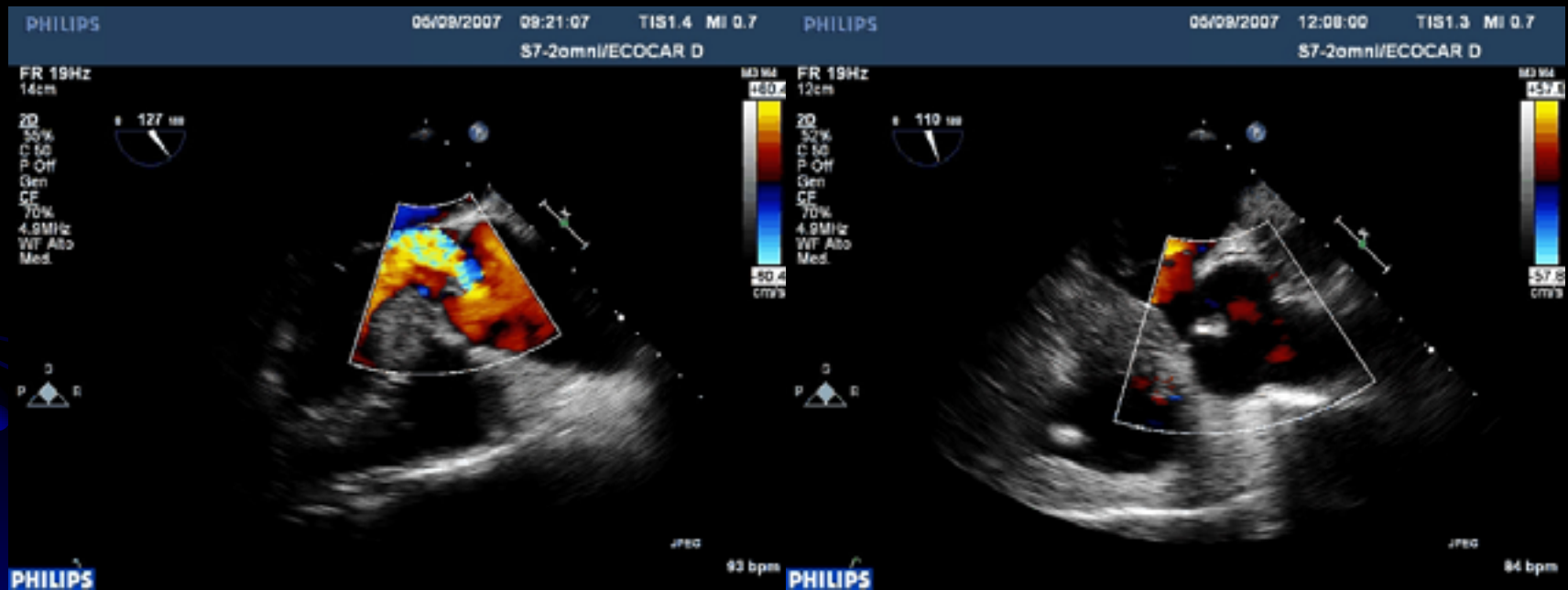RIPARAZIONE



CONFRONTO REFLUSSO AORTICO

BASALE

RIPARAZIONE



CASO CLINICO: IAO + IM

Paziente 71 anni, classe NYHA II

Valvola aorta tricuspidale con jet centrale

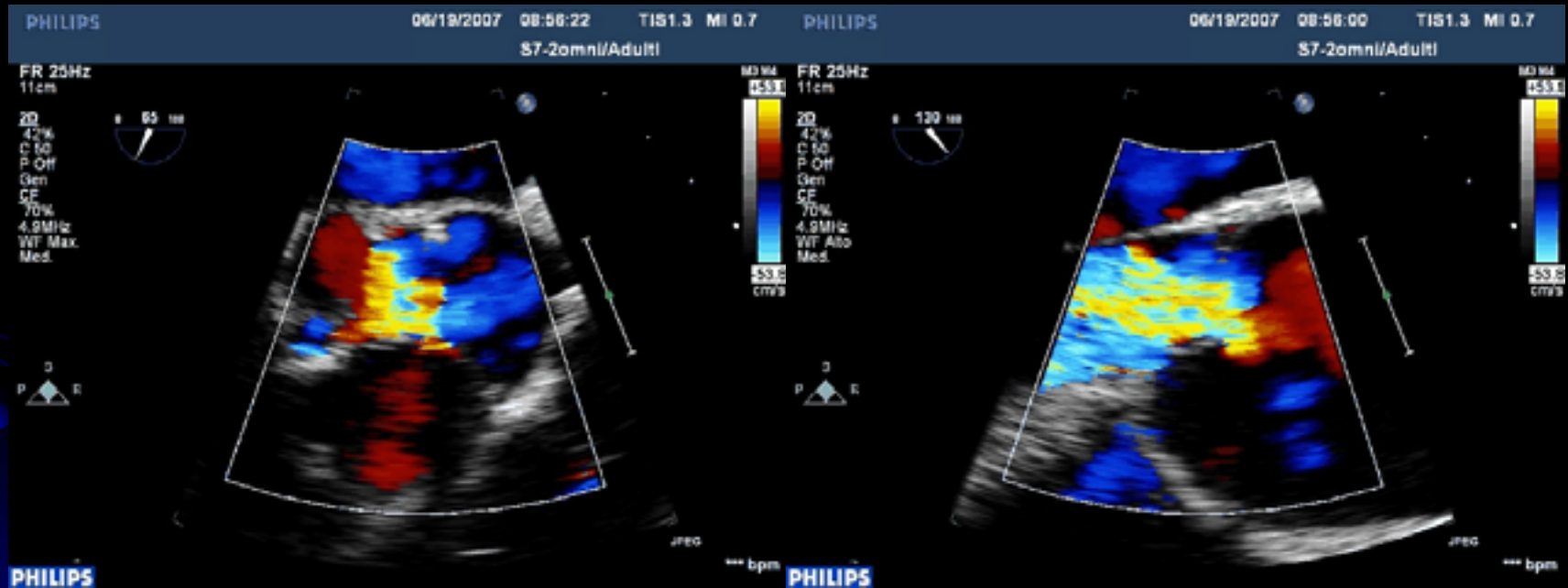
DDVS 72 mm, VTD 210 ml, FE 35%

	basale	riparazione
Anulus	28 mm	23 mm
Seni Valsalva	50 mm	36 mm
Coptazione	5 mm	9 mm
Giunzione	50 mm	prot tubulare
Reflusso aortico	3+/4+	1



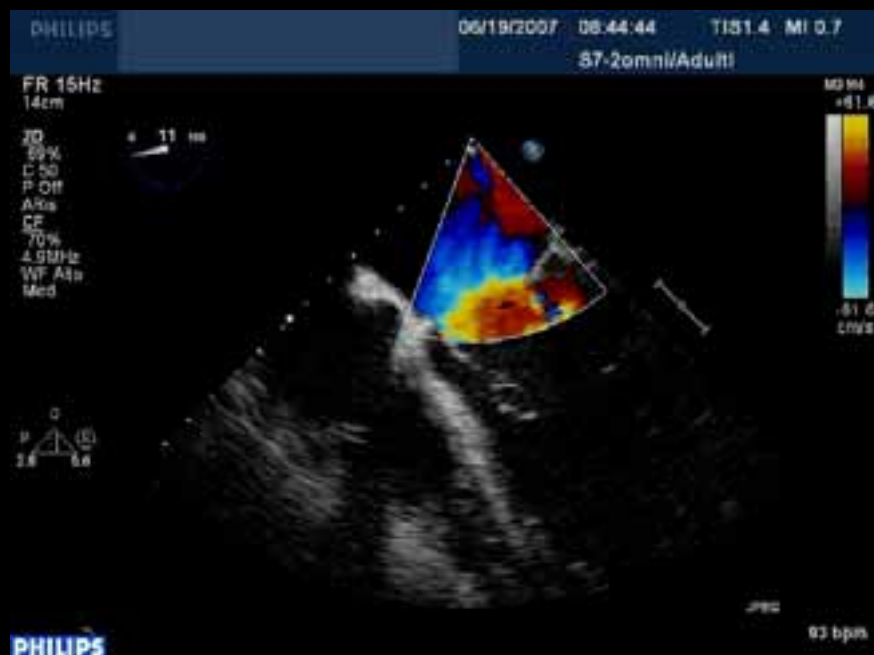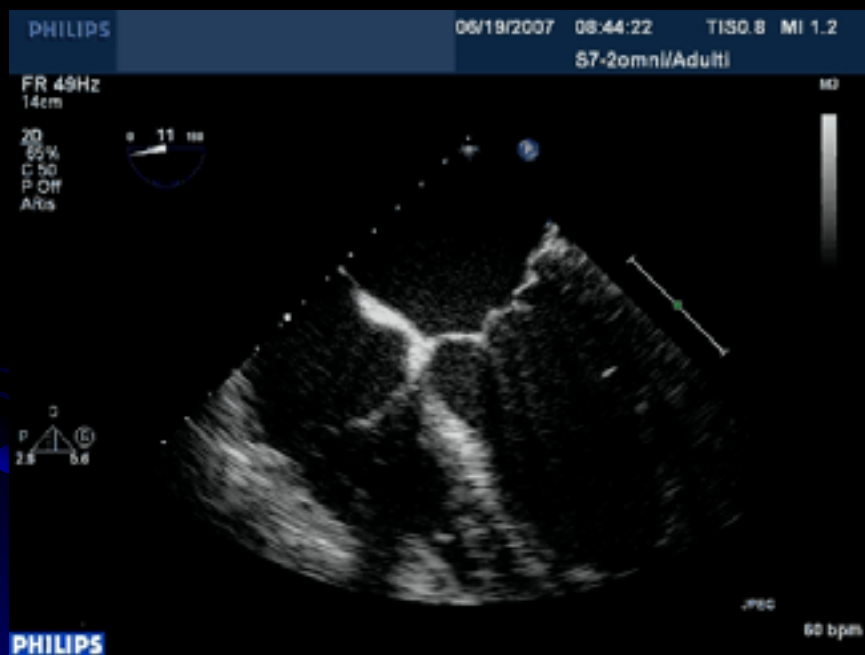
VALVOLA AORTA TRICUSPIDE + REFLUSSO MITRALICO

REFLUSSO AORTICO

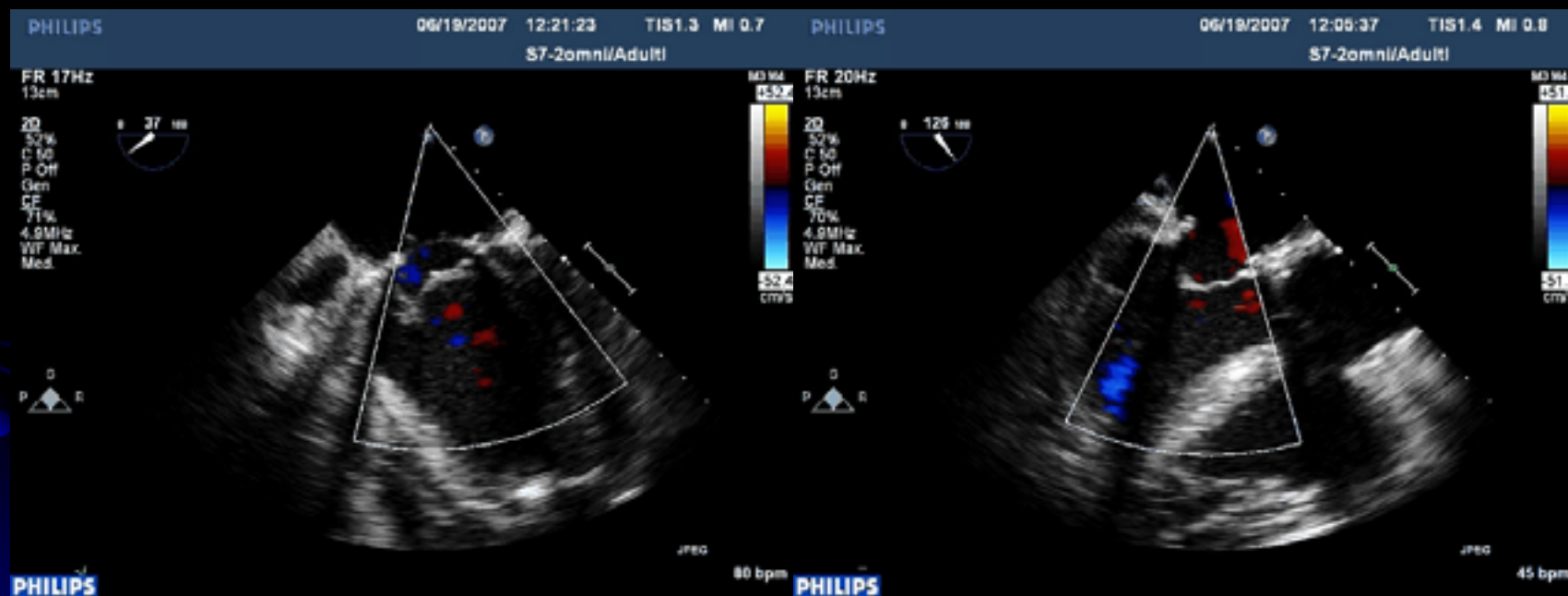


VALVOLA AORTA TRICUSPIDE + REFLUSSO MITRALICO

REFLUSSO MITRALICO



RIPARAZIONE AORTICA E MITRALICA



CASO CLINICO: IAO SECONDARIA A DISSECAZIONE

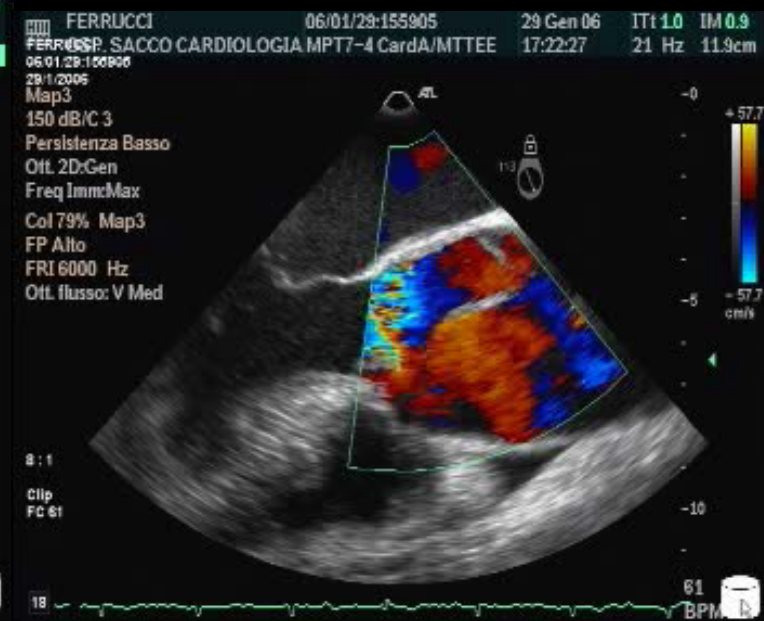
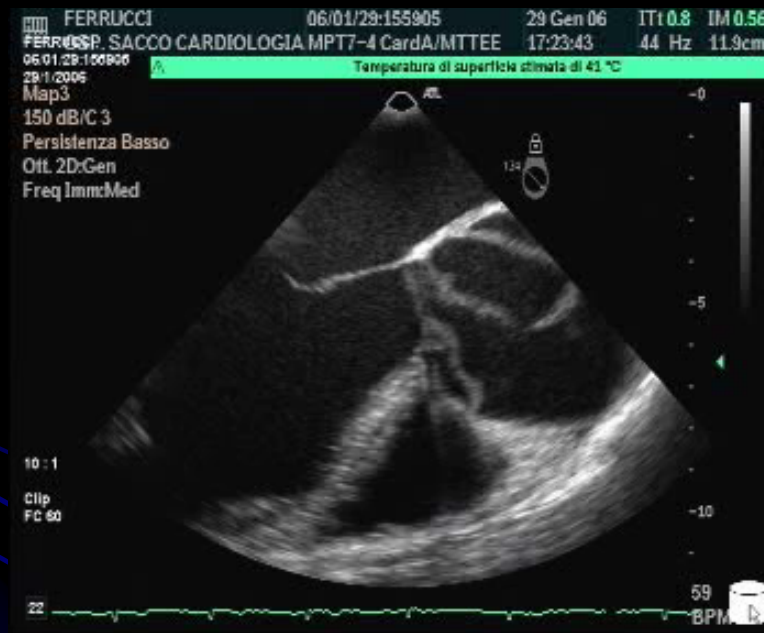Paz. 42 anni, Valvola aorta tricuspide con
reflusso secondario alla dissezione

DDVS 60 mm, VTD 145 ml, FE 65%

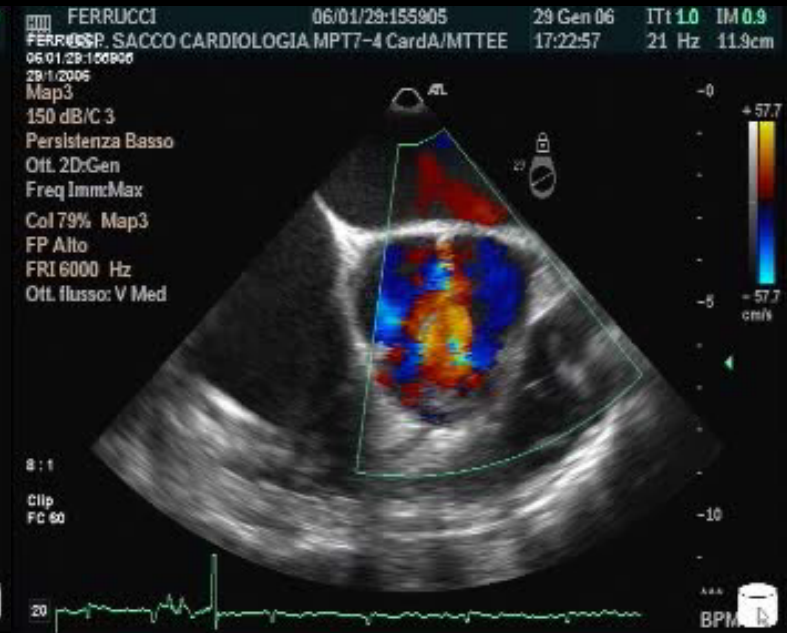
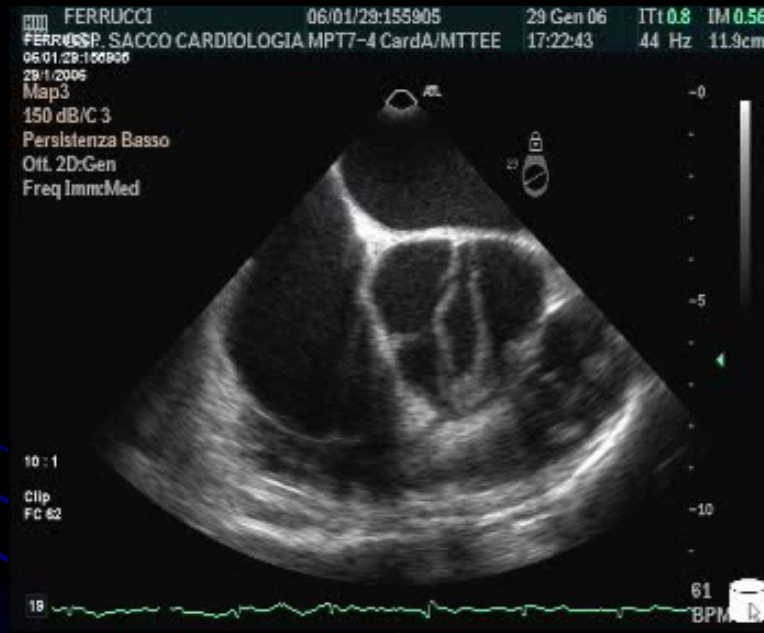
	basale	riparazione
Anulus	28 mm	23 mm
Seni Valsalva	58 mm	36 mm
Coptazione	0 mm	9 mm
Giunzione	60 mm	prot tubulare
Reflusso aortico	4+/4+	1



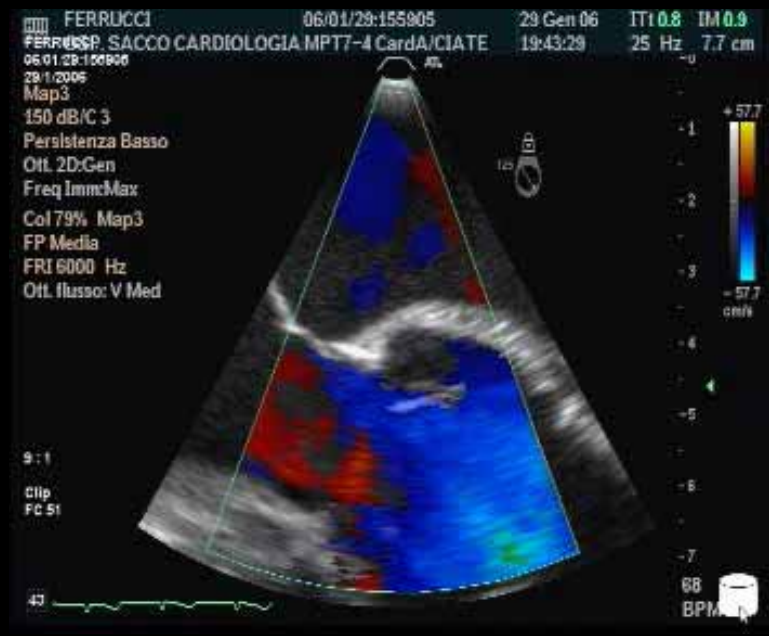
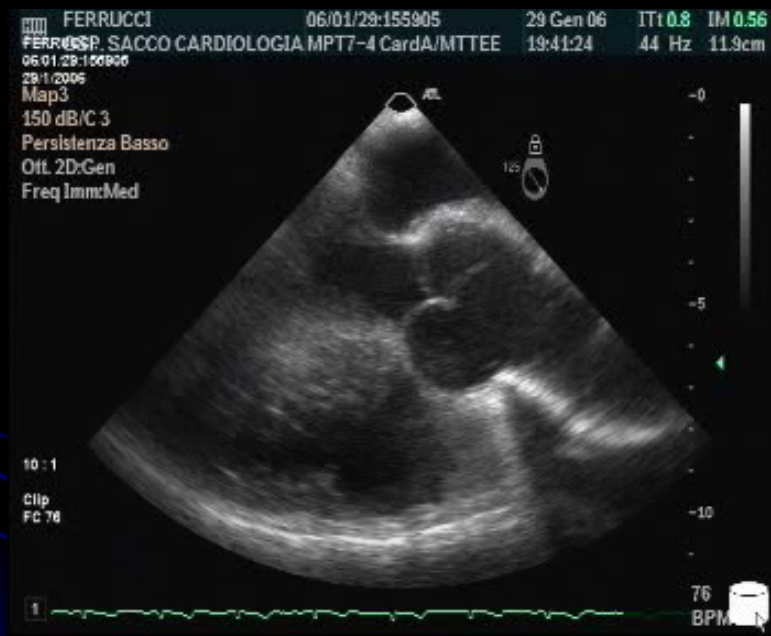
REFLUSSO AORTICO SECONDARIO A DISSEZIONE



REFLUSSO AORTICO SECONDARIO A DISSEZIONE



RISULTATO OPERATORIO



CASO CLINICO: INSUFFICIENZA AORTICA

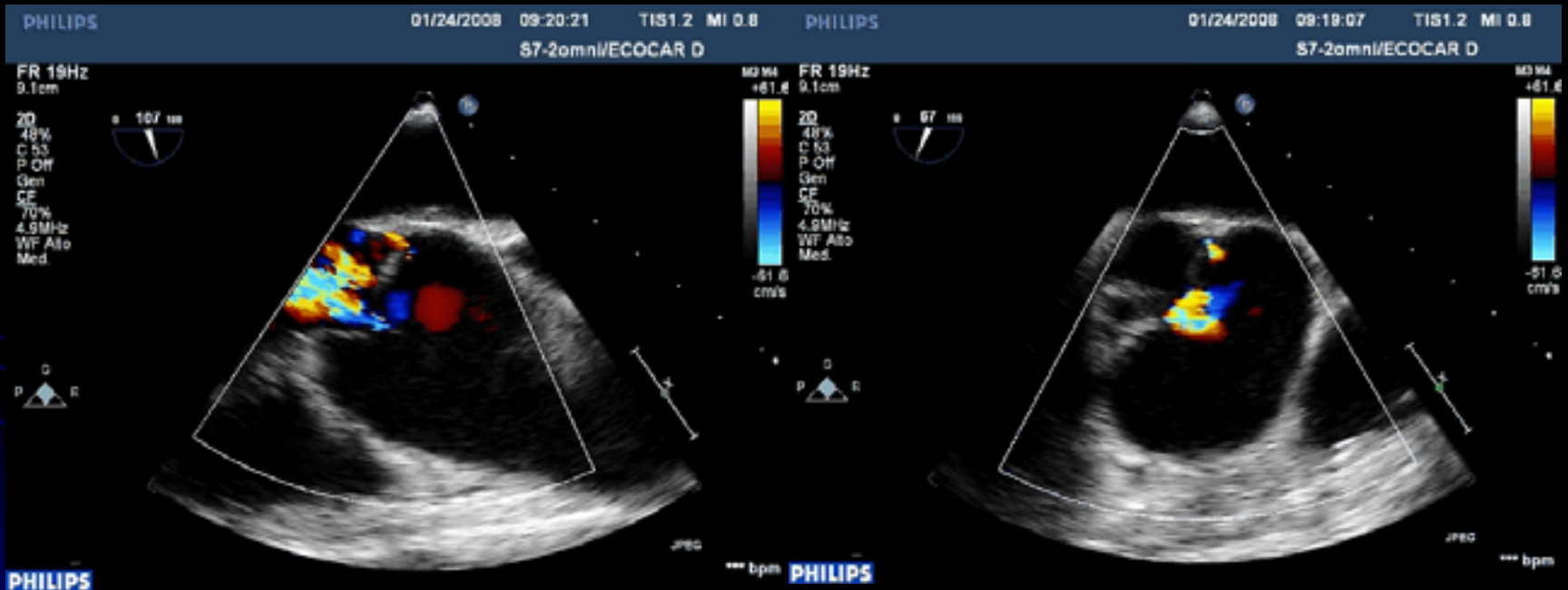
Paziente 73 anni, classe NYHA II (DDVS 71 mm.
VTD 205 ml, FE 45%)

Valvola aorta tricuspidale con jet centrale e
Commisura tra lembo sx e non coronarico

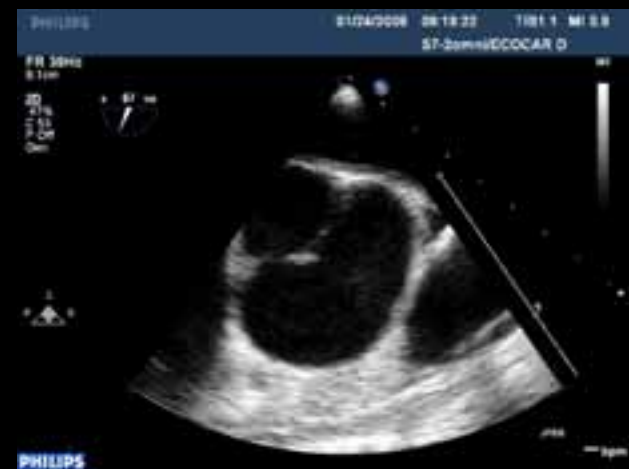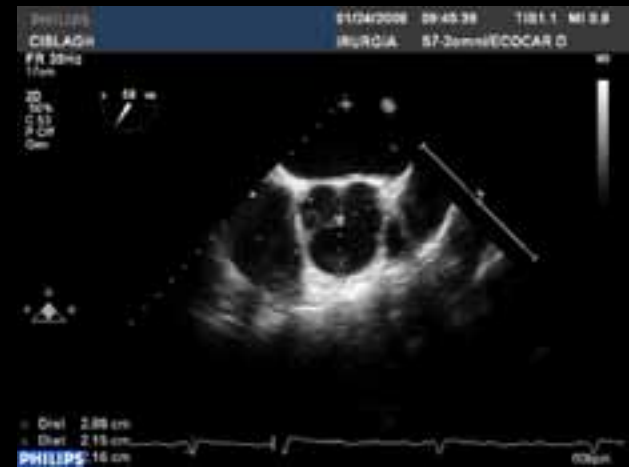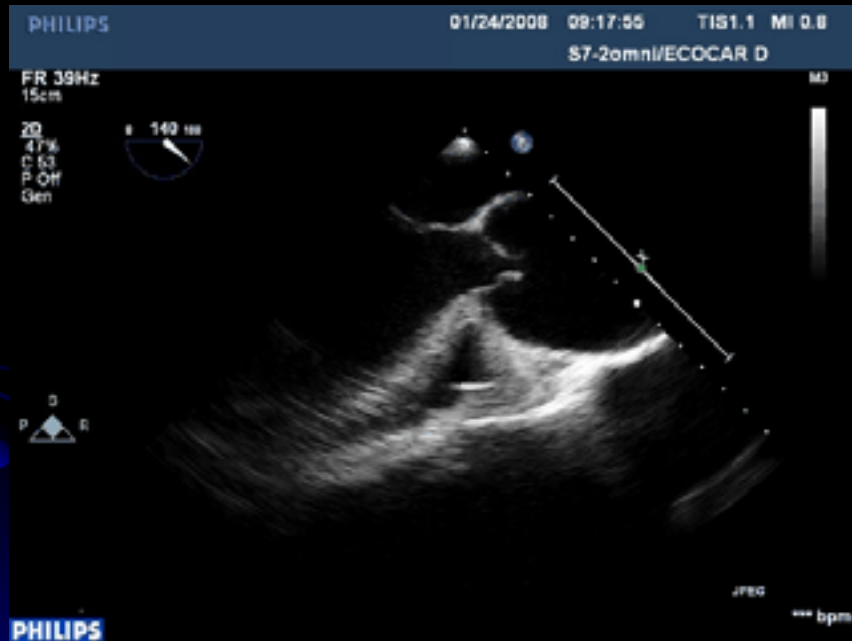
	basale	riparazione
Anulus	26 mm	23 mm
Seni Valsalva	48 mm	35 mm
Coptazione	5 mm	8-9 mm
Giunzione	50 mm	prot tubulare
Reflusso aortico	3+	1+



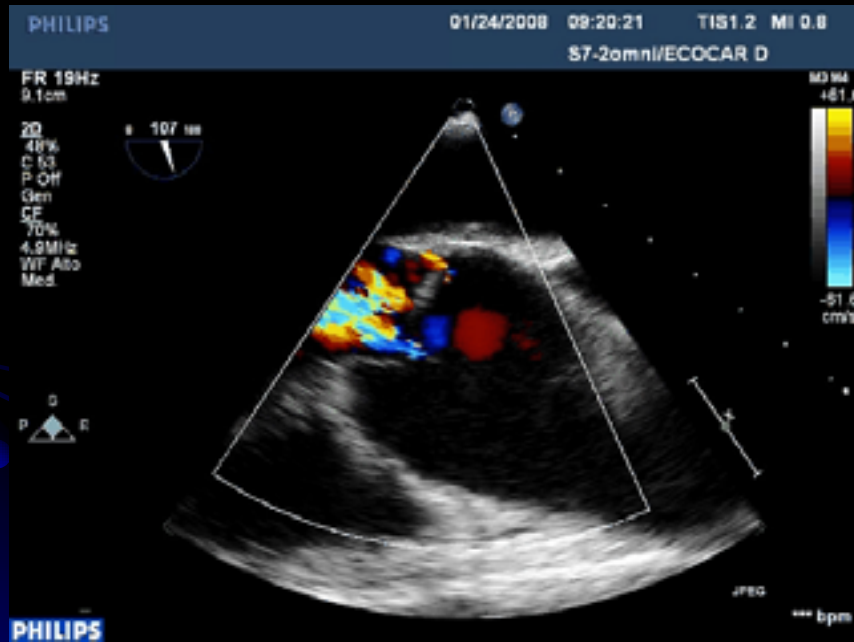
REFLUSSO VALVOLARE AORTICO 2 JET



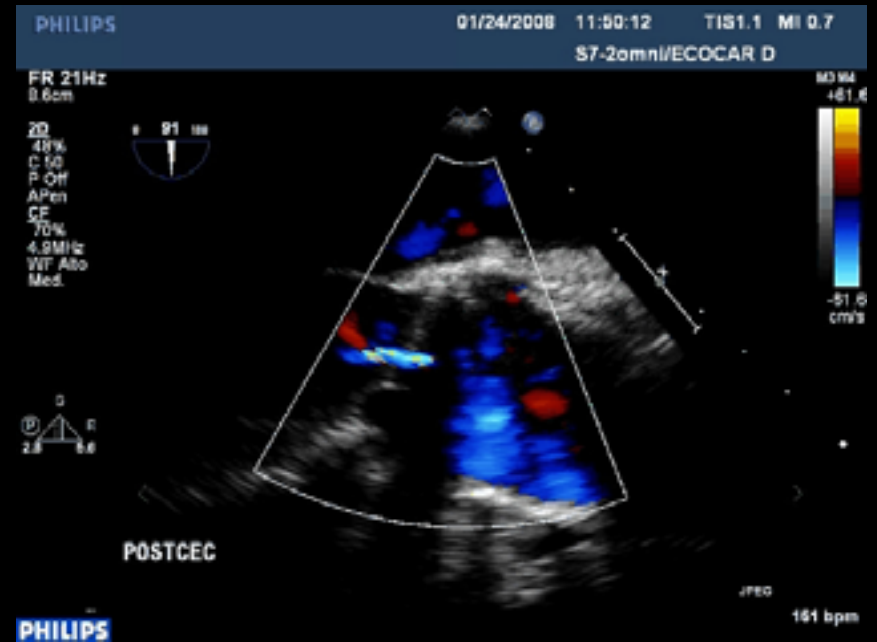
DILATAZIONE SENO CORONARICO DX + IAO



CONFRONTO REFLUSSO AORTICO



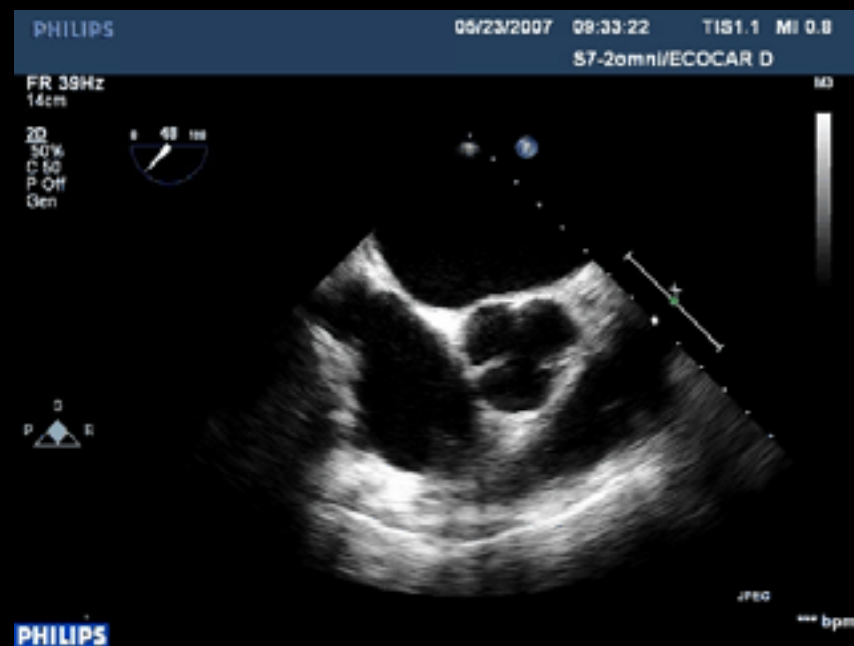
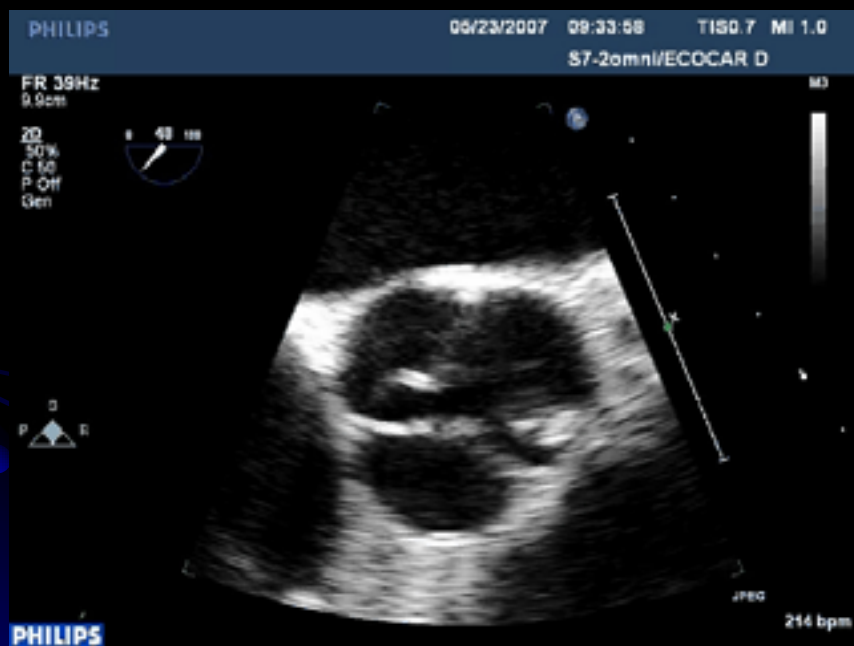
BASALE



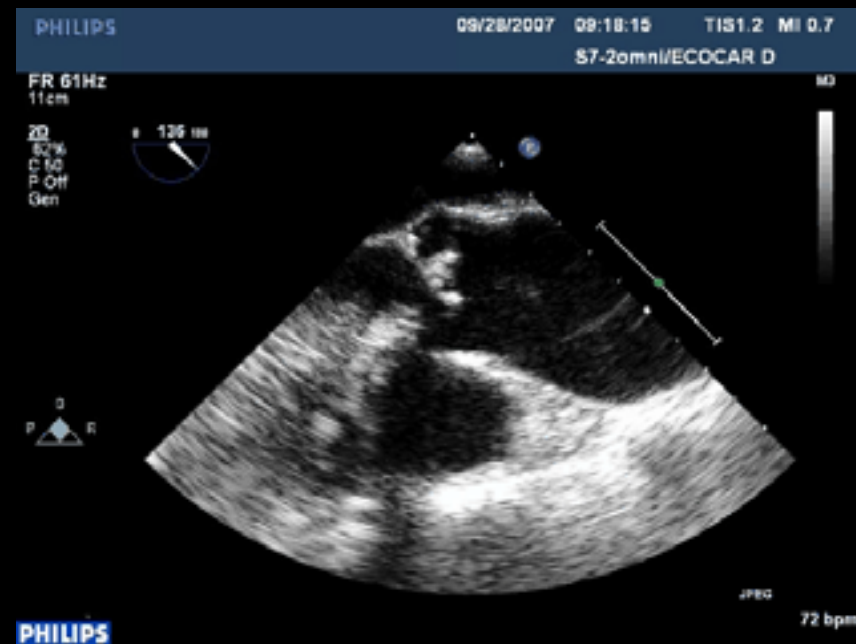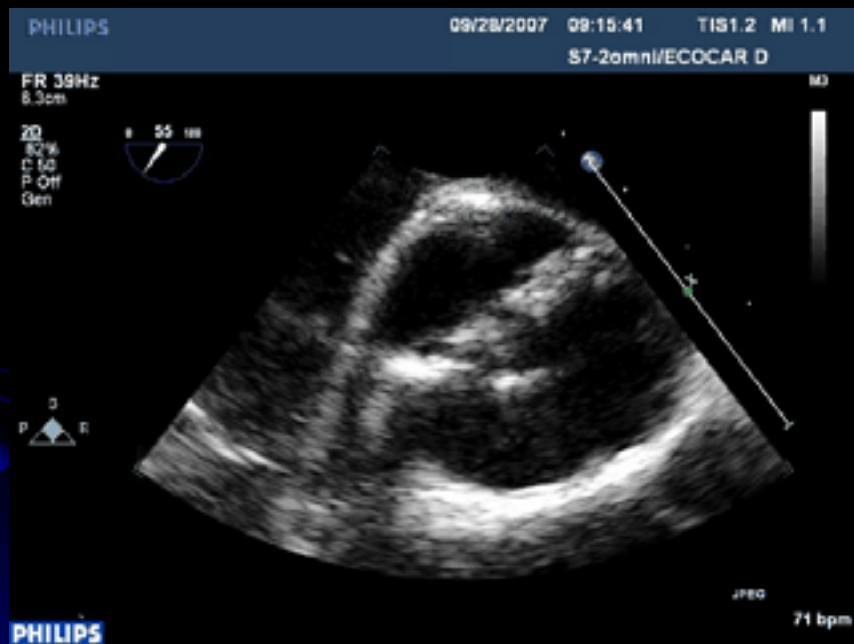
RIPARAZIONE



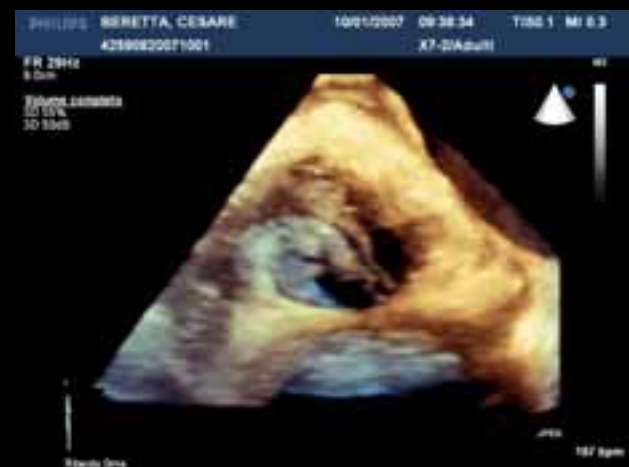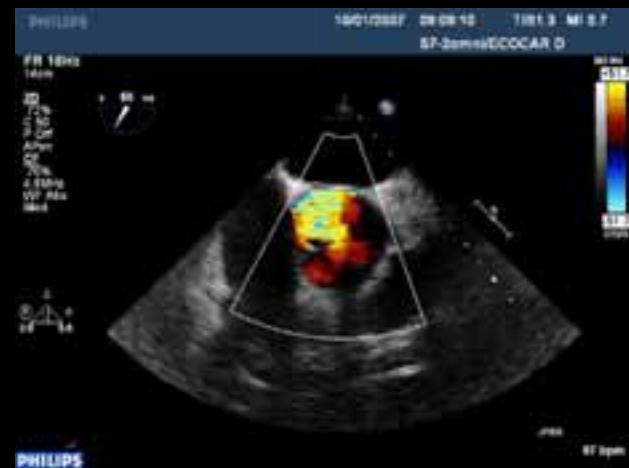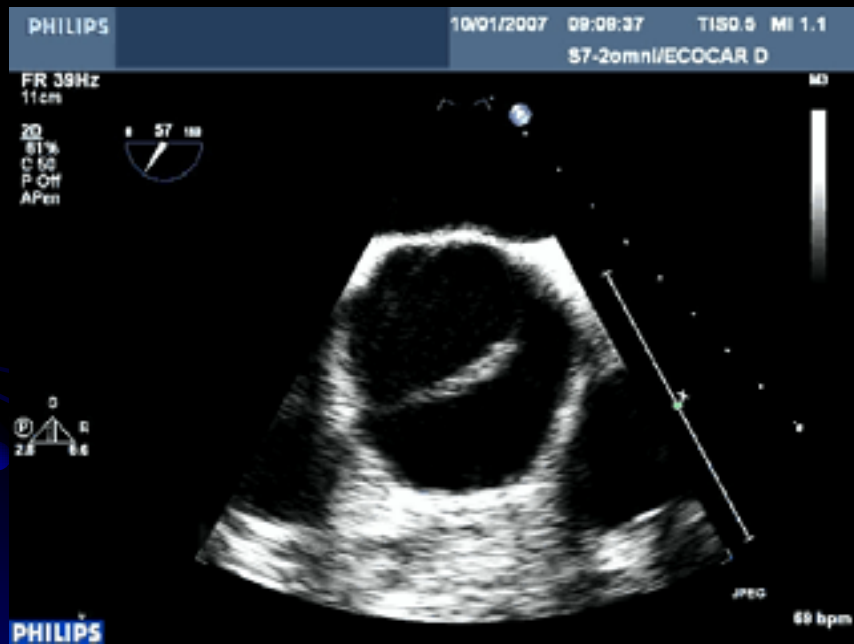
CALCIFICAZIONE V TRICUSPIDE NON RIPARABILE



BICUSPIDE NON RIPARABILE



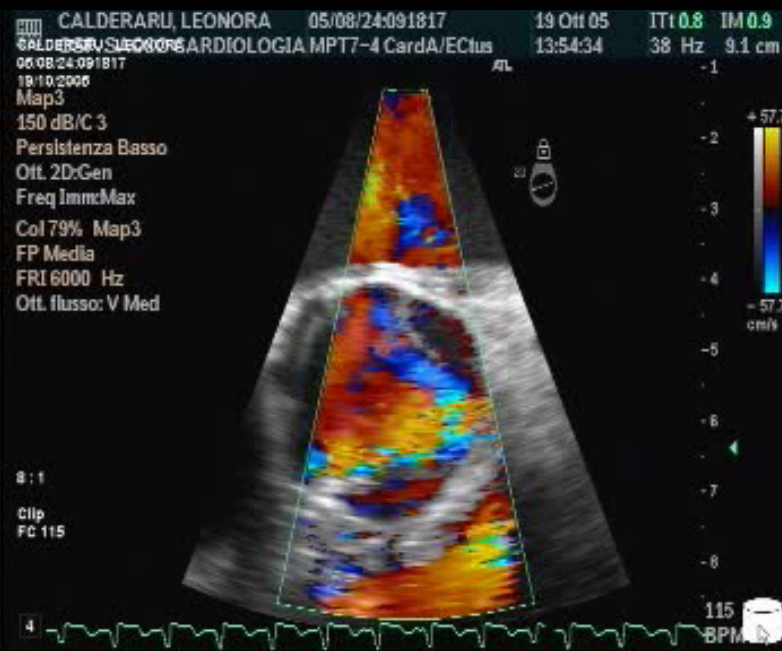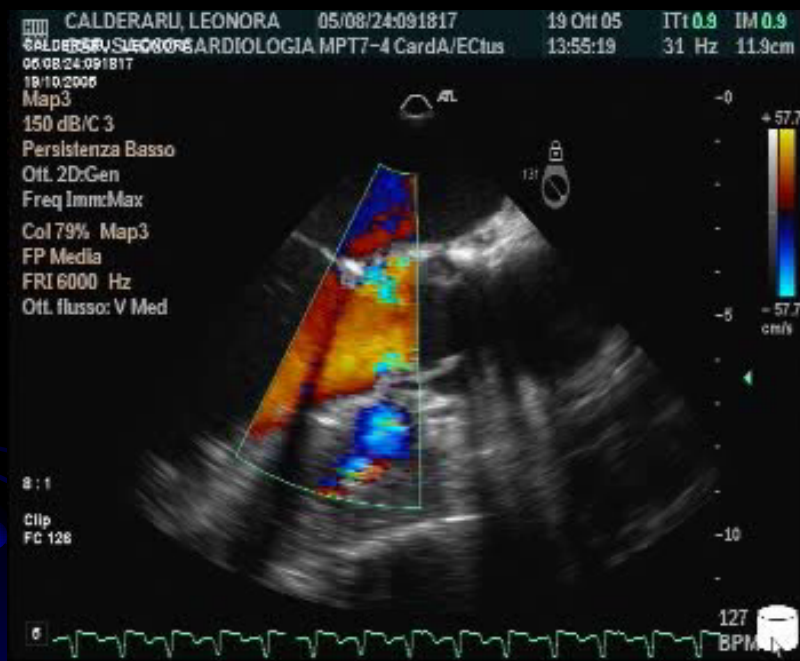POSSIBILE RUOLO 3D



3 D
EPIC



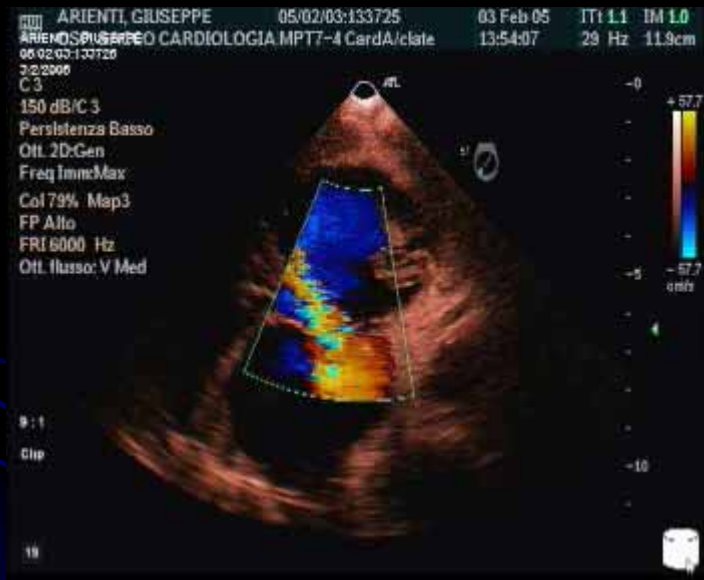RISULTATO NON OTTIMALE



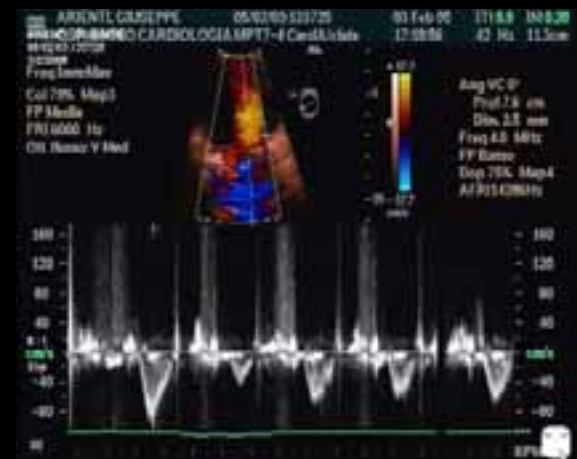
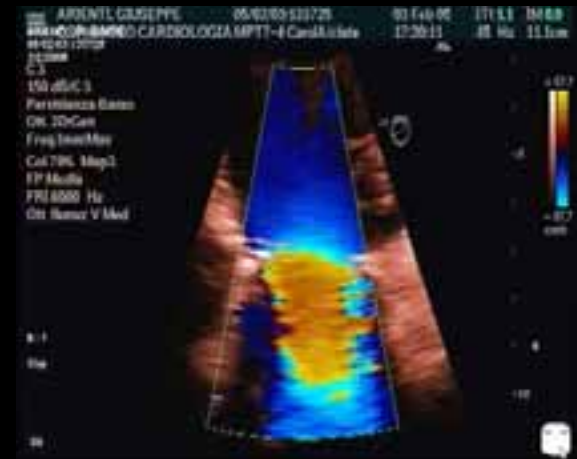
ECO TEE INTRAOP E' METODICA
FONDAMENTALE PER CHIR RIP
AORTICA: REFLUSSO AORTICO
RESIDUO 2+ NON ACCETTABILE



SEZIONI TRANSGASTRICHE PROFONDE



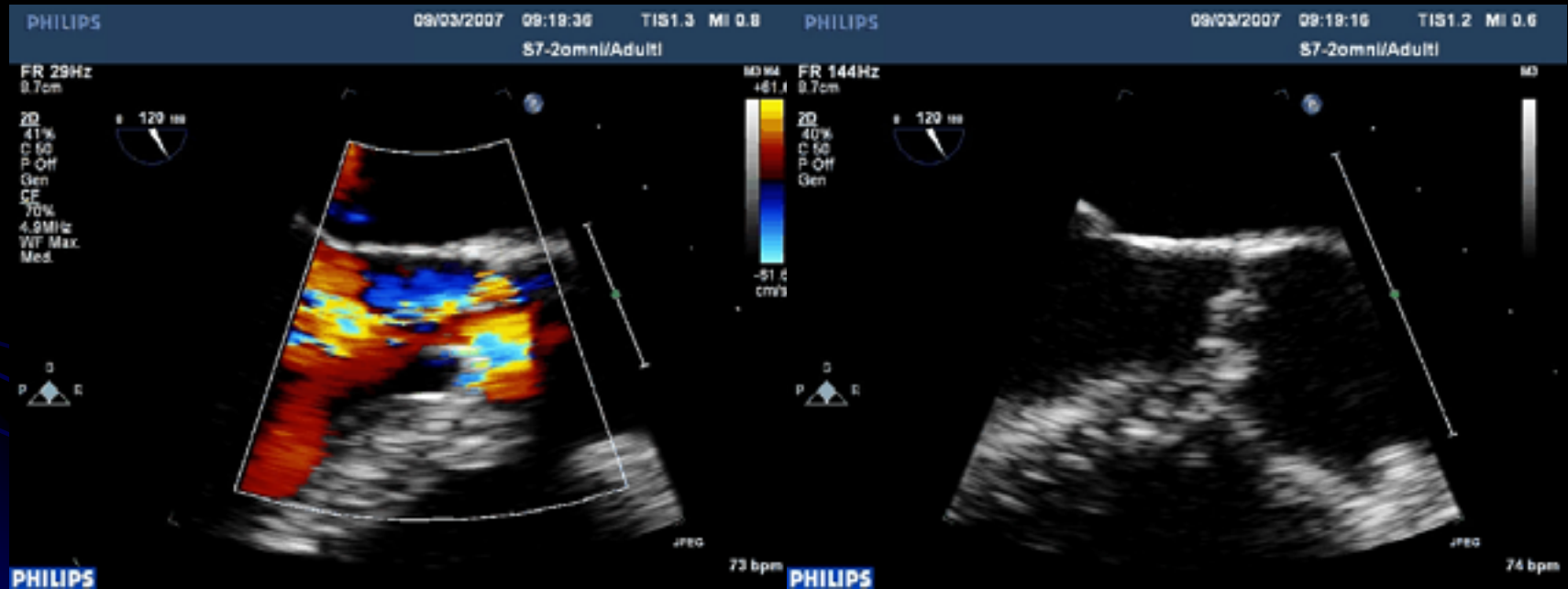
BASALE



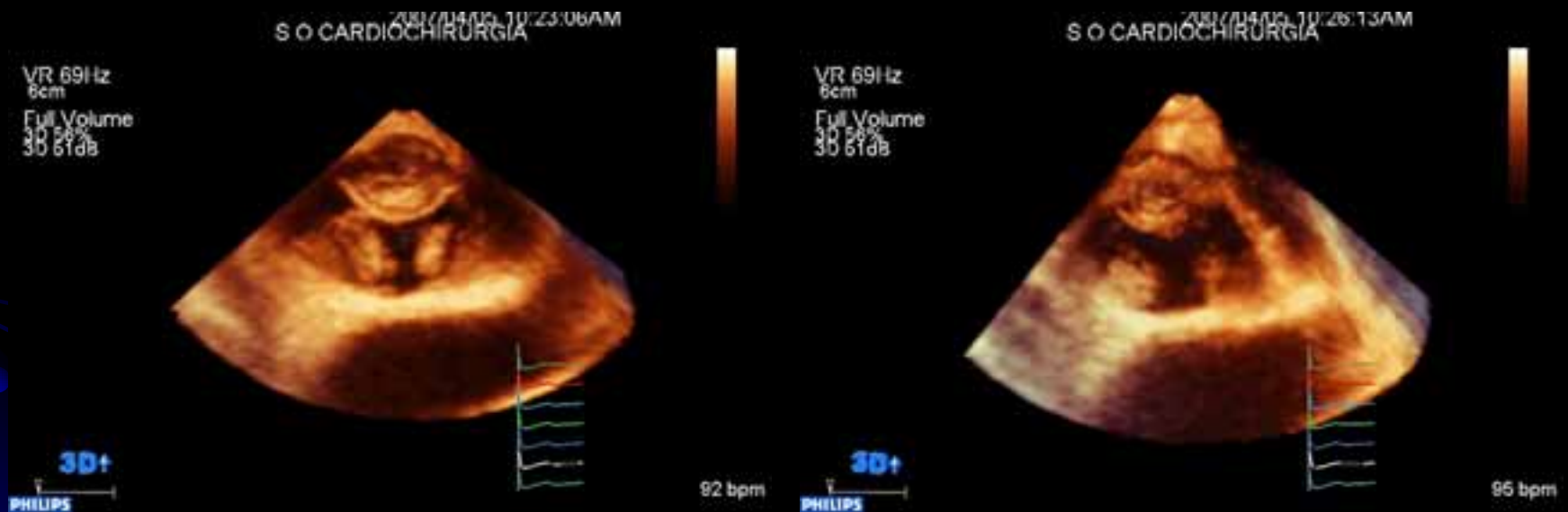
R
I
P



ENDOCARDITE SU PLASTICA AORTICA



POSSIBILE RUOLO 3D



3D EPICARDICO

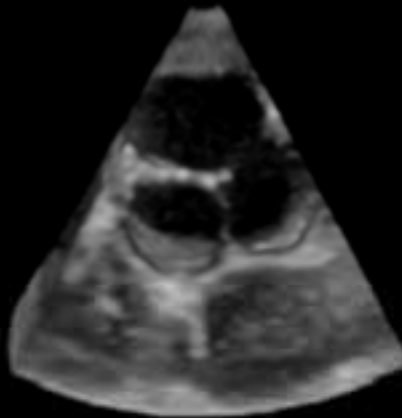
Fondazione
Don Carlo Gnocchi
Onlus

ECOGRAFIA EPICARDICA TRIDIMENSIONALE

2005/04/27 09:31:38AM
Philips Medical S.

VR 24Hz
9cm

Live 3D
3D 50%
3D 50dB

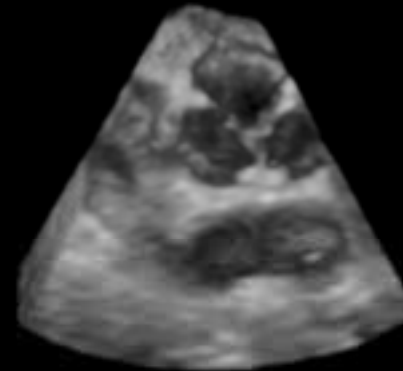


71 bpm

2005/04/27 11:23:29AM
Philips Medical S.

VR 24Hz
10cm

Live 3D
3D 50%
3D 50dB



56 bpm

View: Crossing Color MPR Setup

VR Mode	Gain 20%	3D Compression 70%	Water	Color	VR S
Auto Crop	Reset Crop	Adjustment (dB)	Smoothing (Hz)	+	-
VR	Reset VR	Mapping (1.00)	Interpolate	VR	Reset

1/27 0.80s/0.28s (1.4-11, 0.00s)

View: Crossing Color MPR Setup

VR Mode	Gain 20%	3D Compression 70%	Water	Color	VR S
Auto Crop	Reset Crop	Adjustment (dB)	Smoothing (Hz)	+	-
VR	Reset VR	Mapping (1.00)	Interpolate	VR	Reset

1/27 0.80s/1.17s (1.4-11, 0.00s)

