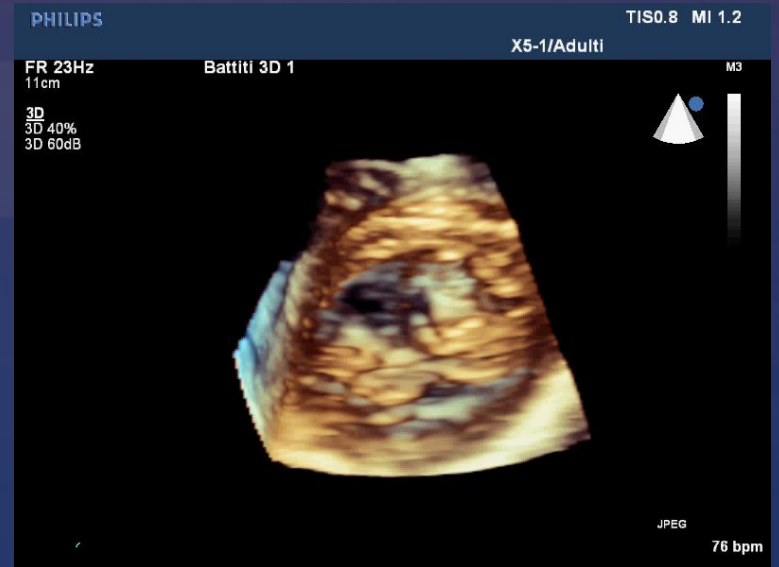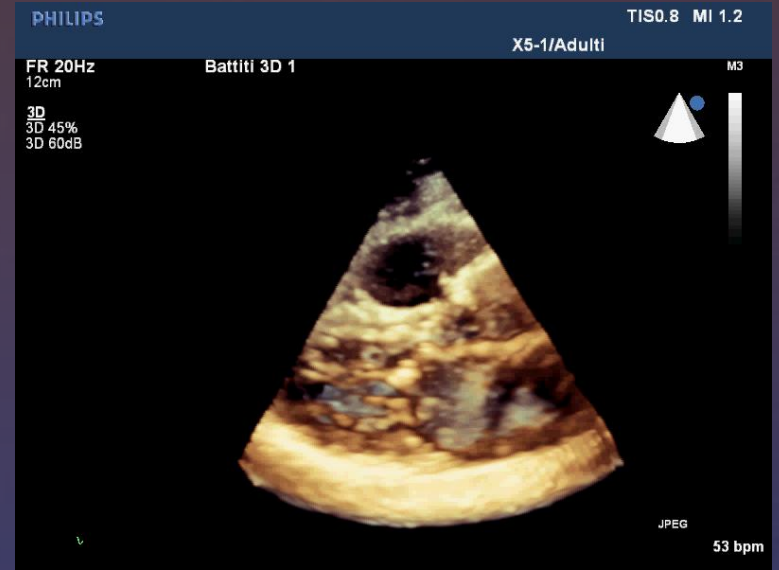
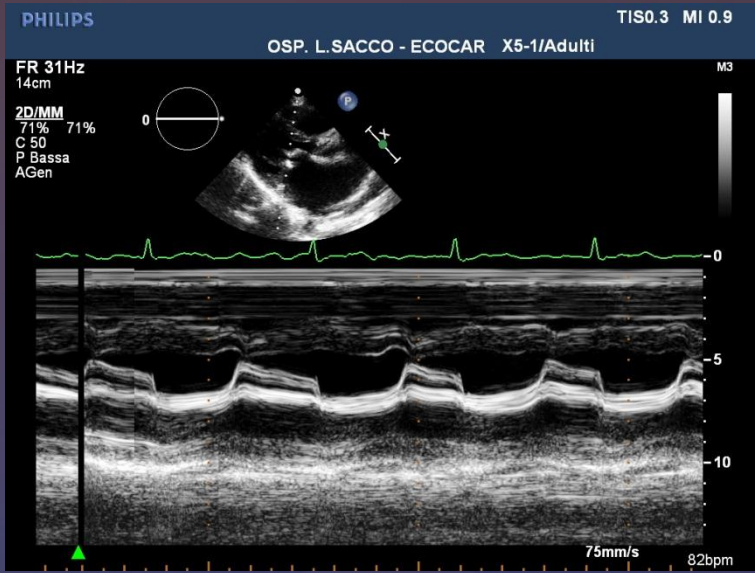


LA STENOSI MITRALICA E LA
DEGENERAZIONE DELL'APPARATO
VALVOLARE. LA FISIOPATOLOGIA, I
METODI DI VALUTAZIONE DELLA
GRAVITA' DELLA PATOLOGIA, LA
FUNZIONE VENTRICOLARE DESTRA, IL
TIMING OPERATORIO E LE OPZIONI
CHIRURGICHE

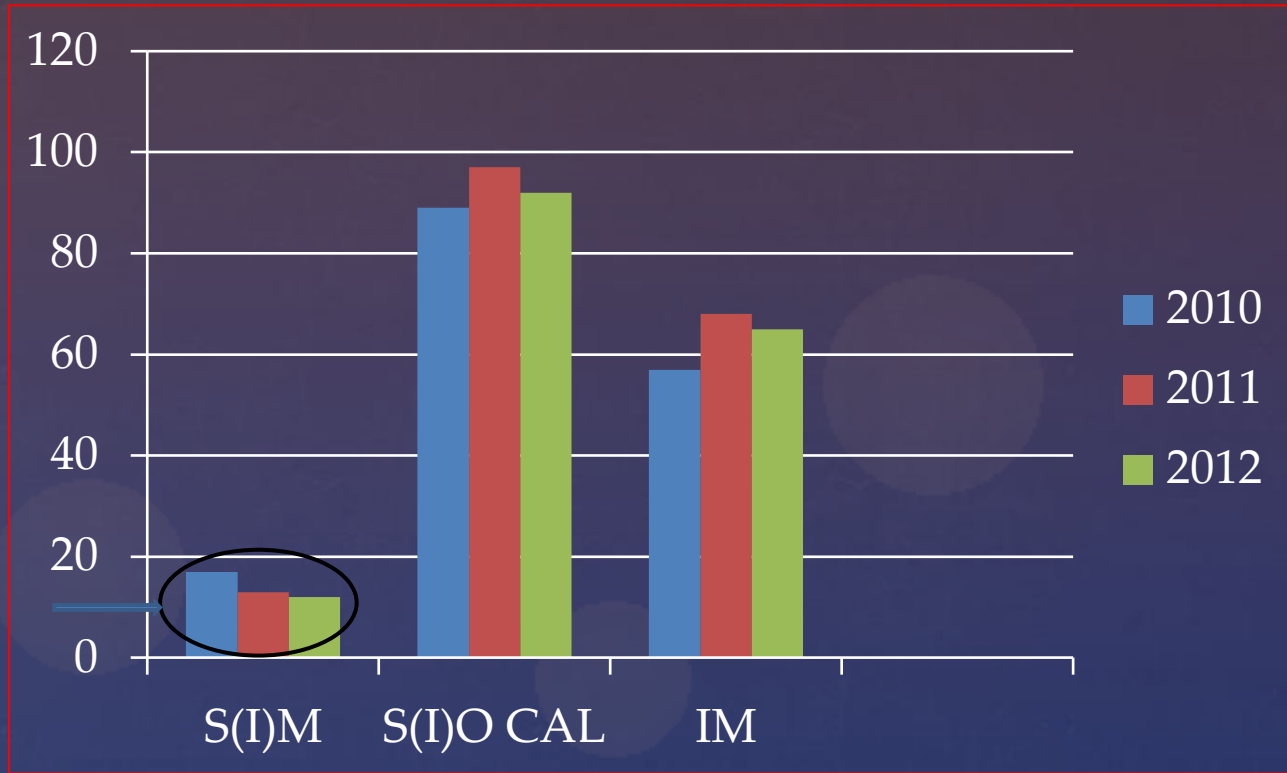
ALESSANDRO CIALFI
AZIENDA OSP. SACCO. MILANO
16 ottobre 2012





SM 1978





INCIDENZA SM



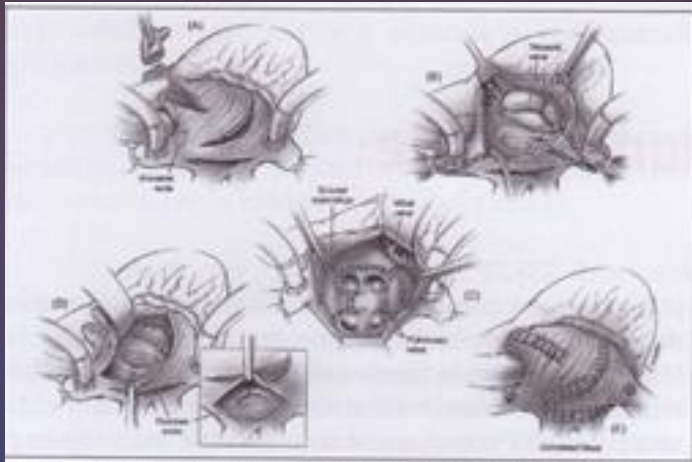
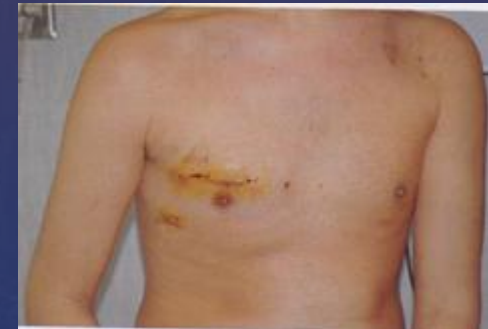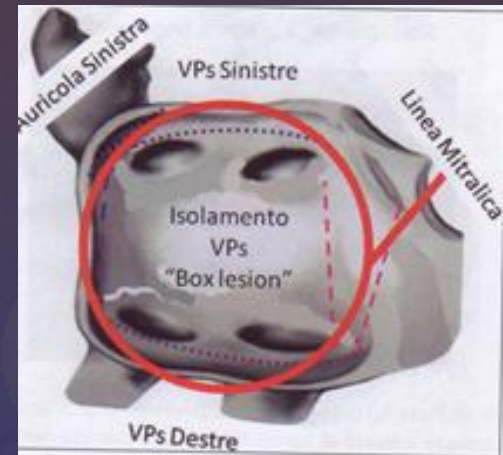


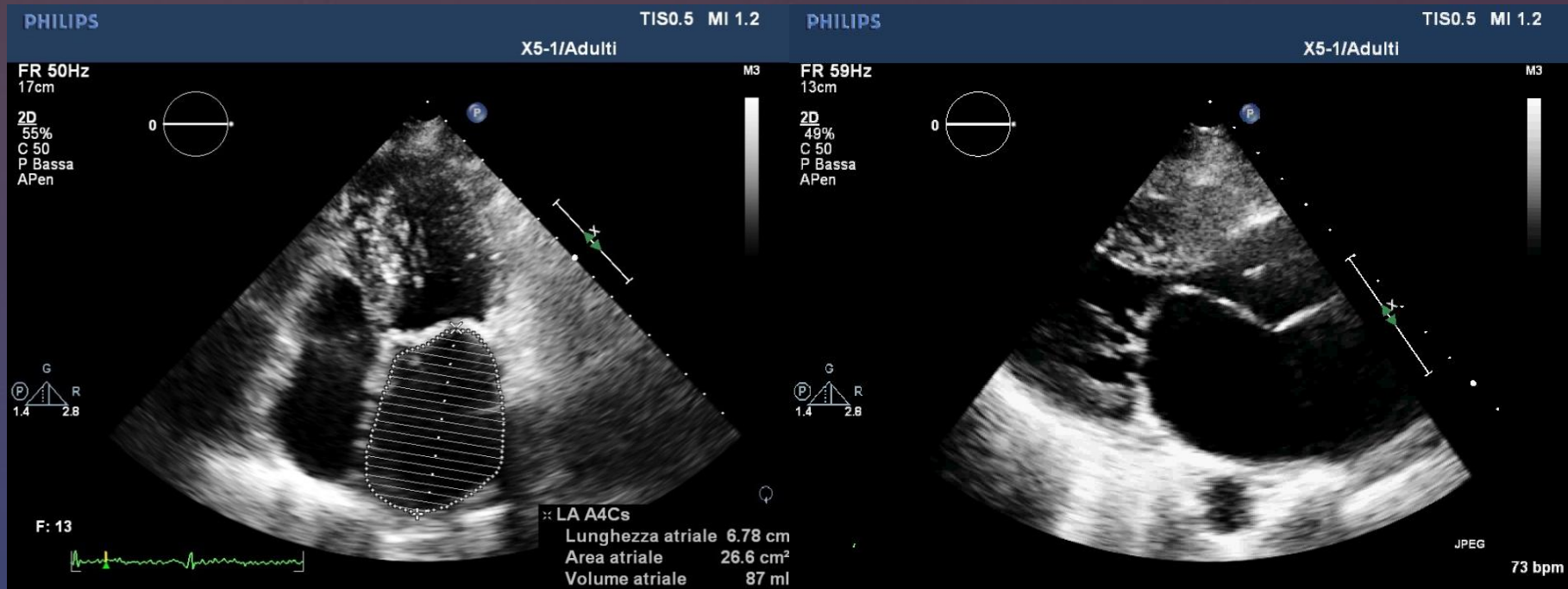
Fig. 1 - Cox Maze Procedure (CMP): nella figura vengono illustrate le lesioni "taglia e cucì" necessarie all'ablazione della fibrillazione e del flutter eseguite in entrambi gli atri.



SOSTITUZIONE VALV.
 PLASTICA MITR
 VALVULOPLAS. PERCUT.

ABLAZIONE CHIRURGICA DELLA FA
 IN CORSO DI CARD ISCH / PATOL MITRAL



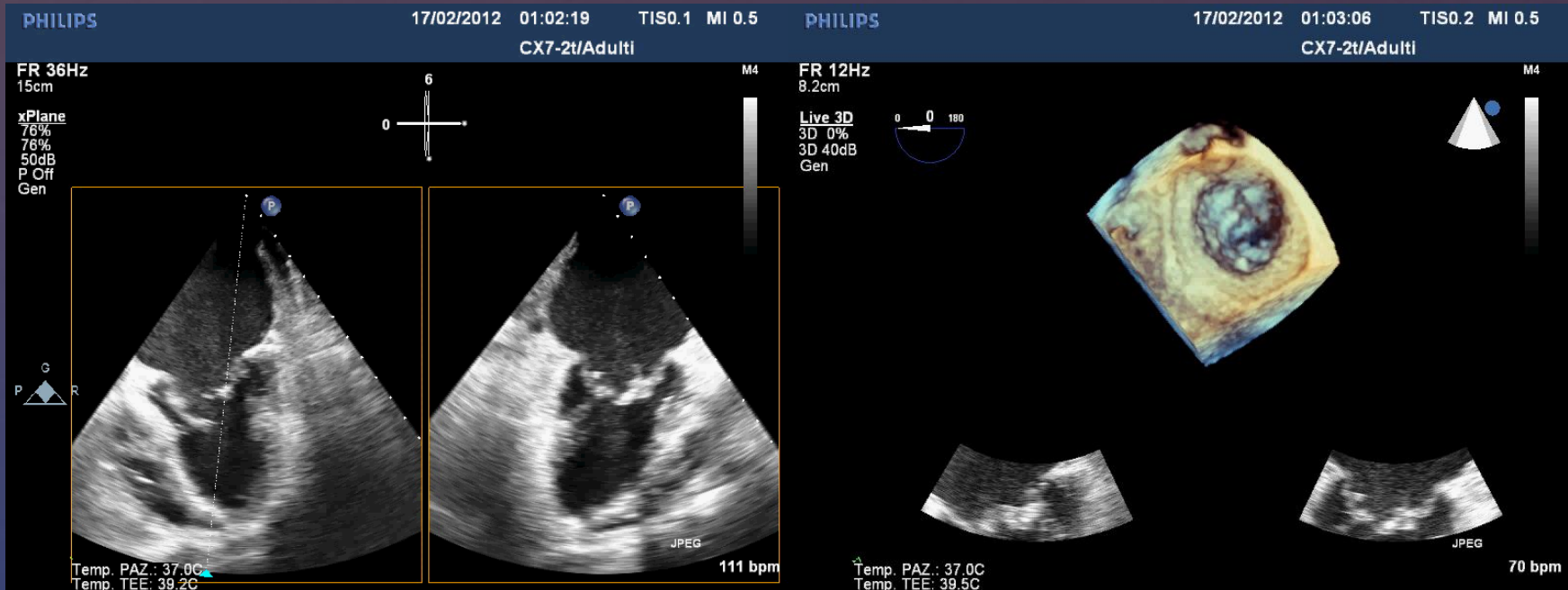


Real-Time 3D Echocardiographic Quantification of Left Atrial Volume

Multicenter Study for Validation With CMR

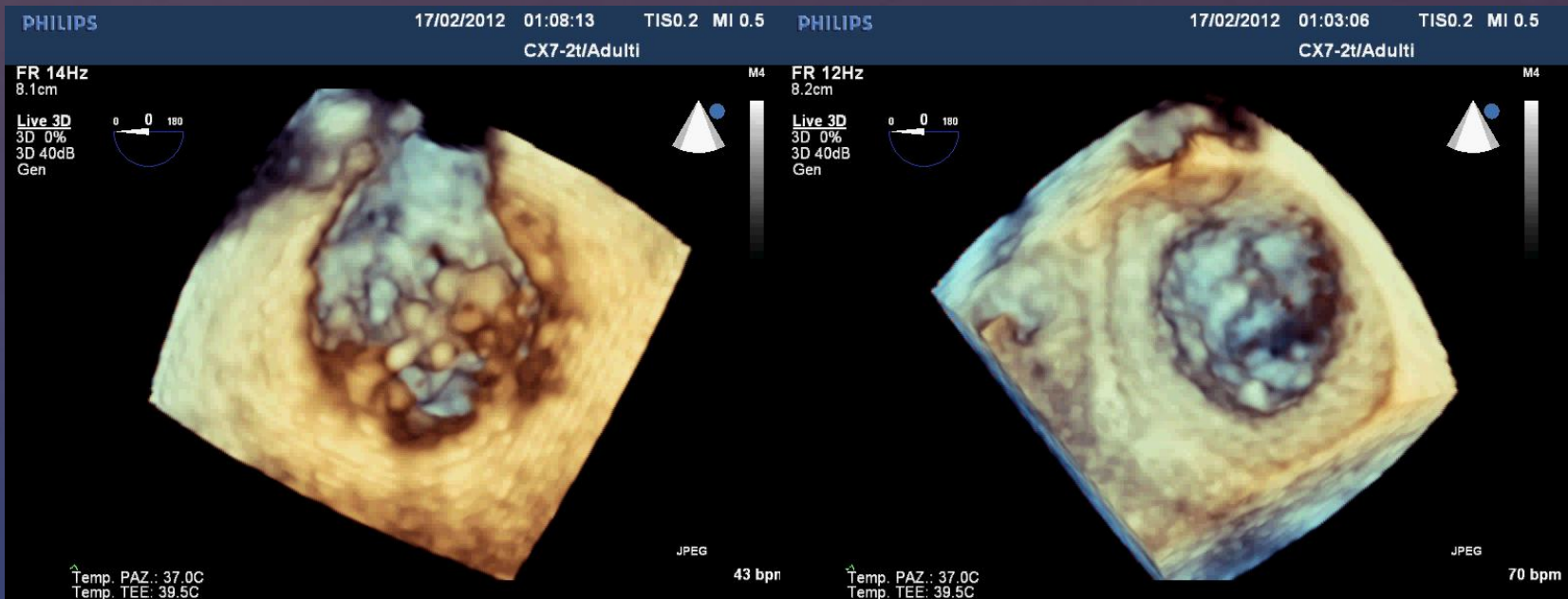
NON LIMITARSI AL DIAMETRO AP





ESEMPIO STENOSI MITRALICA TEE 3D



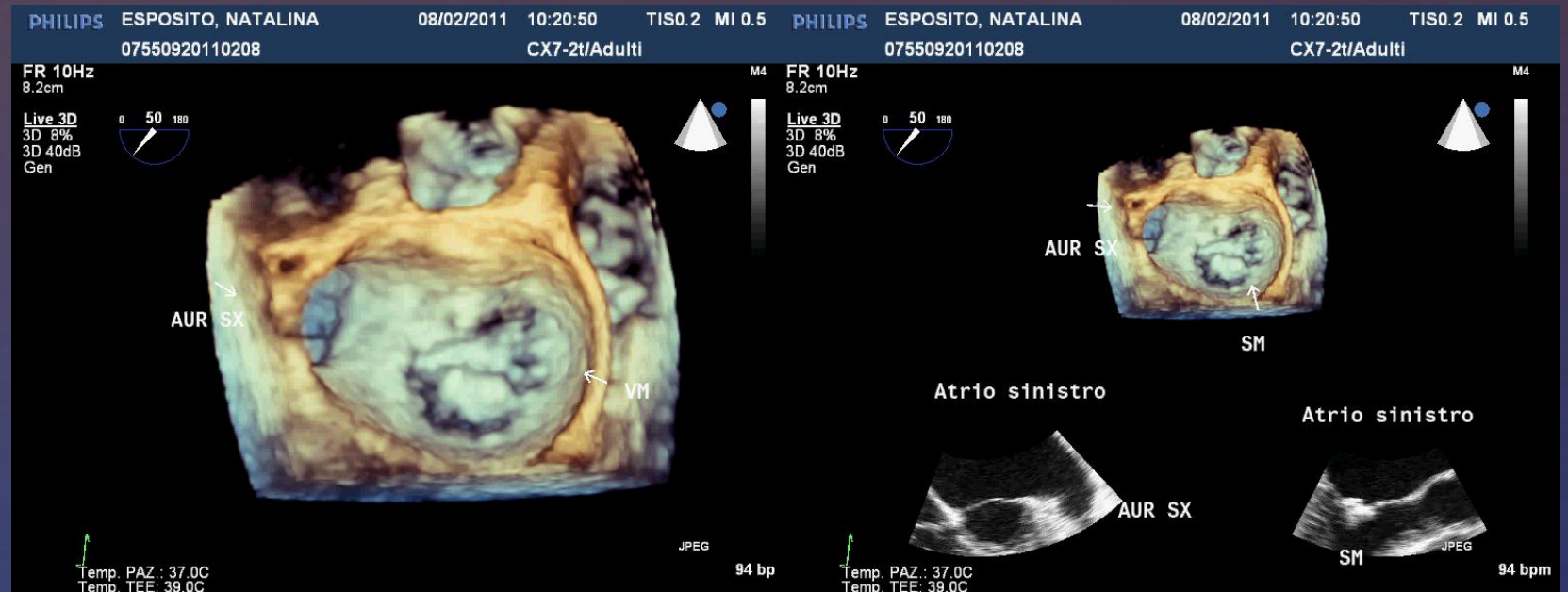


LATO VENTRICO

LATO ATRIALE

ESEMPIO STENOSI MITRALICA TEE 3D

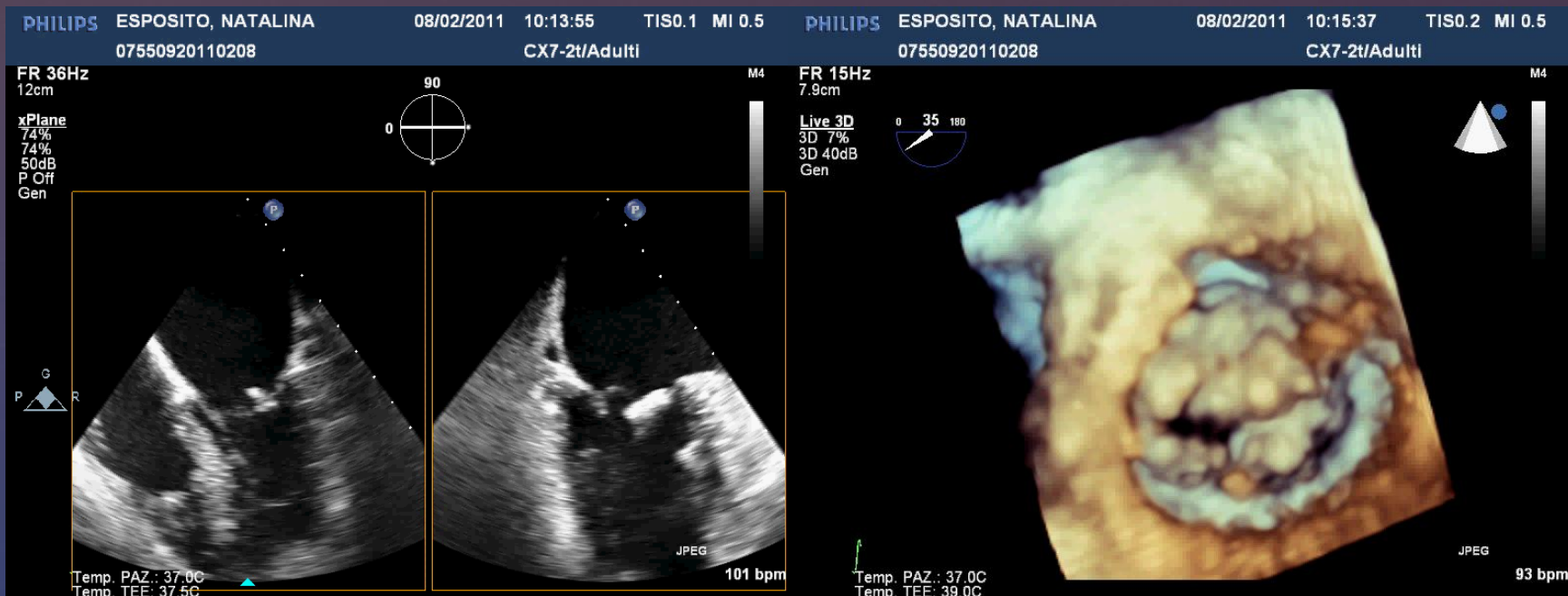




VISIONE CHIRURGICA

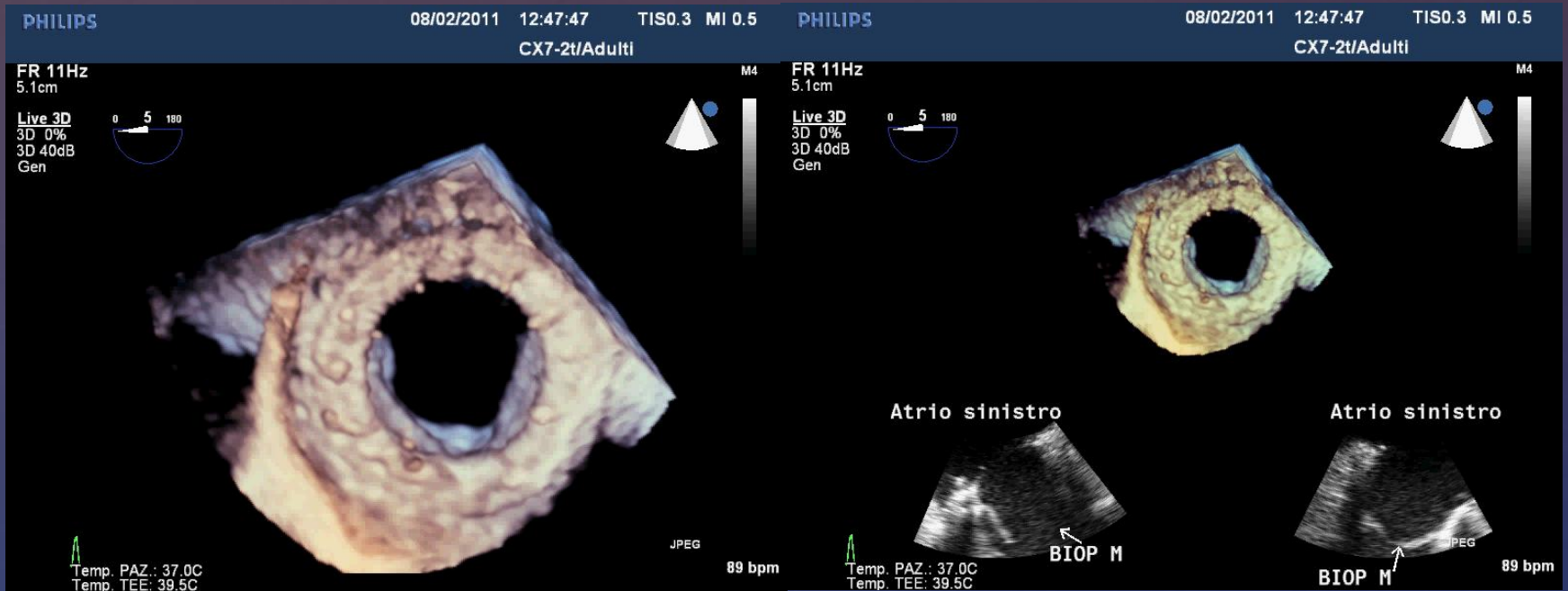STENOSI MITRALICA TEE 3D ES. N° 2





STENOSI MITRALICA CASO N° 2





SOSTITUZIONE VALVOLARE TEE 3D



PHILIPS

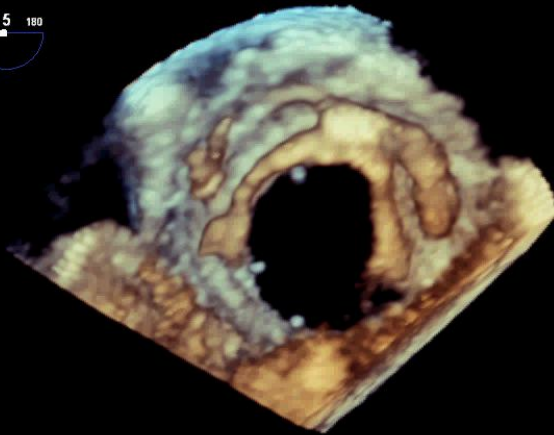
08/02/2011 12:48:59 TIS0.3 MI 0.5
CX7-2t/Adulti

PHILIPS

08/02/2011 12:48:59 TIS0.3 MI 0.5
CX7-2t/Adulti

FR 11Hz
5.1cm

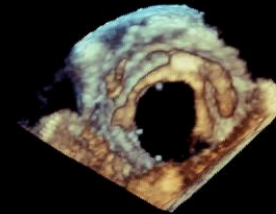
Live 3D
3D 0%
3D 34dB
Gen



M4

FR 11Hz
5.1cm

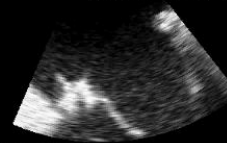Live 3D
3D 0%
3D 34dB
Gen



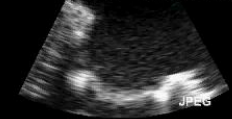BIOP MITR
LATO VENT

M4

Atrio sinistro



Atrio sinistro



Temp. PAZ : 37.0C
Temp. TEE : 40.1C

JPEG

92 bpm

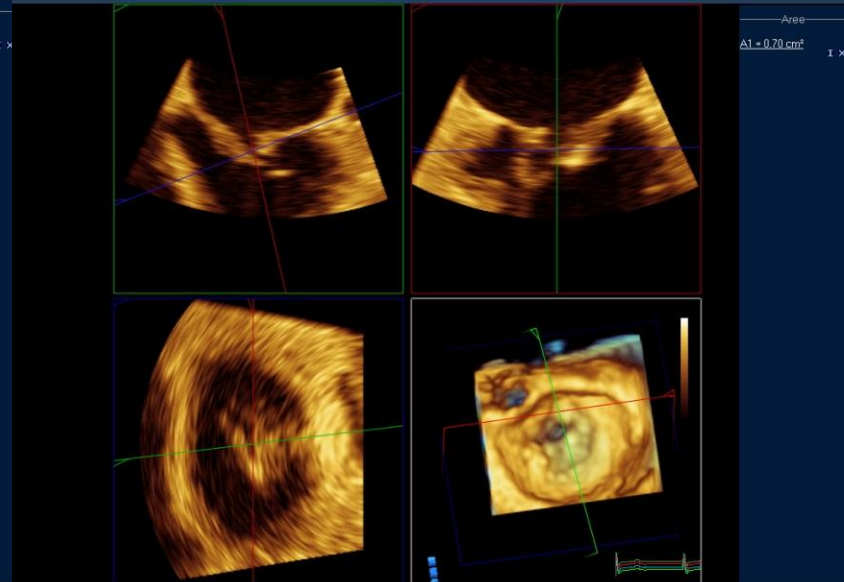
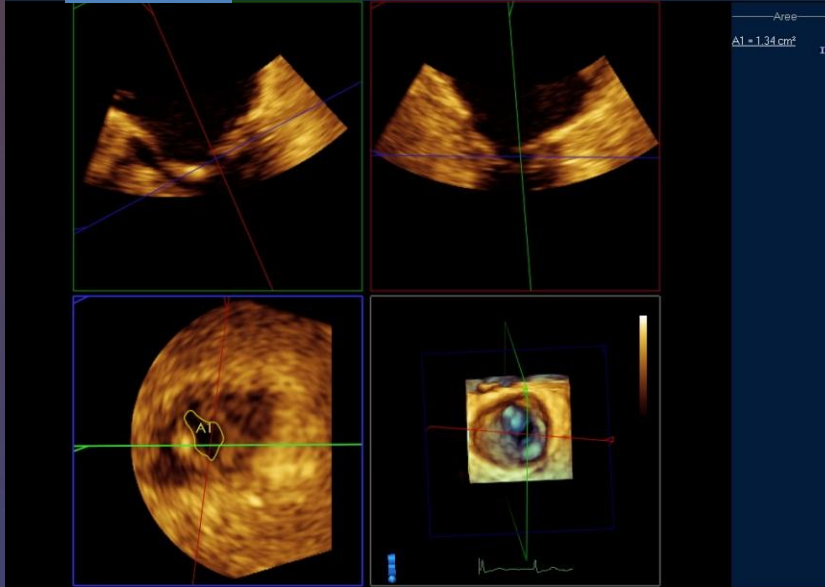
Temp. PAZ : 37.0C
Temp. TEE : 40.1C

JPEG

92 bpm

BIOPROTESI MITRALICA TEE 3D





EDITORIAL COMMENT

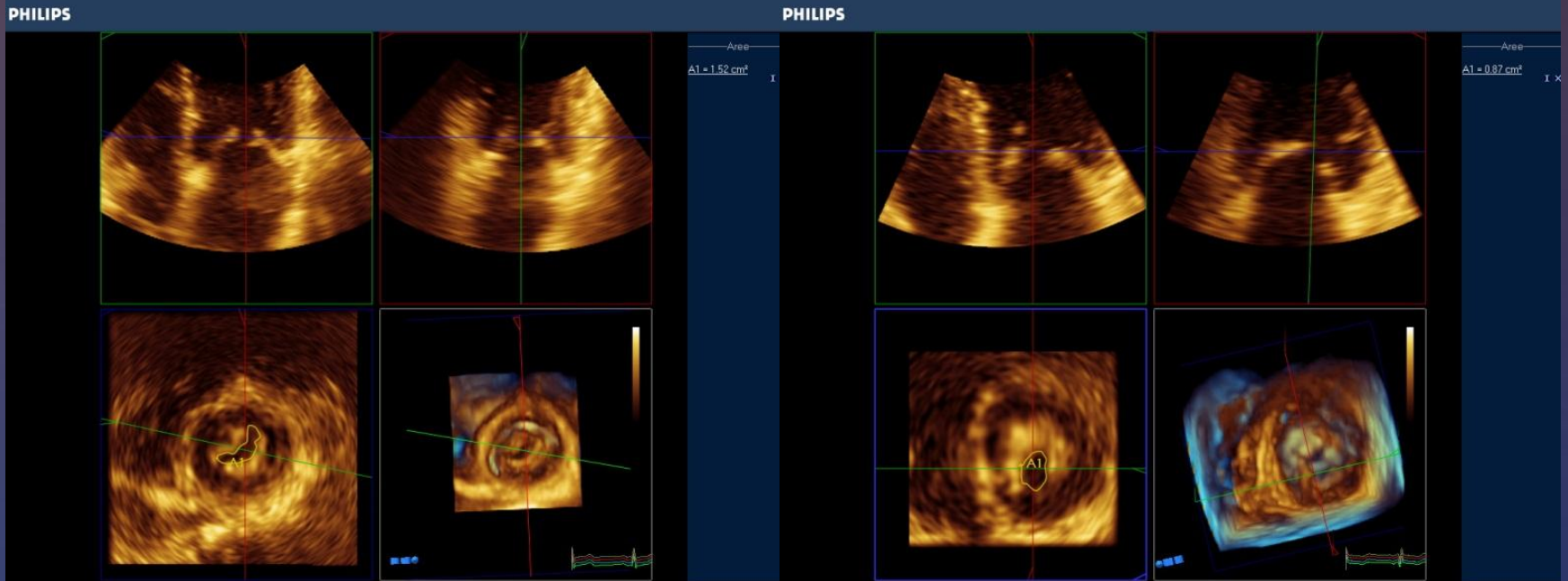
Assessment of Mitral Stenosis: Role of Real-Time 3D TEE*

Arthur E. Weyman, MD
Boston, Massachusetts

system being studied. When viewed from the esophagus using real-time 3D echocardiography, the mitral valve orifice will be recorded using the lateral resolution of the system. In this projection, the relatively sparse line density of the 3D system necessitates greater interpolation and smoothing, which, together with the point spread function of the scanning beam, results in a displayed area that is smaller than the actual valve orifice size. In contrast,

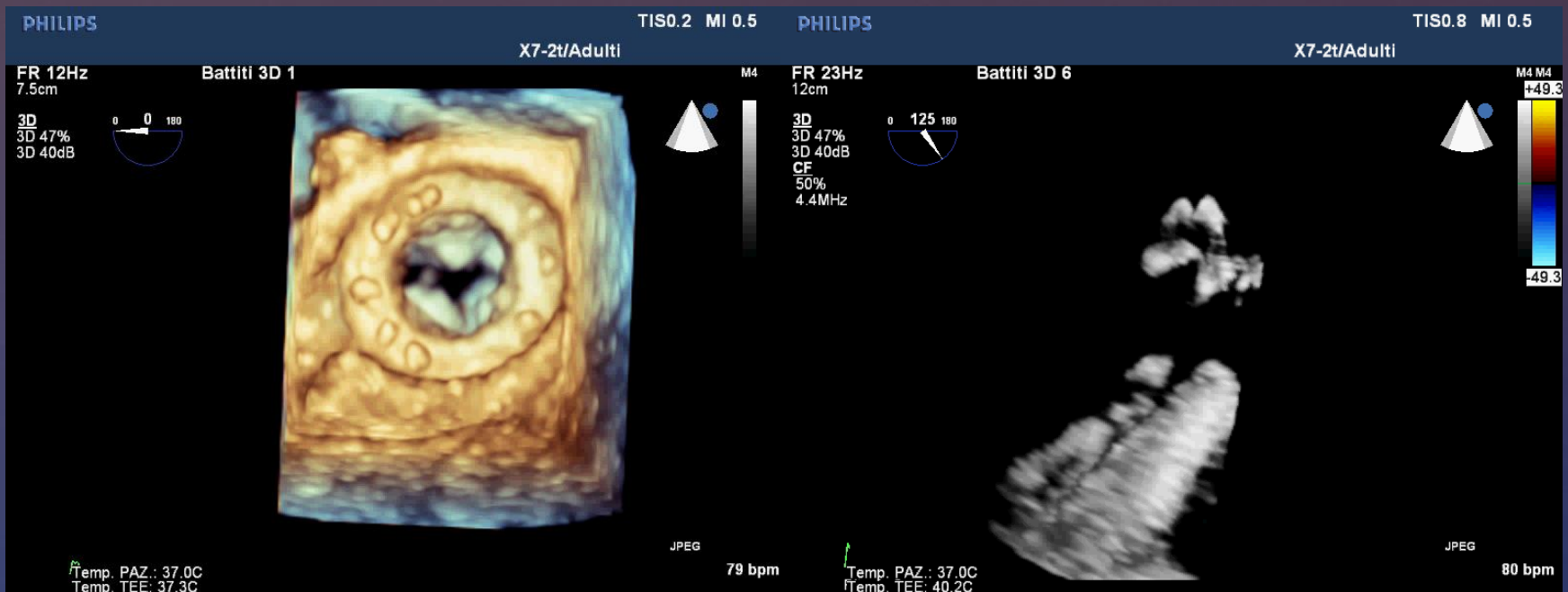
AREA MITRALE TEE 3D





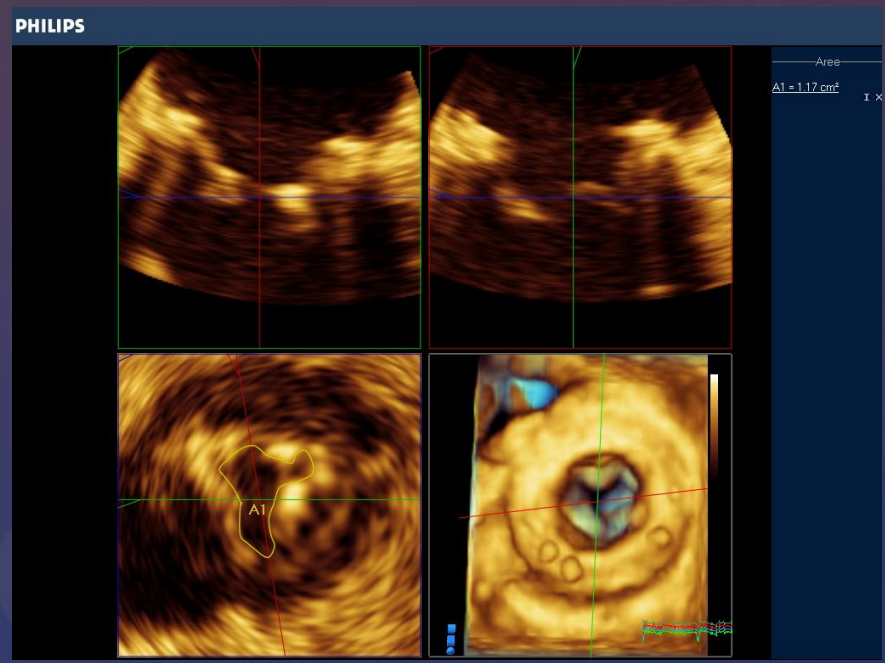
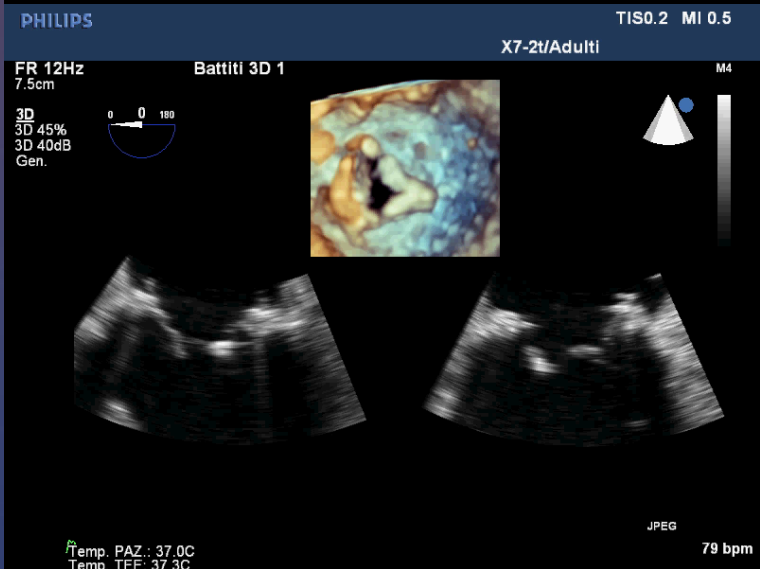
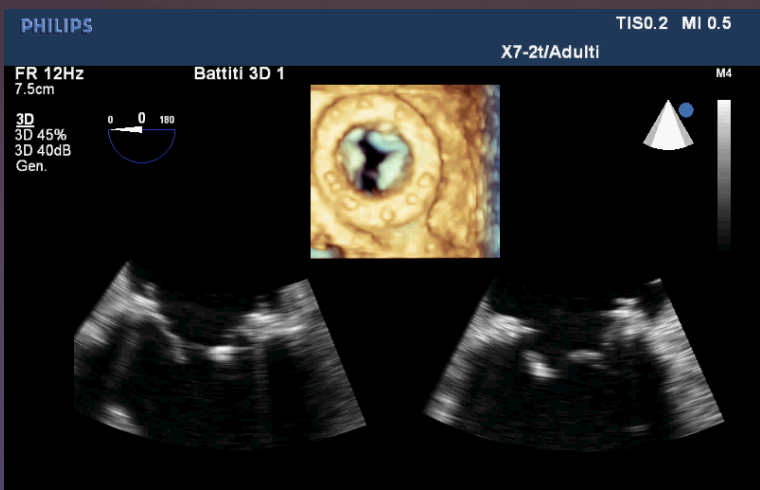
AREA MITRALE: TTE 3D





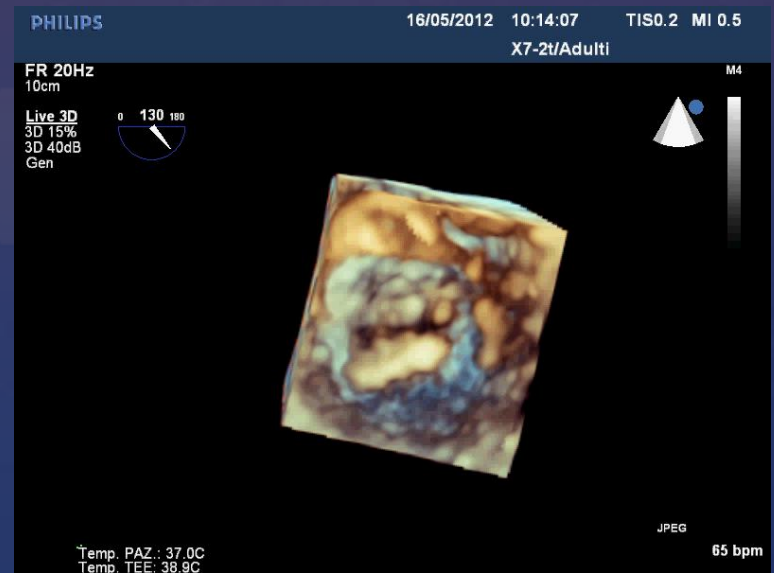
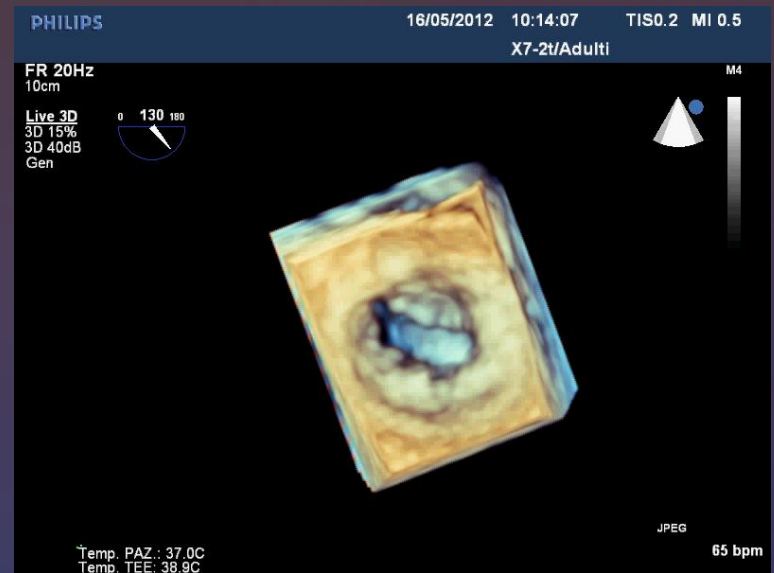
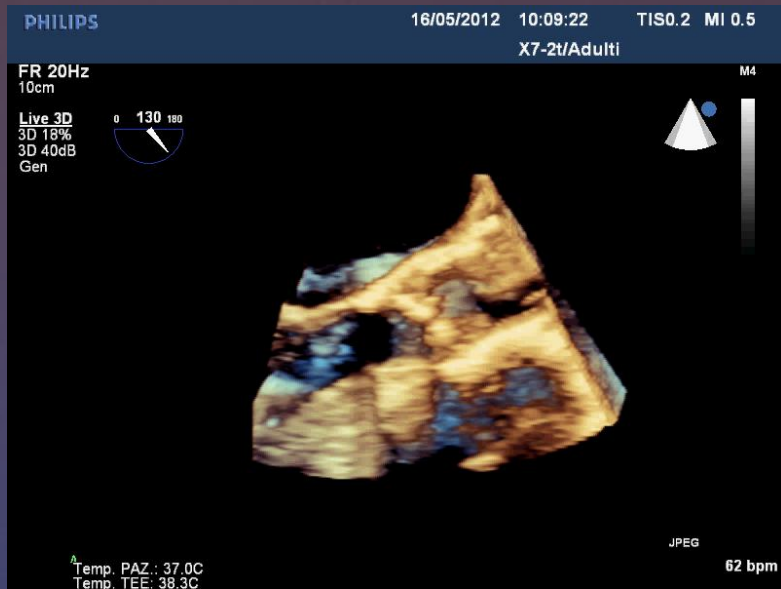
VALUTAZIONE AREA BIOPROTESI MITRALICA TEE 3D





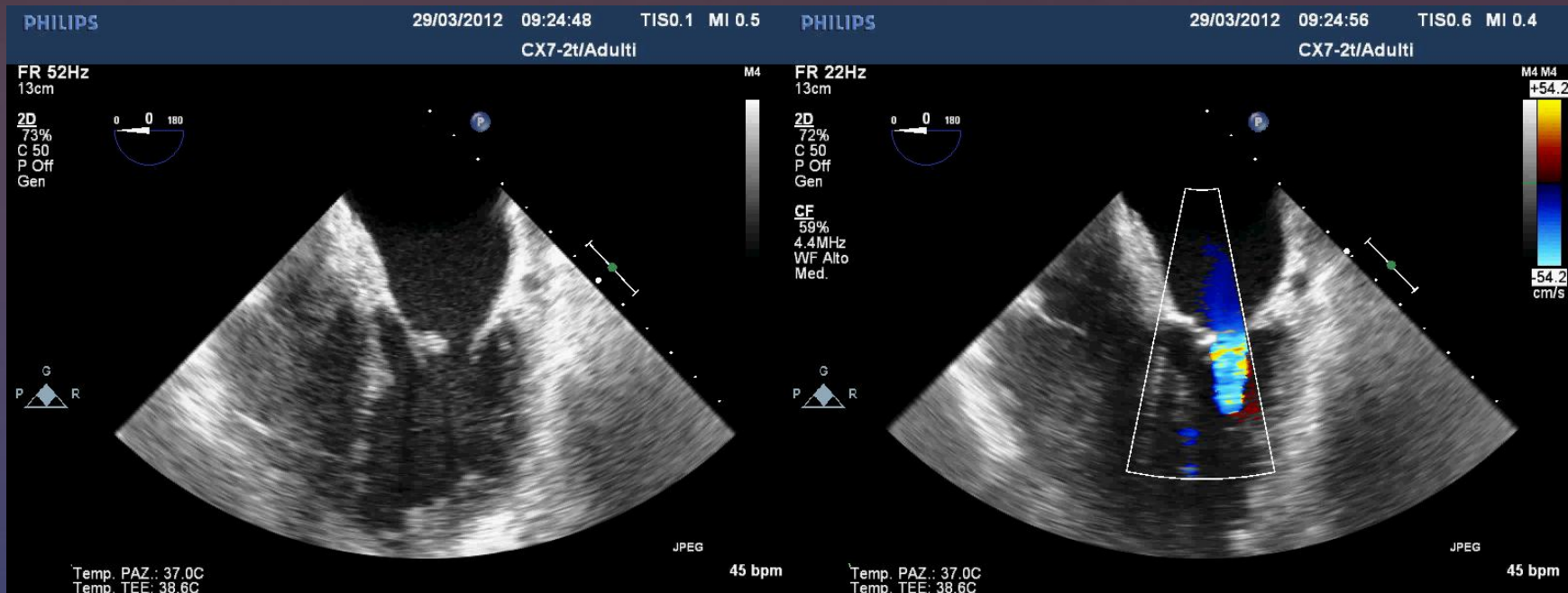
VALUTAZIONE AREA BIOPROTESI MITRALICA TEE 3D





SAO + DEG MITR 3 D TEE

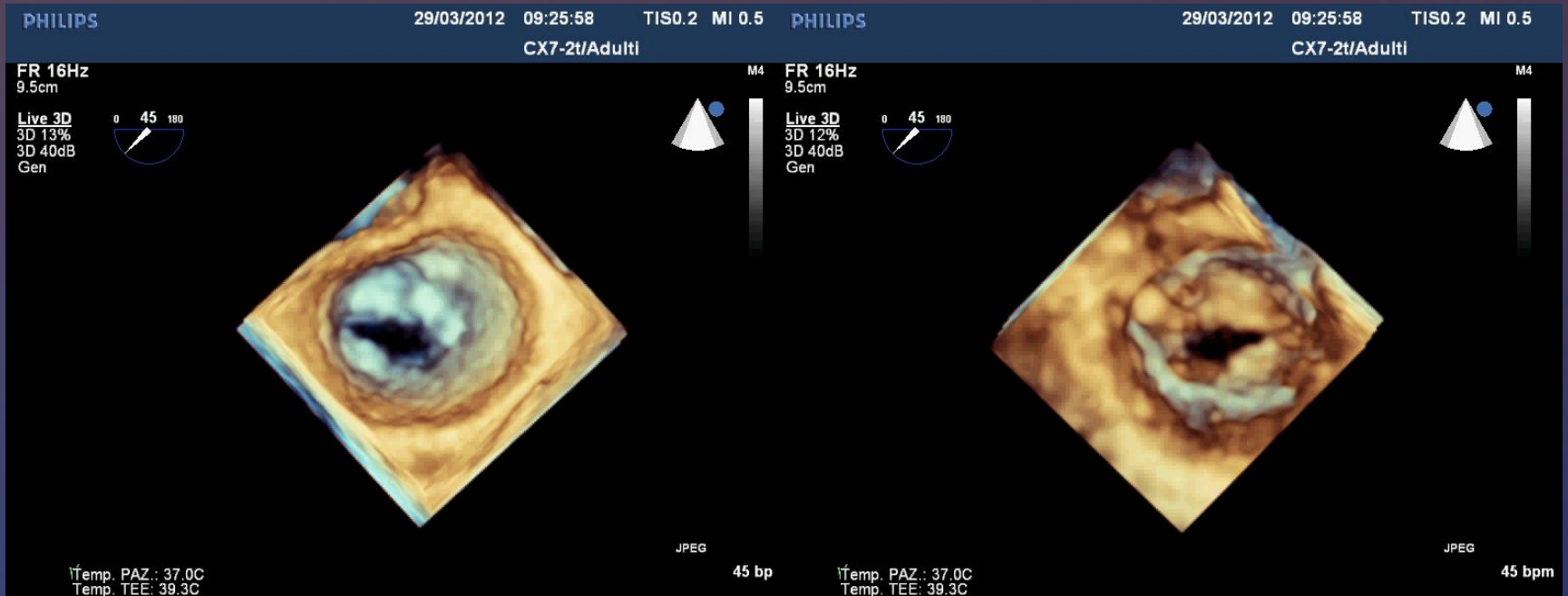




PAZ 71 a
INVIATO PER SM +
STENOSI IVA PROX

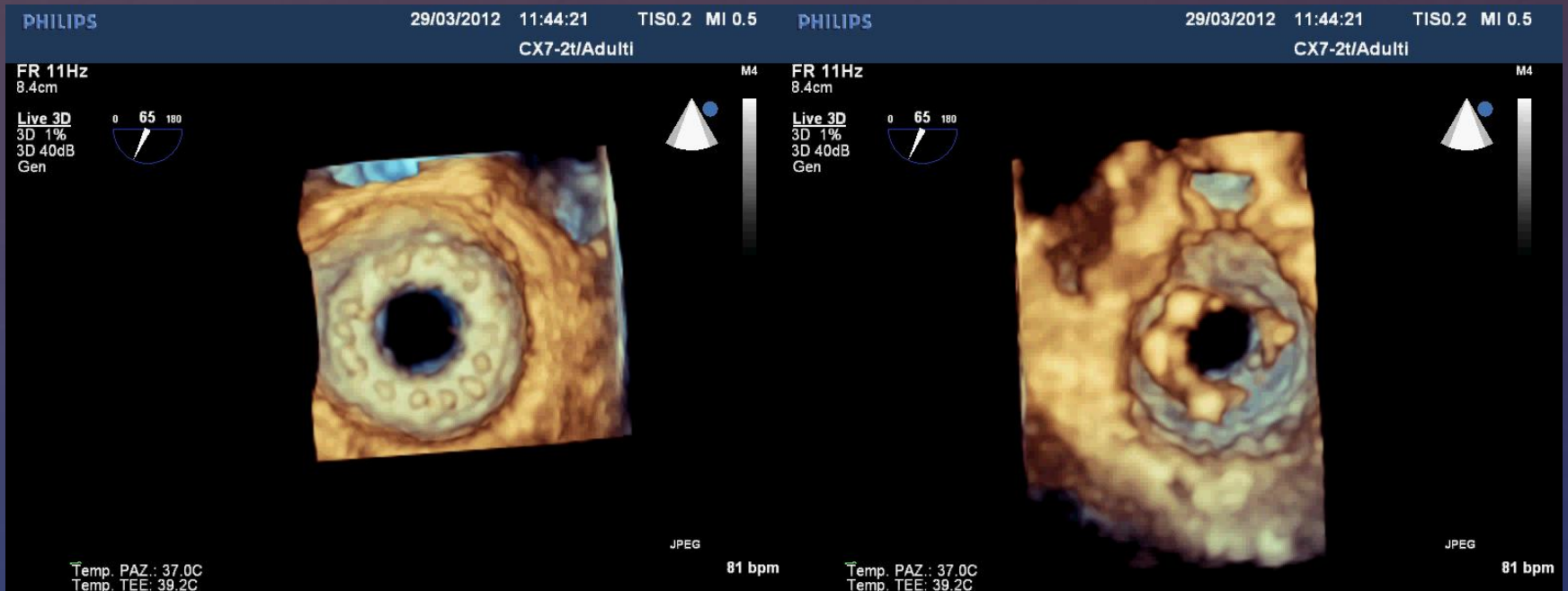
ALTERAZIONE DEGENERATIVA: PREOP
TEE 2D





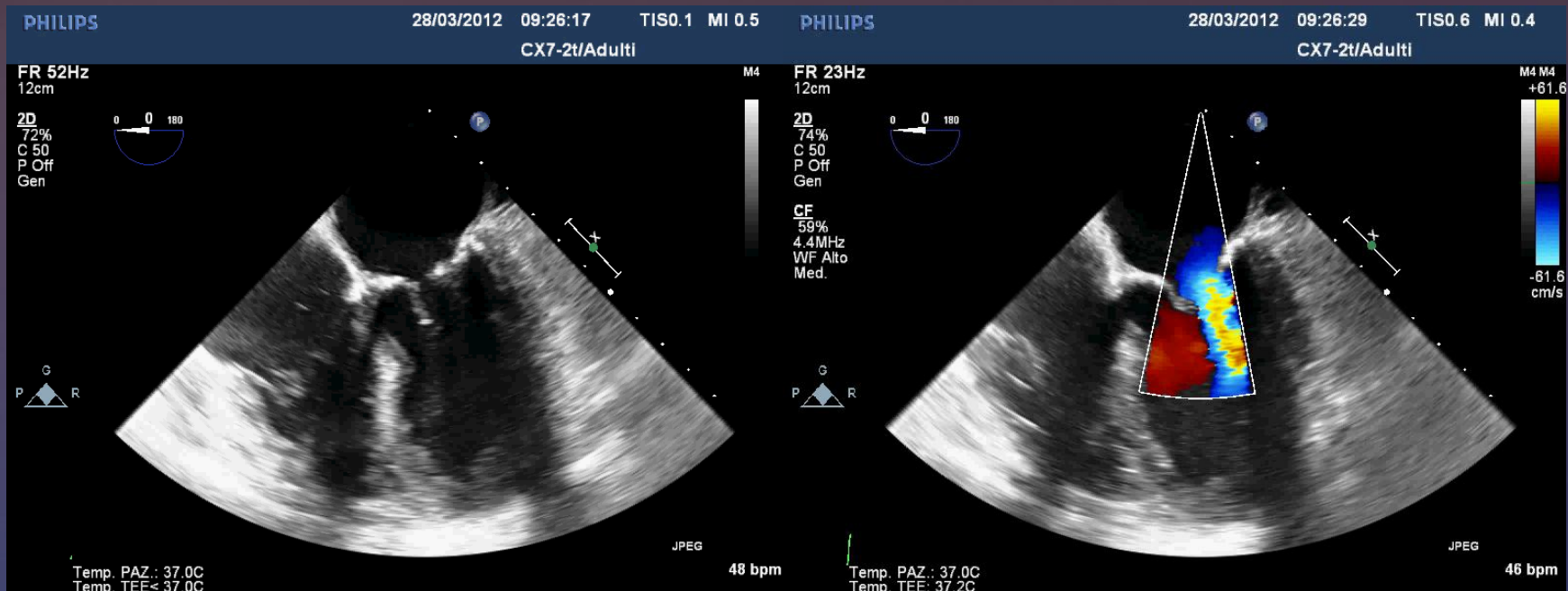
ECO TEE 3D: PREOP





SOSTITUZIONE VALVOLARE

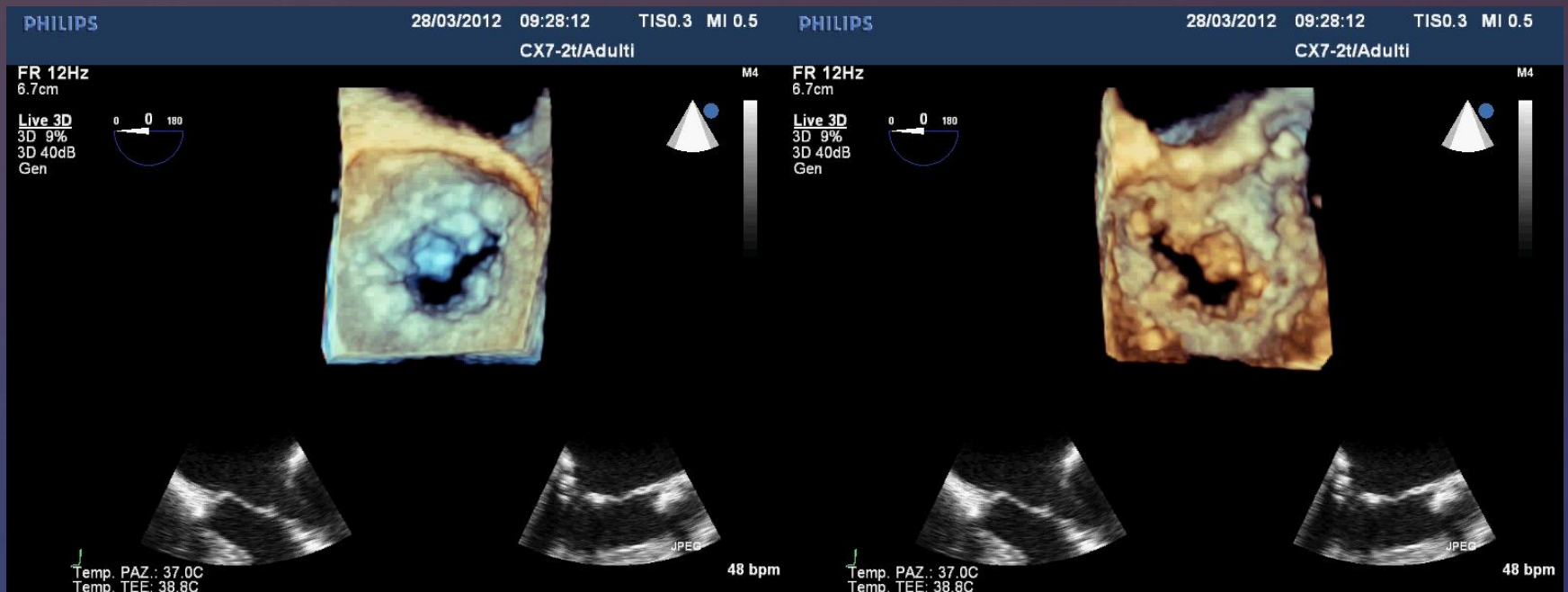




PAZIENTE 67 SESSO FEMM
 MALATTIA COR BIVAS (IVA + CD)
 CLASSE NYHA II

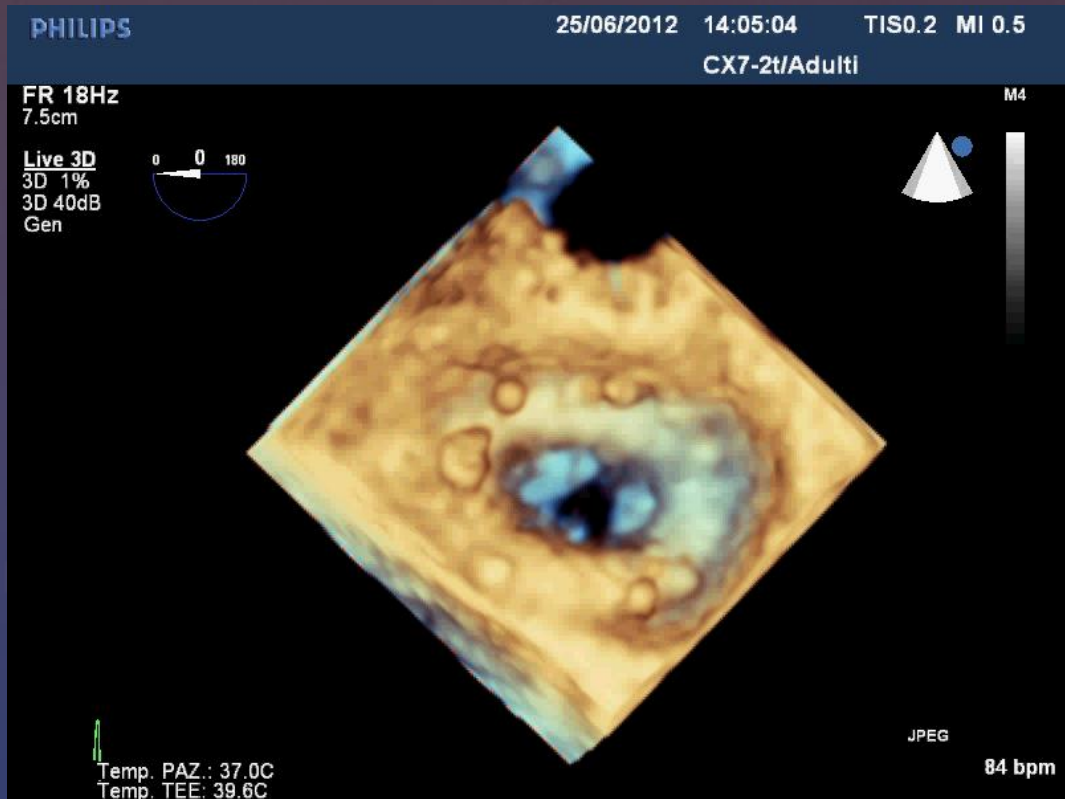
TEE 2D VALV MITRALE





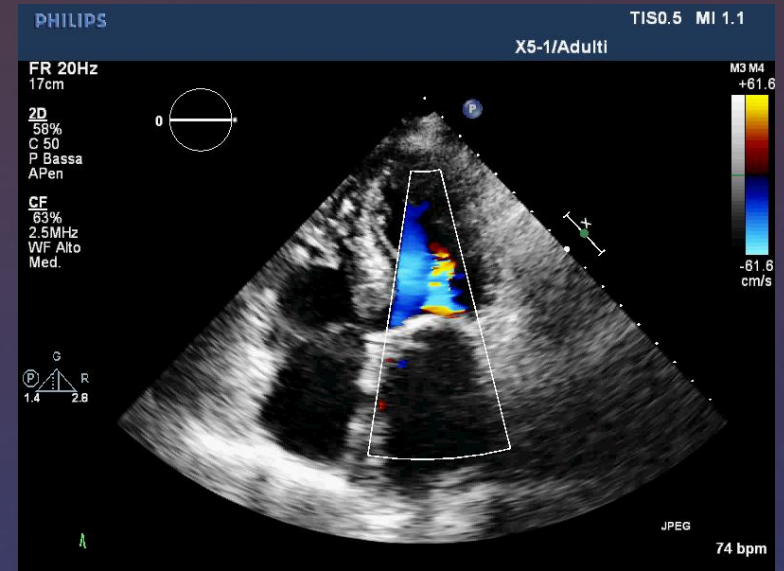
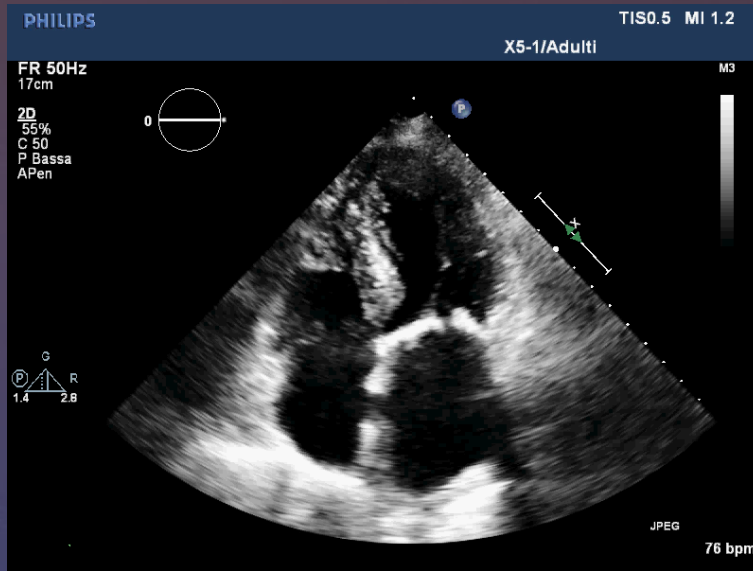
TEE 3D VALV MITRALE





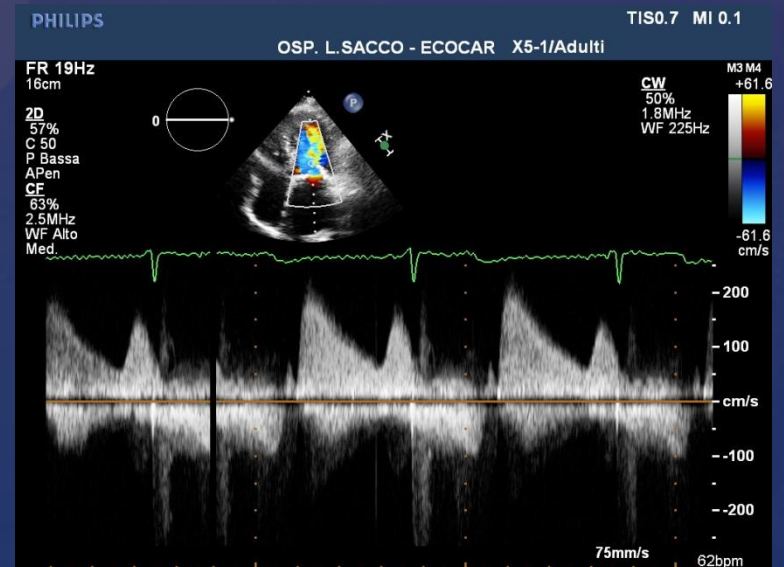
PLASTICA MITRALE

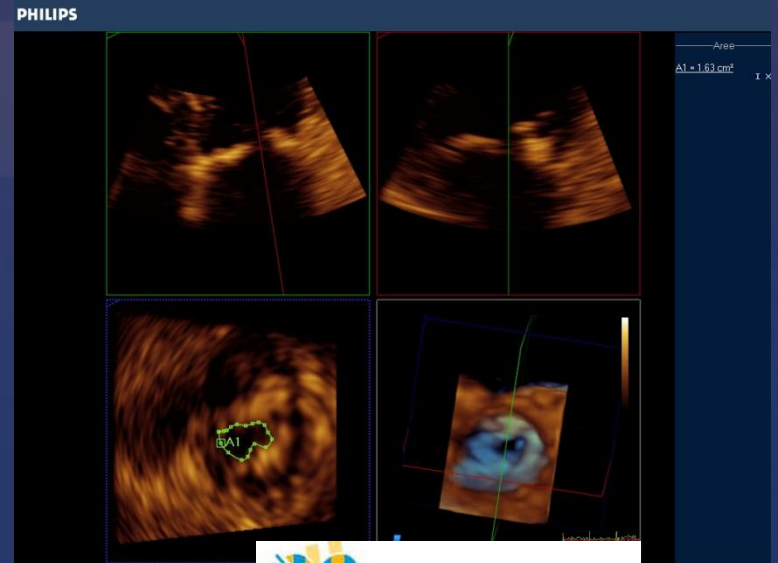
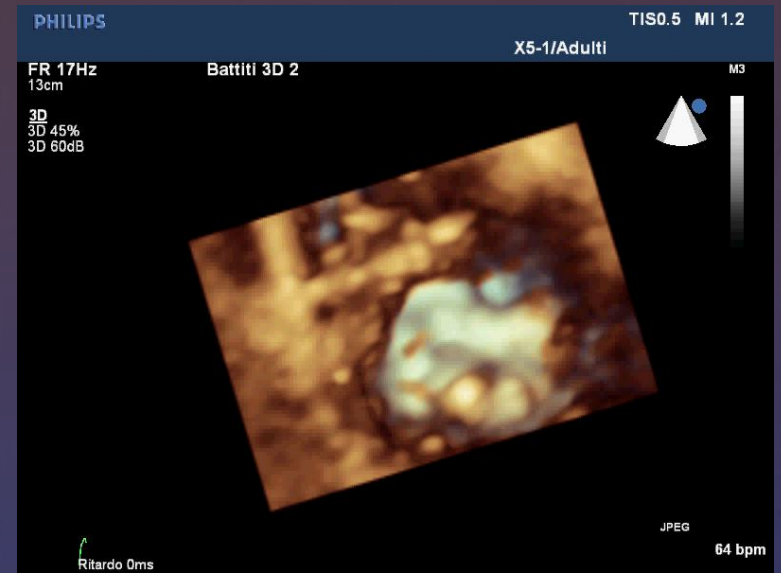
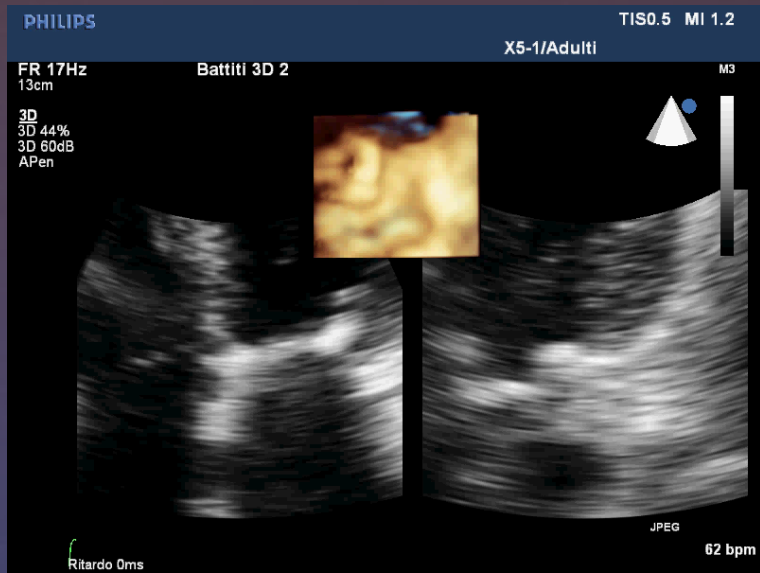




PAZIENTE 75 ANNI
CORONAROP TRIVASALE

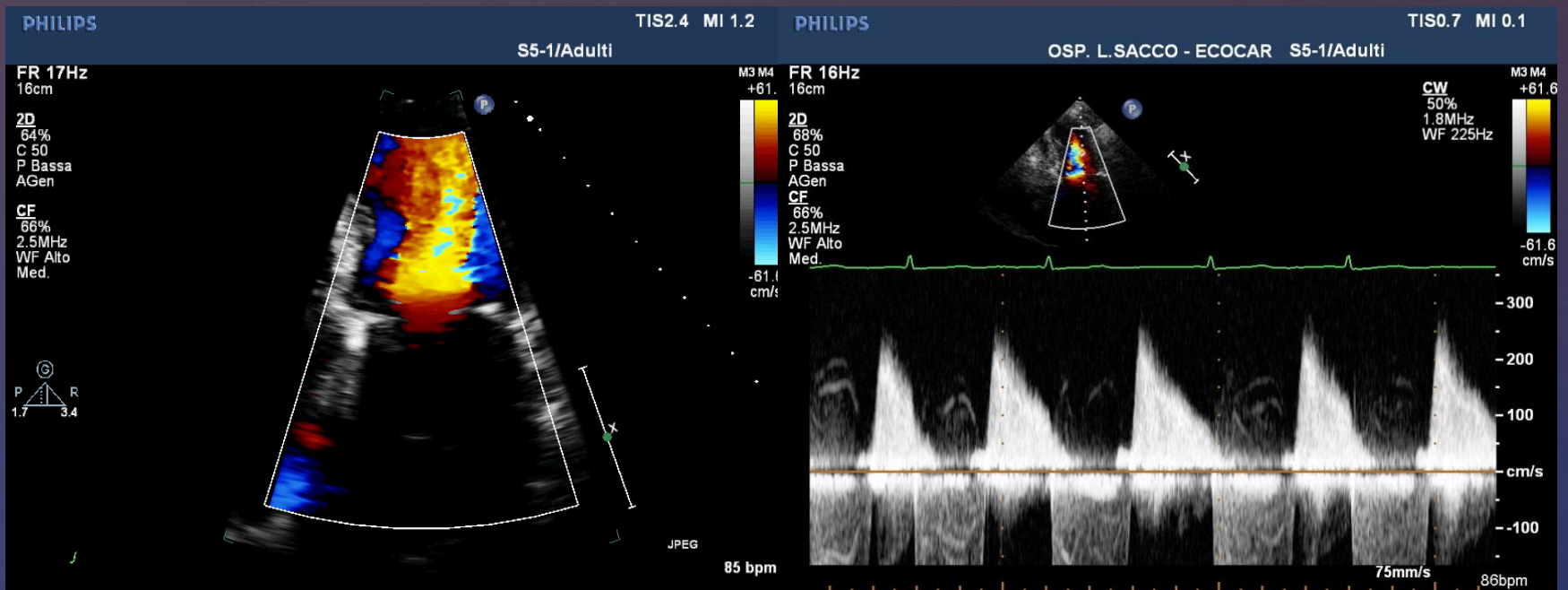
TTE DEG MITR





AREA 3D TTE

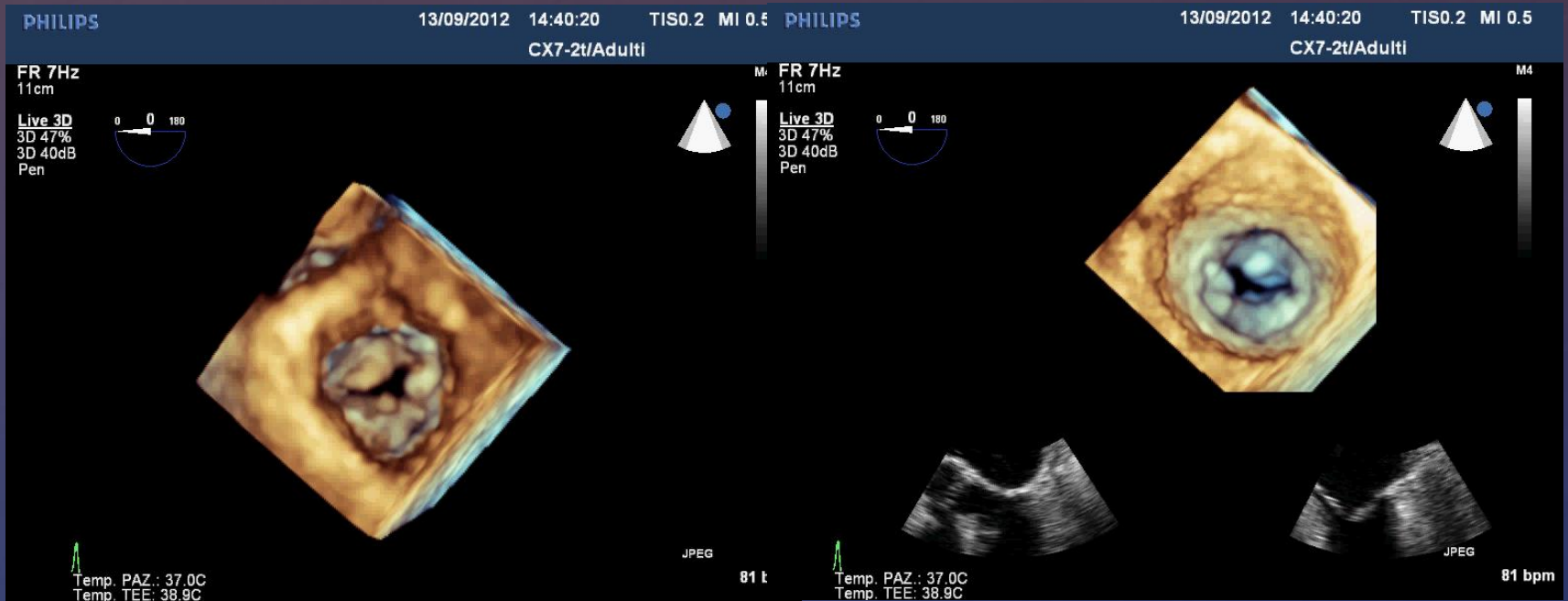



PAZ 65 a BPCO,
OBESITA', SIM REUM

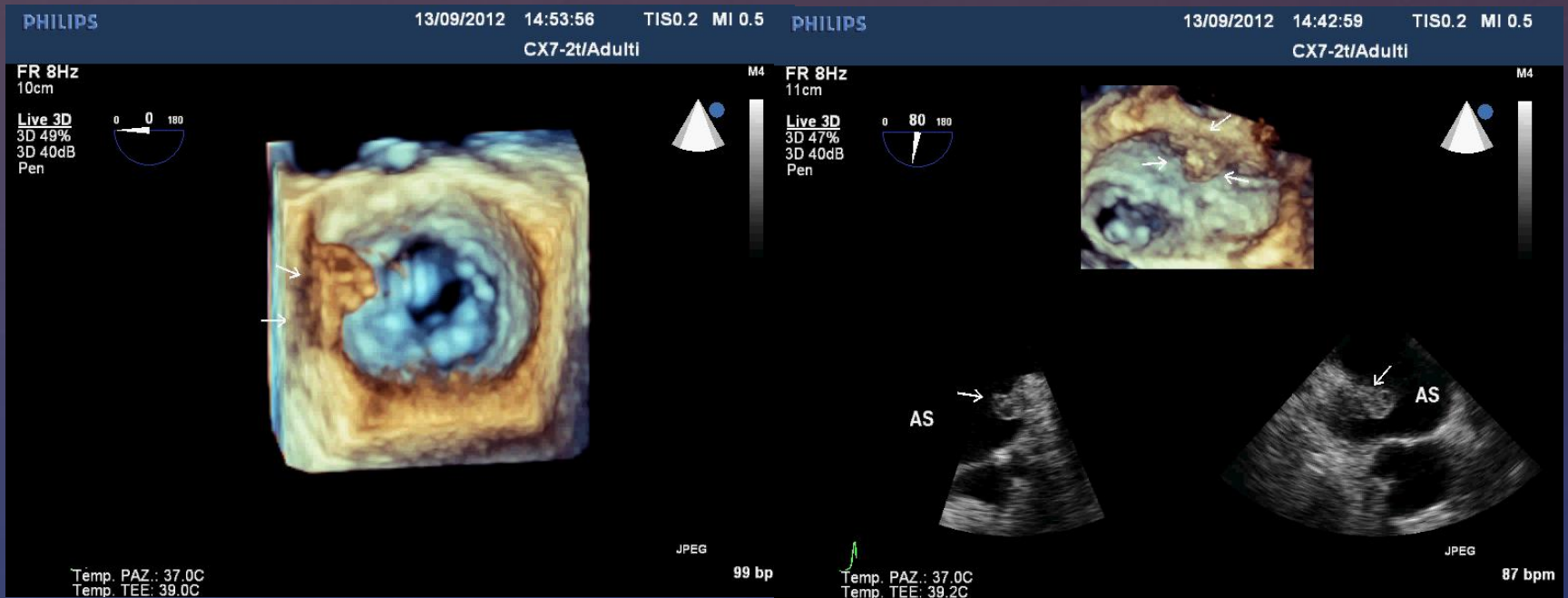
SIM: TTE 2D





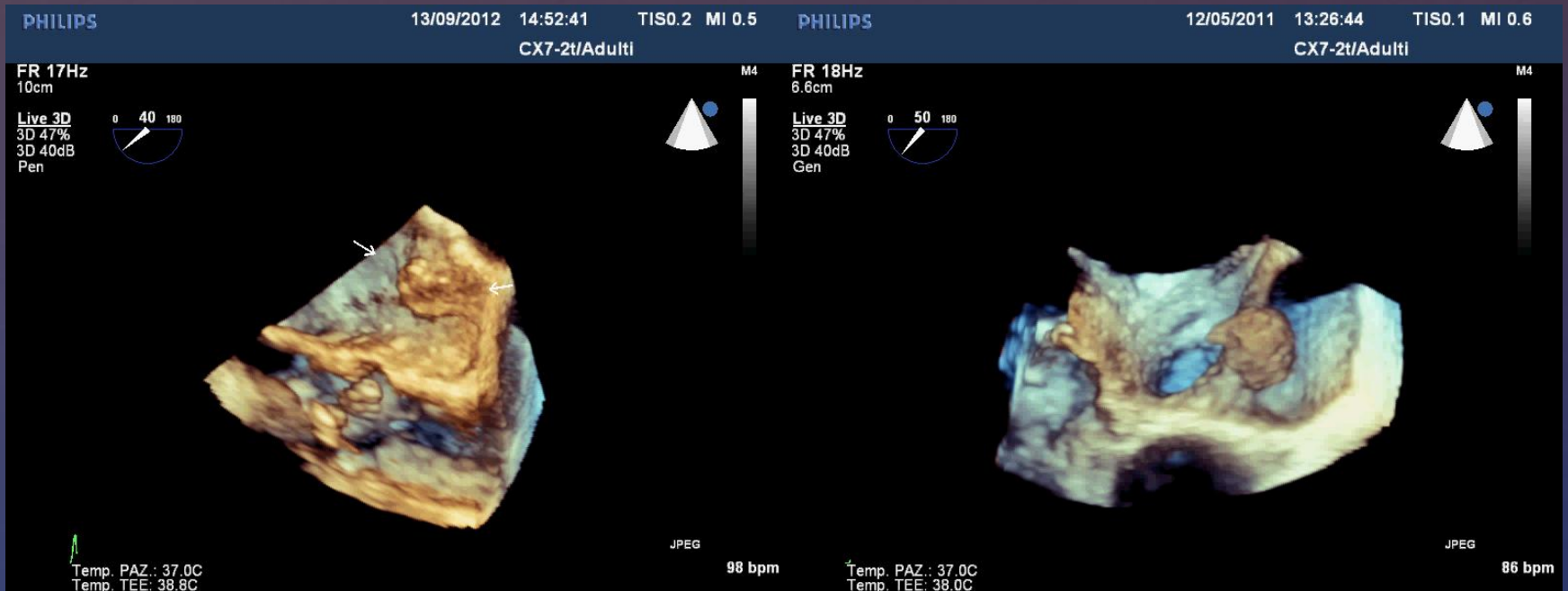
SM TEE 3D





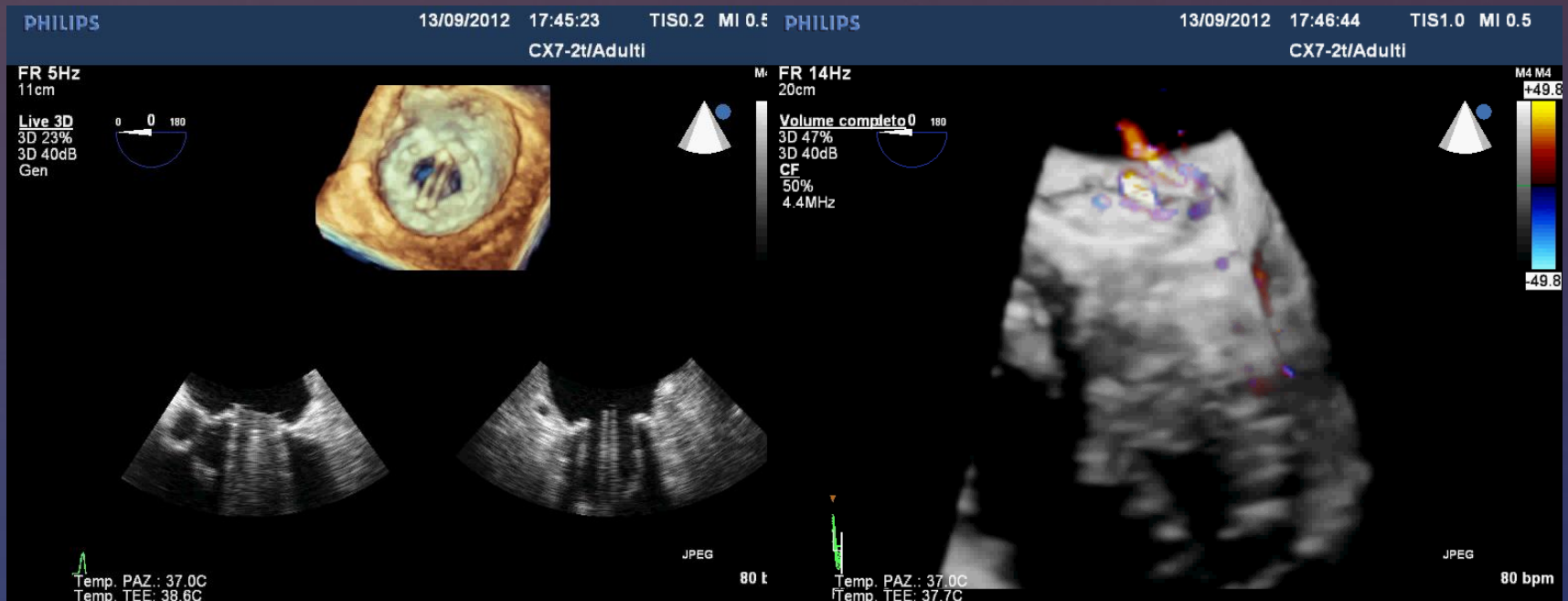
TROMBO AS TEE 3D





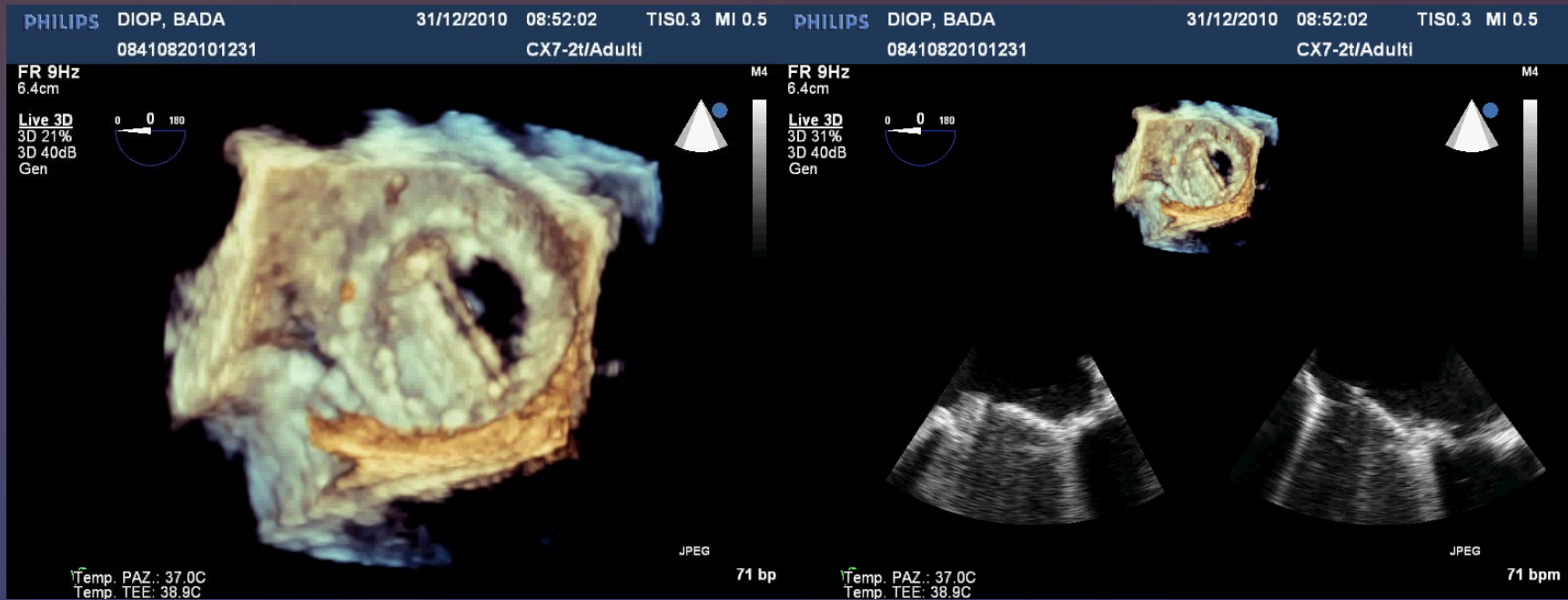
CONFRONTO TROMBO/MIXOMA AS 3D TEE





PROTESI MITRALICA MECCANICA TEE 3D

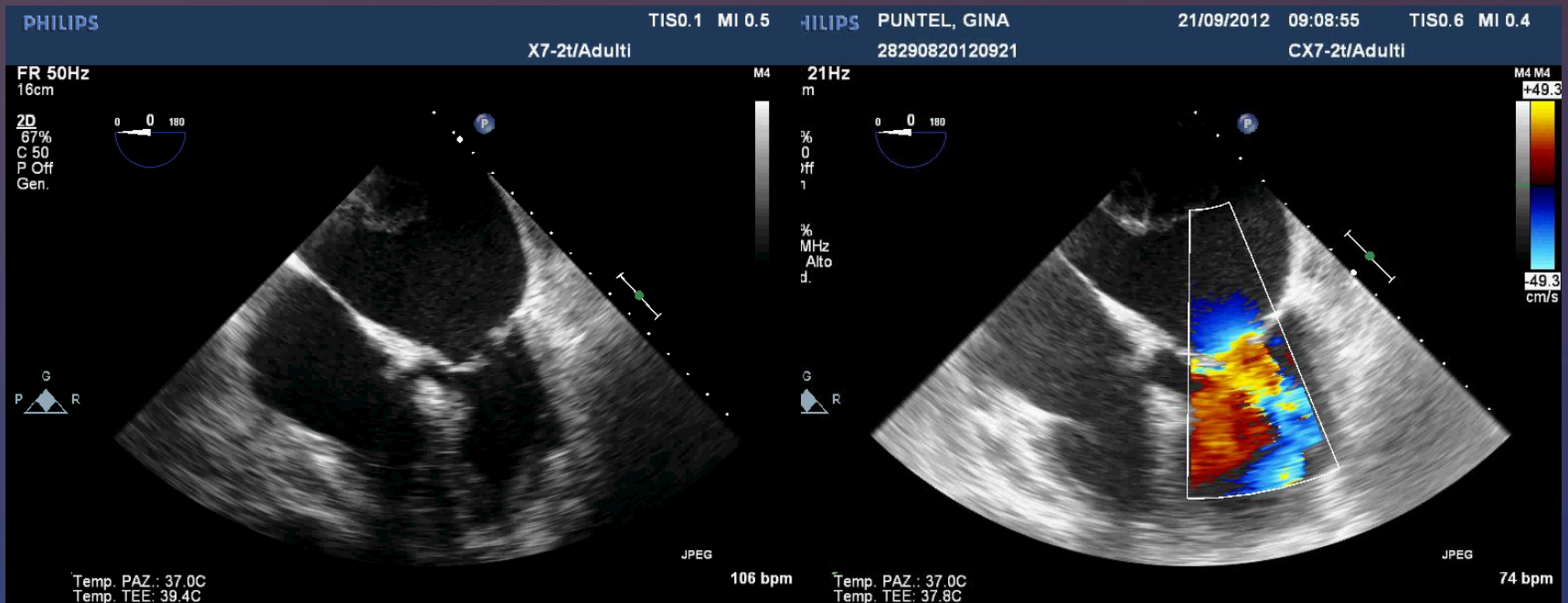




PAZIENTE 41 ANNI
SIM + IAO
PROTESI MITRO-AORTICA

PROTESI MITRALICA MECCANICA
TROMBOSI (INR 1,3) TEE 3D

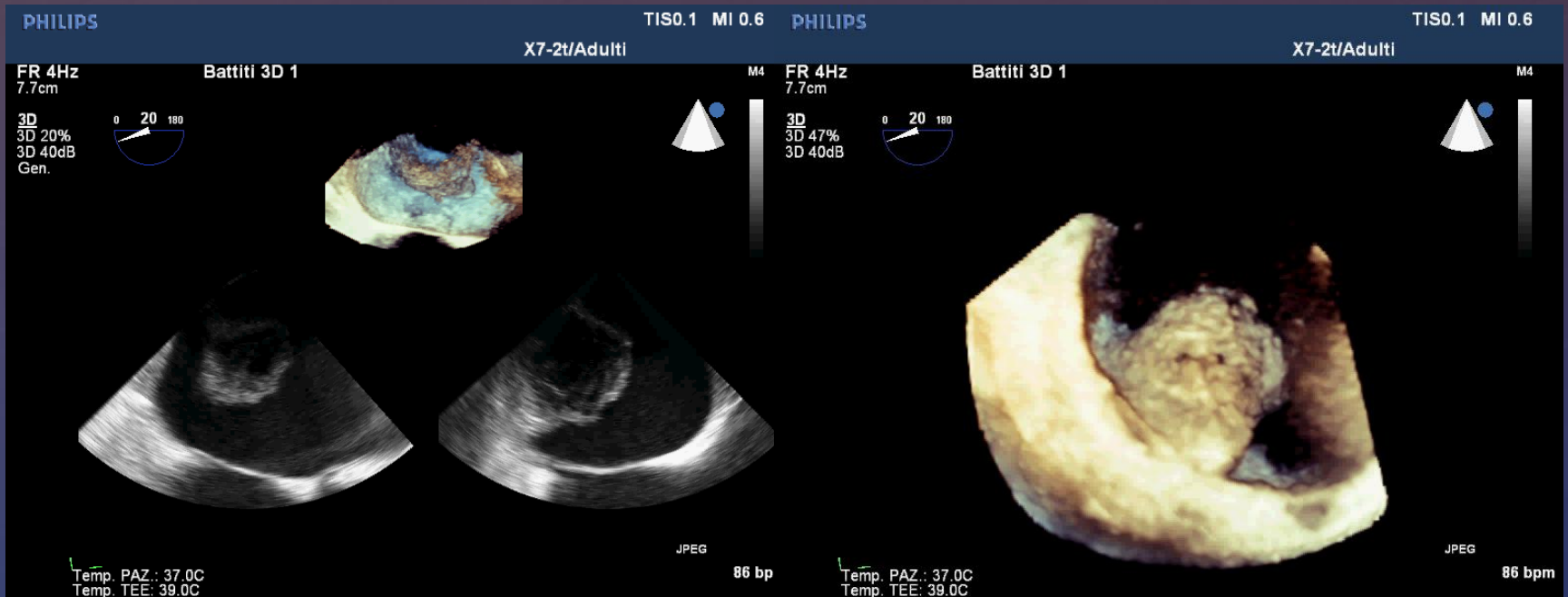




PAZ 68 a
 FA, SM

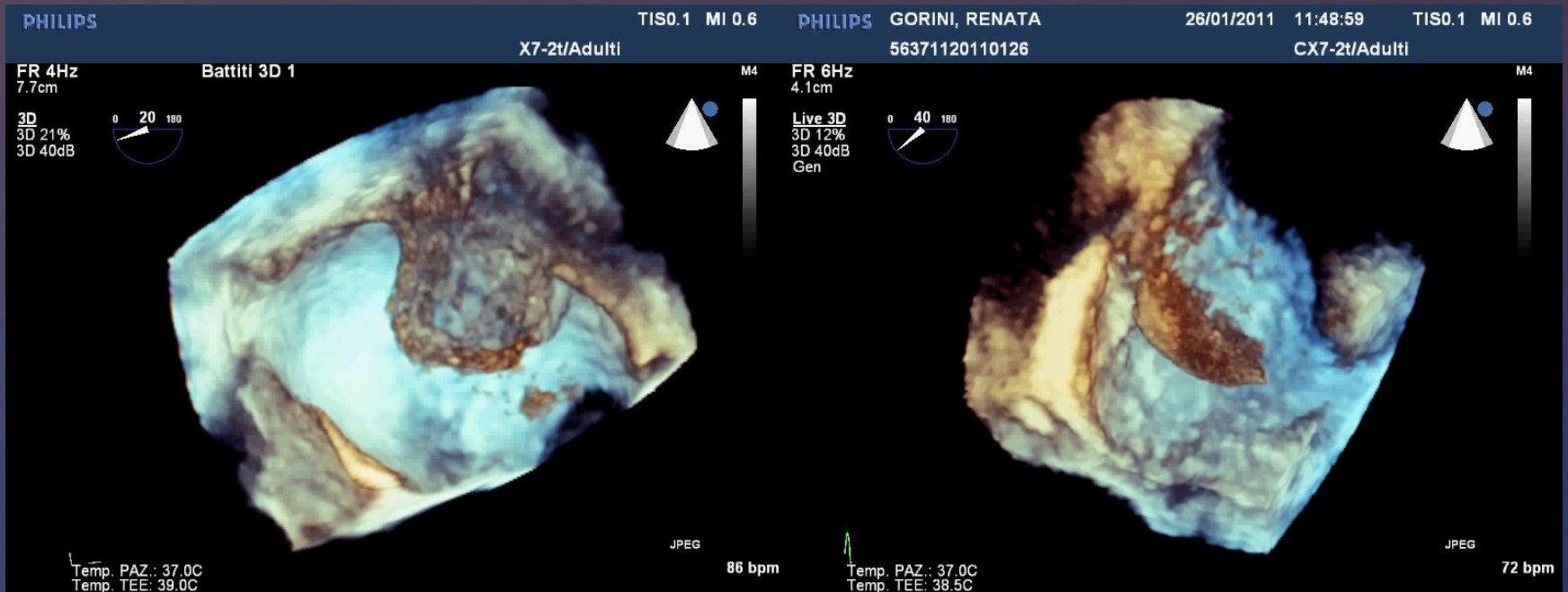
SM + TOMBO AS TEE 2D





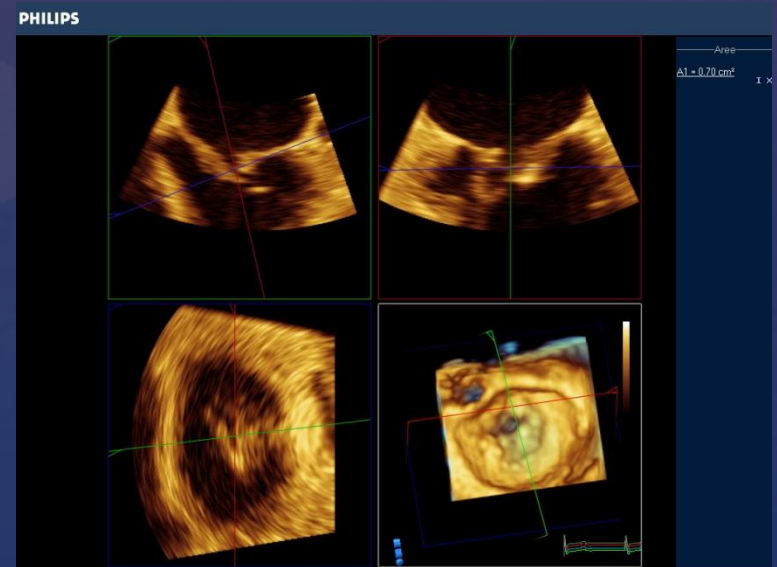
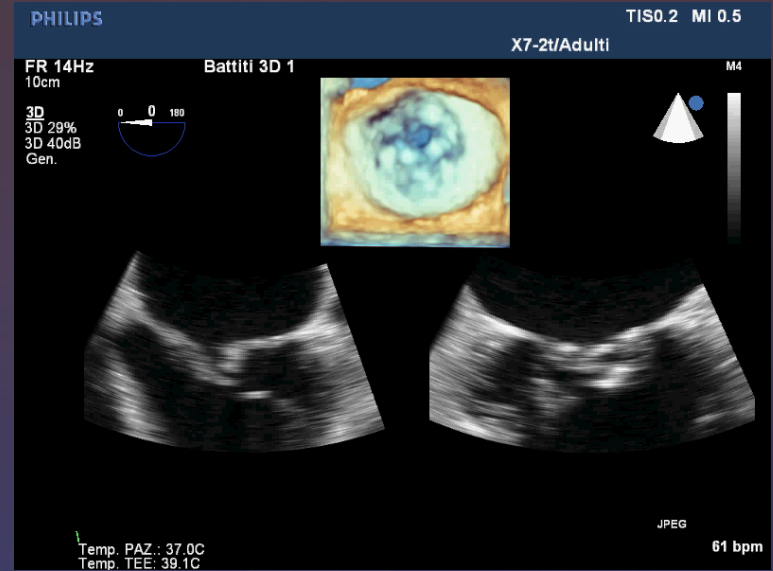
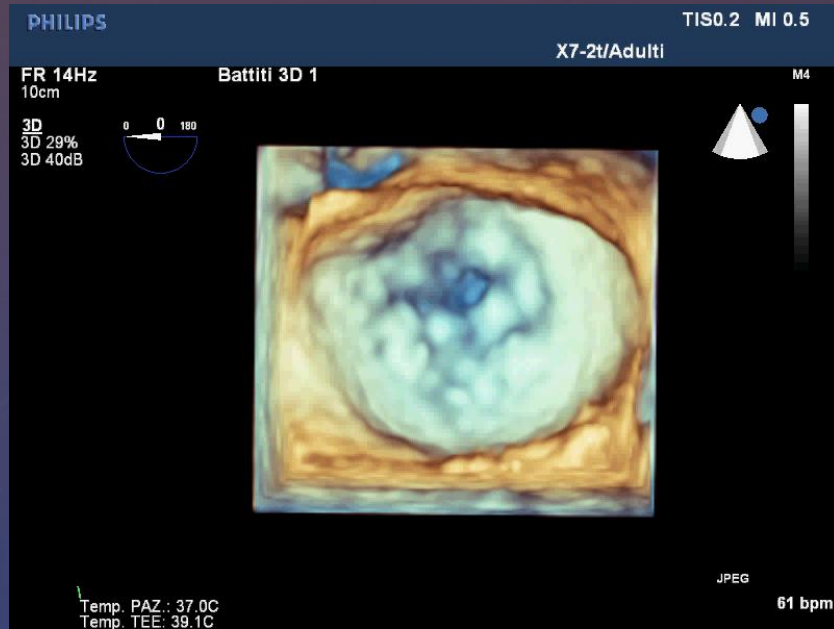
TROMBO AS: TEE 3D





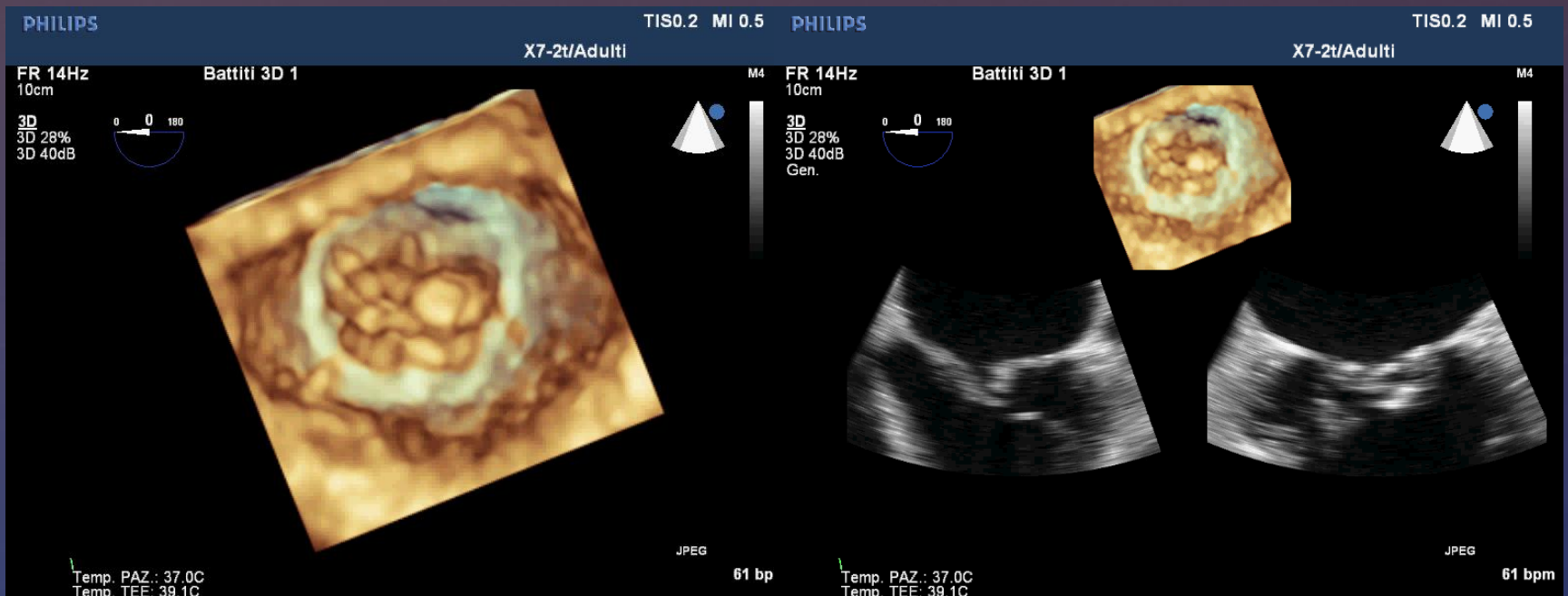
CONFRONTO TROMBO/MIXOMA: TEE 3D





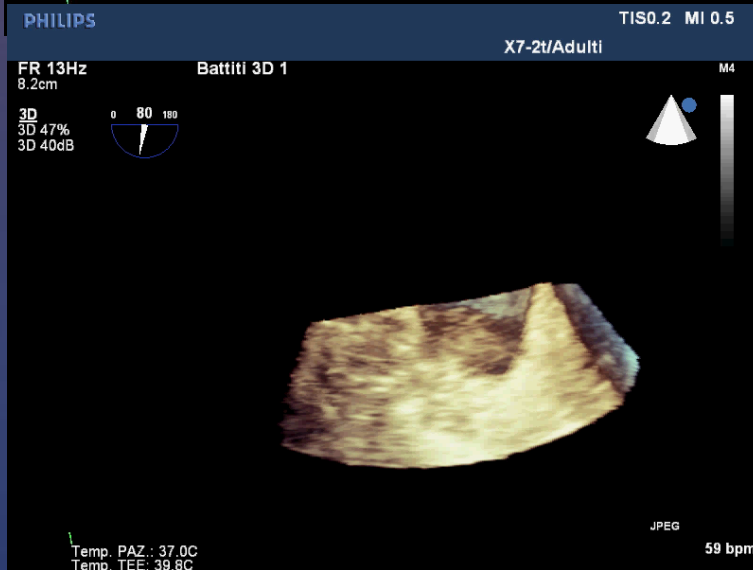
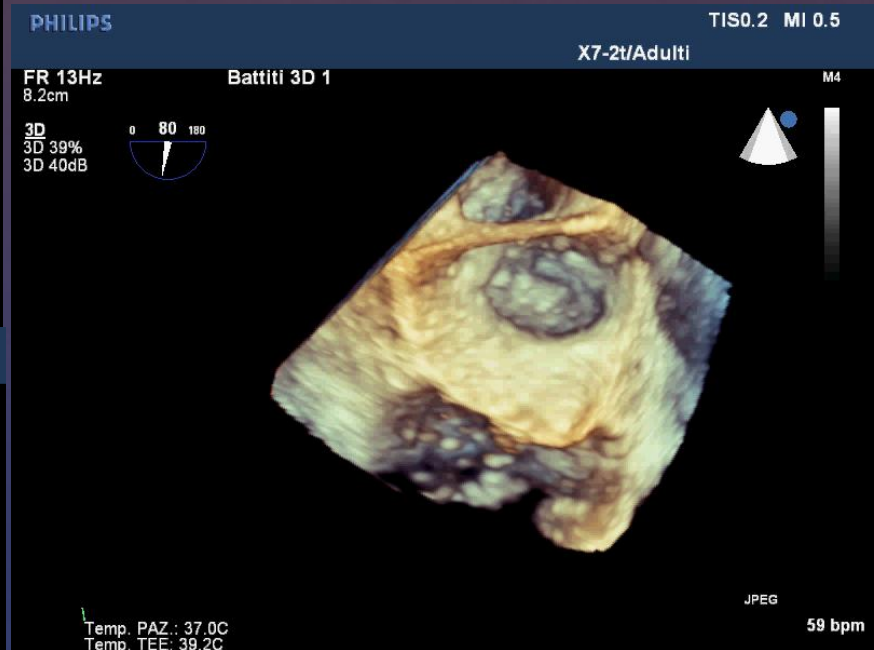
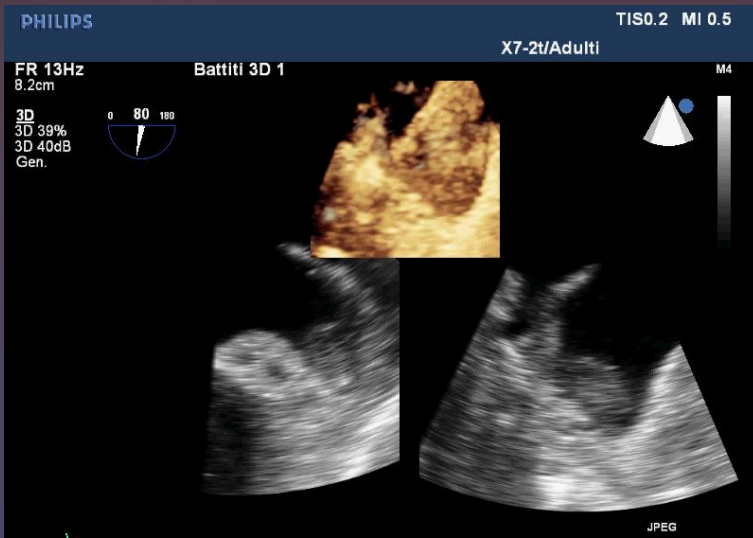
SM TEE 3D





SM REUMATICA TEE 3D





SM + TROMBOSI AURICOLA TEE 3D



CONTATTARE
CENTRO
RIFERIMENTO
INVIARE CD/DVD

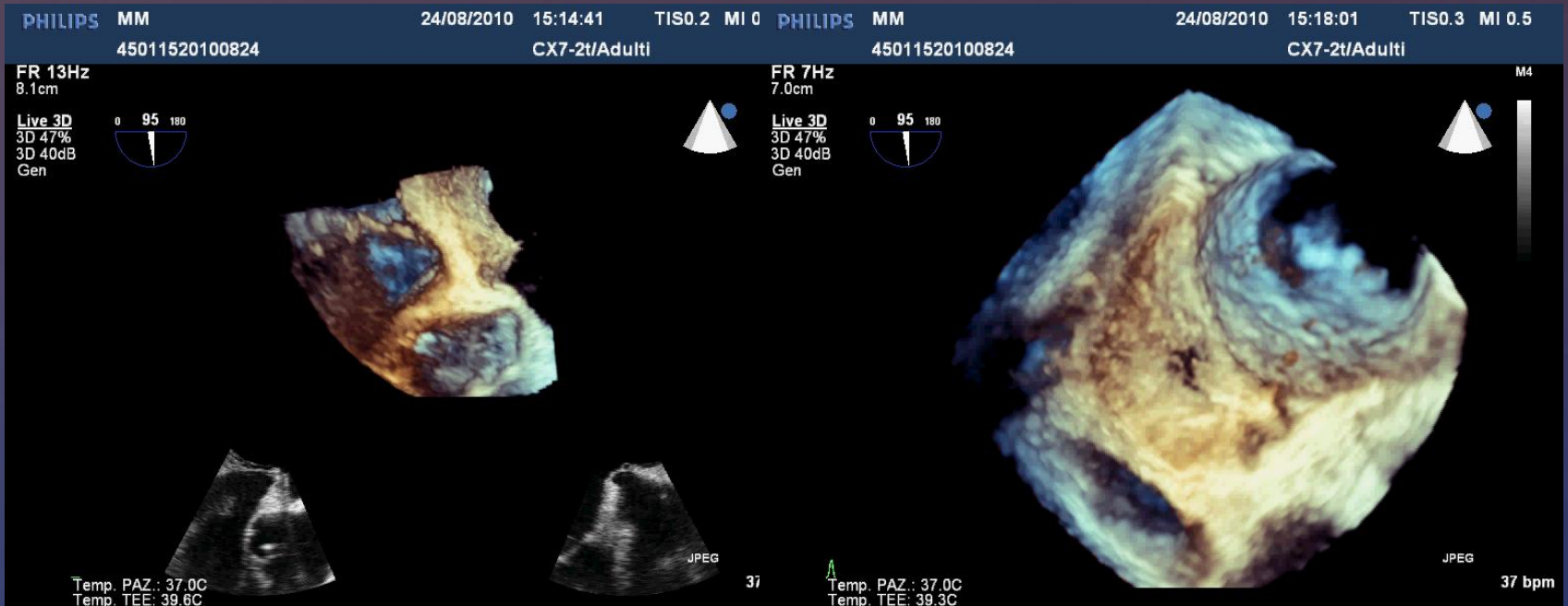
Table 1. Assessment of MV Anatomy According to the Wilkins Score

Grade	Mobility	Thickening	Calcification	Subvalvular Thickening
1	Highly mobile valve with only leaflet tips restricted	Leaflets near normal in thickness (4–5 mm)	A single area of increased echo brightness	Minimal thickening just below the mitral leaflets
2	Leaflet mid and base portions have normal mobility	Mid-leaflets normal, considerable thickening of margins (5–8 mm)	Scattered areas of brightness confined to leaflet margins	Thickening of chordal structures extending to one-third of the chordal length
3	Valve continues to move forward in diastole, mainly from the base	Thickening extending through the entire leaflet (5–8 mm)	Brightness extending into the mid portions of the leaflets	Thickening extended to distal third of the chords
4	No or minimal forward movement of the leaflets in diastole	Considerable thickening of all leaflet tissue (>8–10 mm)	Extensive brightness throughout much of the leaflet tissue	Extensive thickening and shortening of all chordal structures extending down to the papillary muscles

The total Wilkins score (3) is the sum of the 4 items and ranges between 4 and 16.

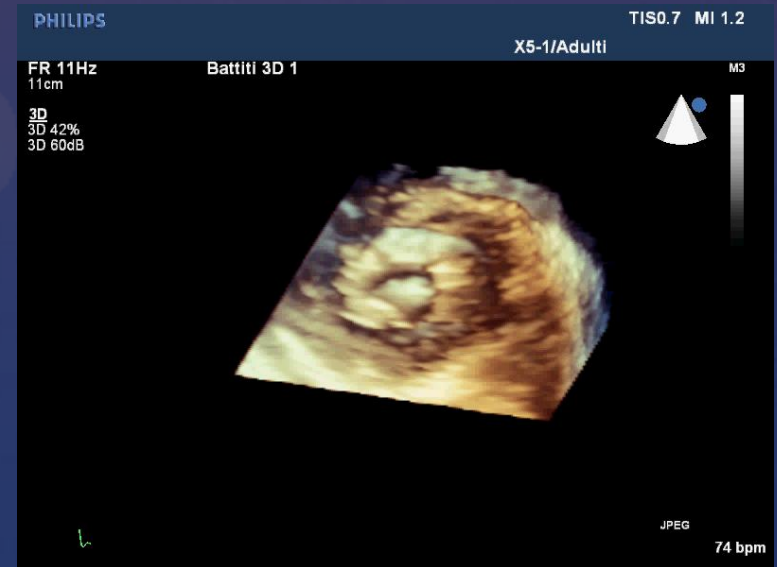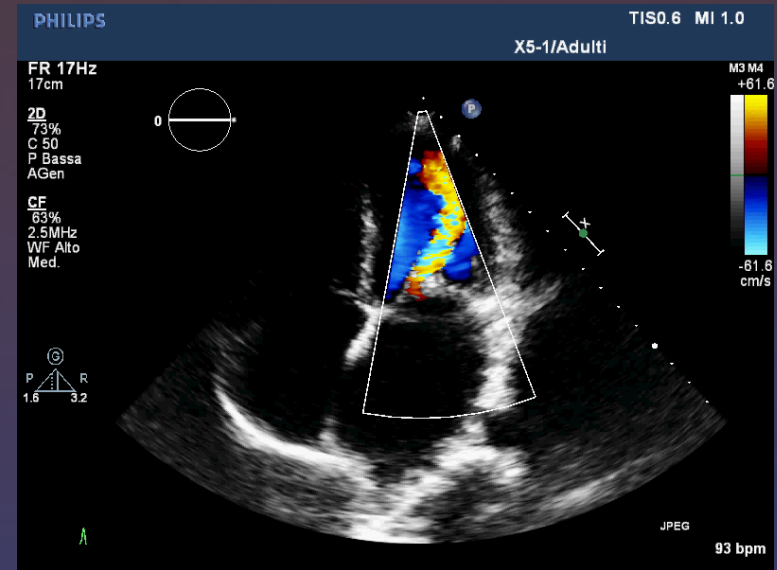
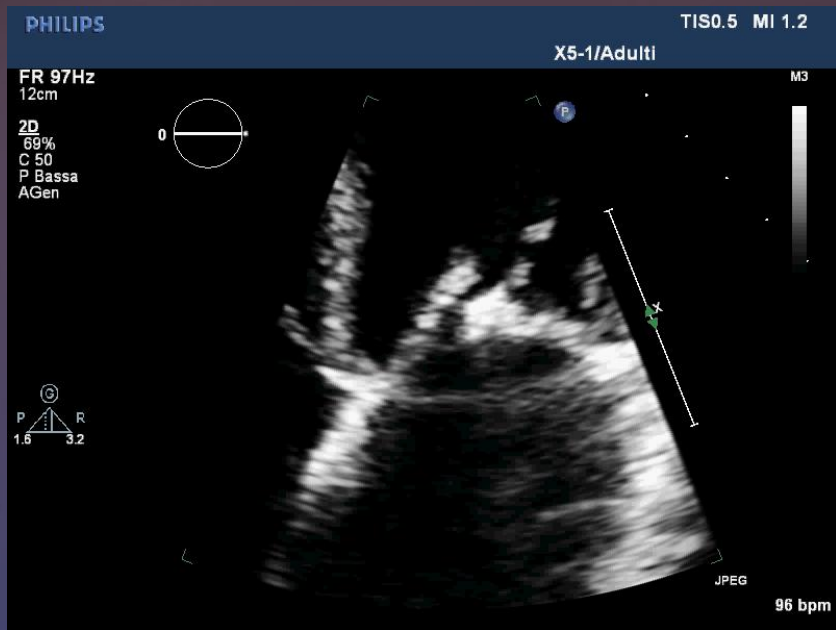
VALVULOPLASTICA PERCUTANEA





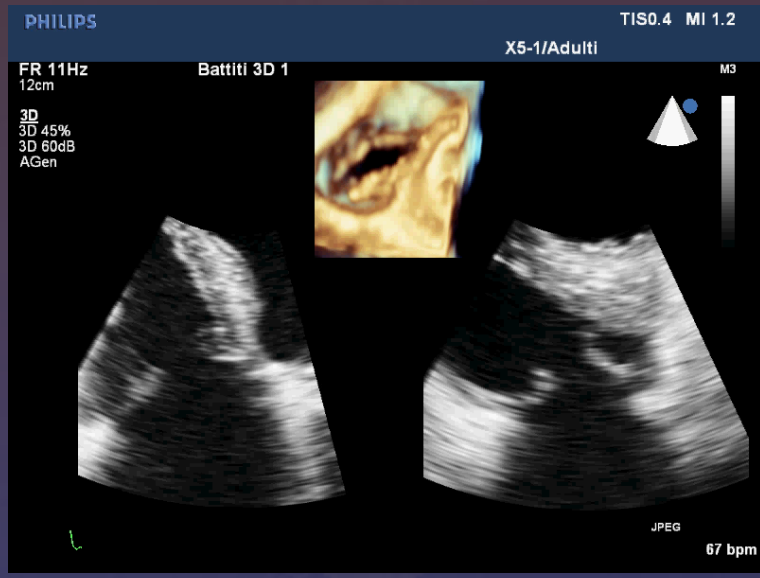
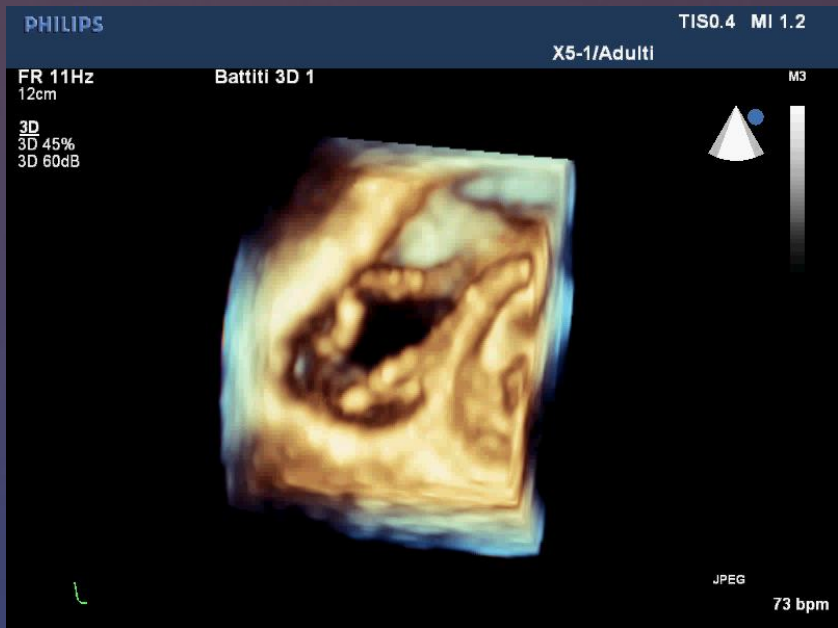
PUNTURA TRANSETTALE: ECO TEE 3D



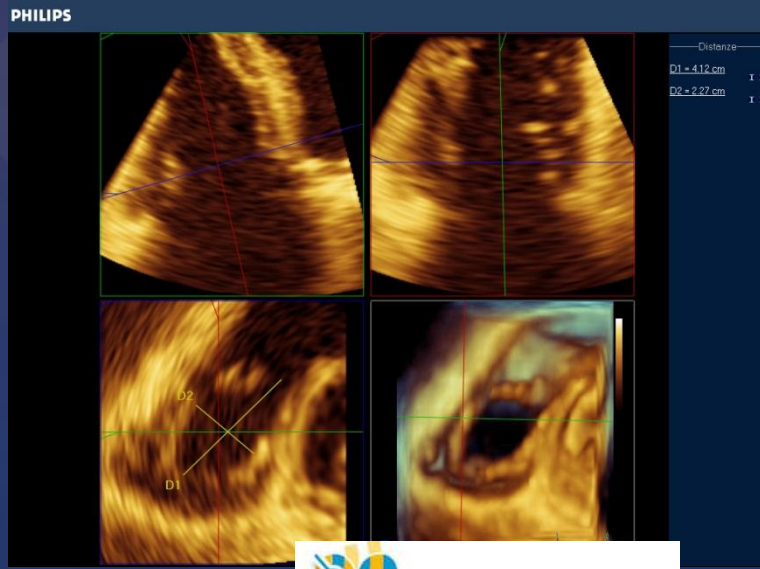


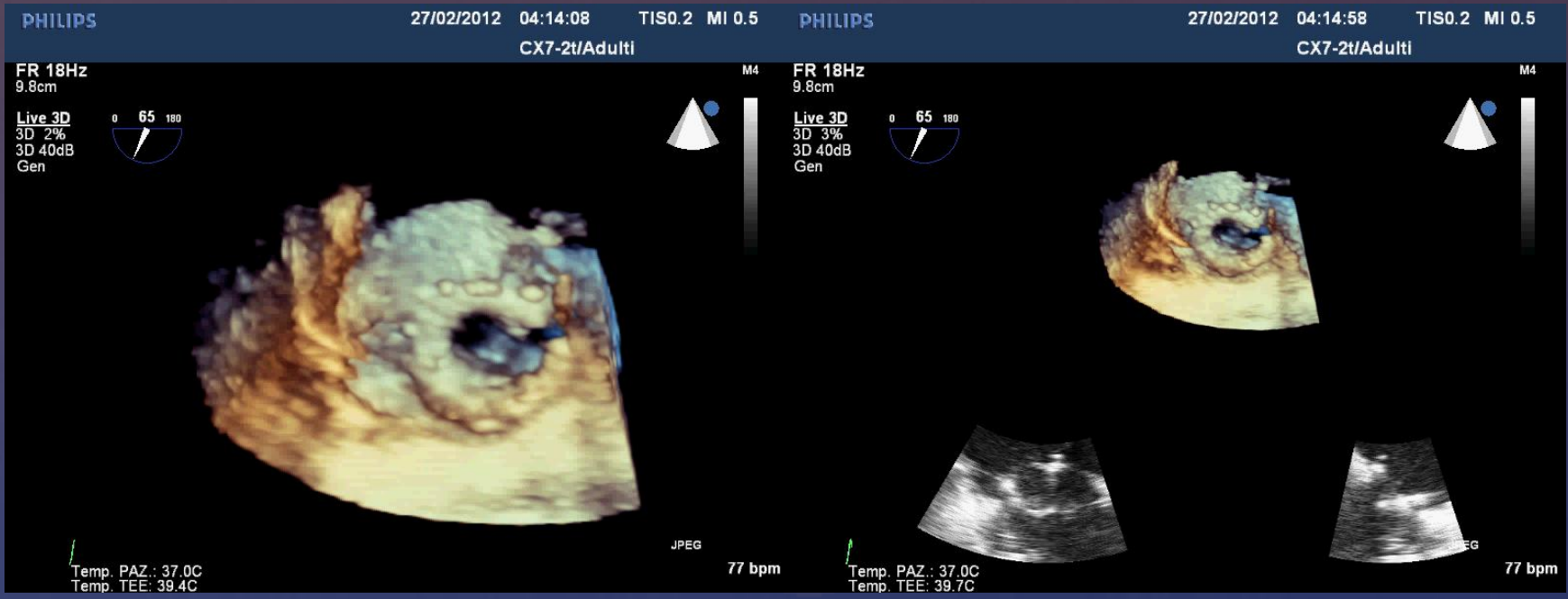
SM 9 ANNI DOPO VALVULOPLASTICA





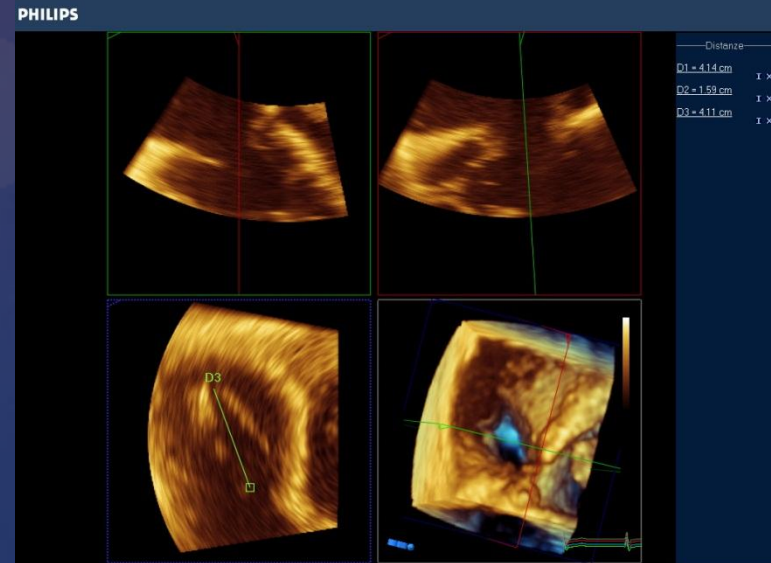
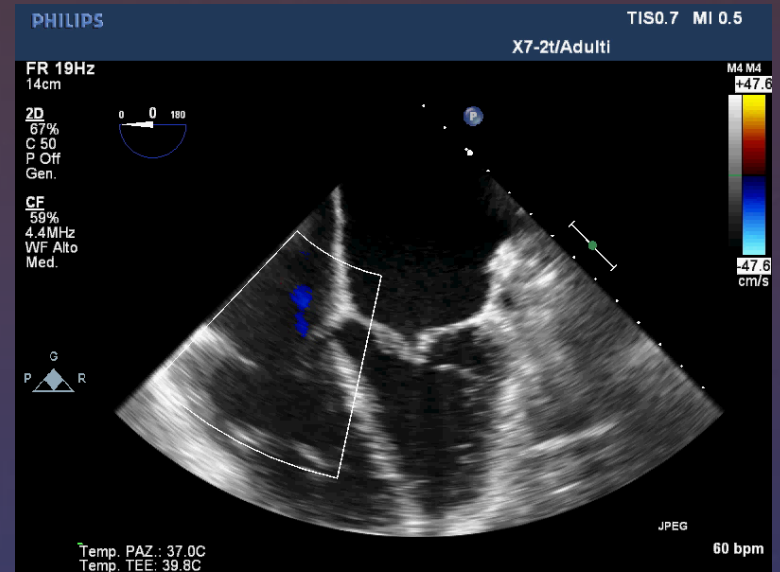
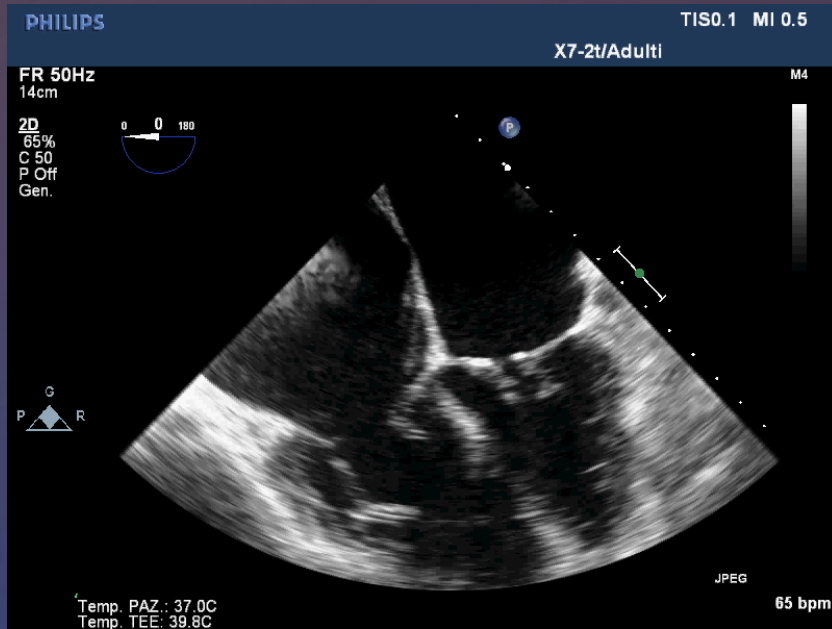
VALV TRIC TTE 3D





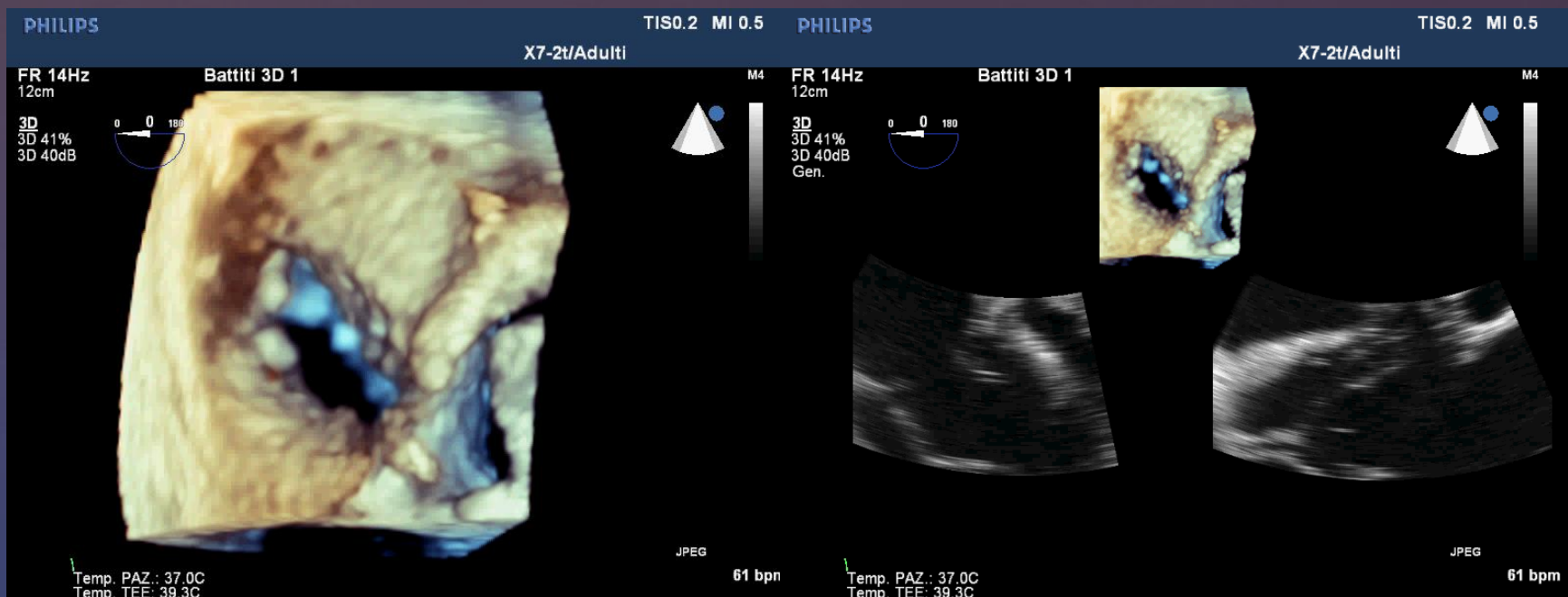
3D TTE ANULOPLASTICA TRICUSPIDE





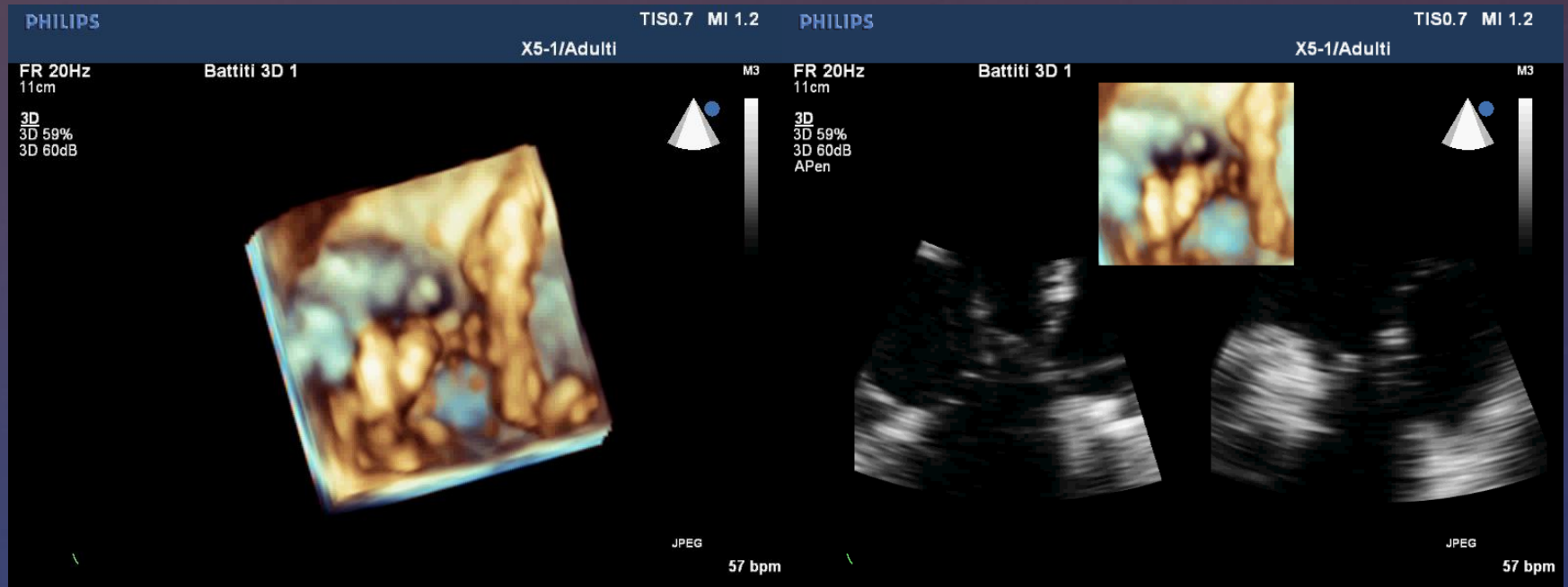
SM + ITR TEE 2D





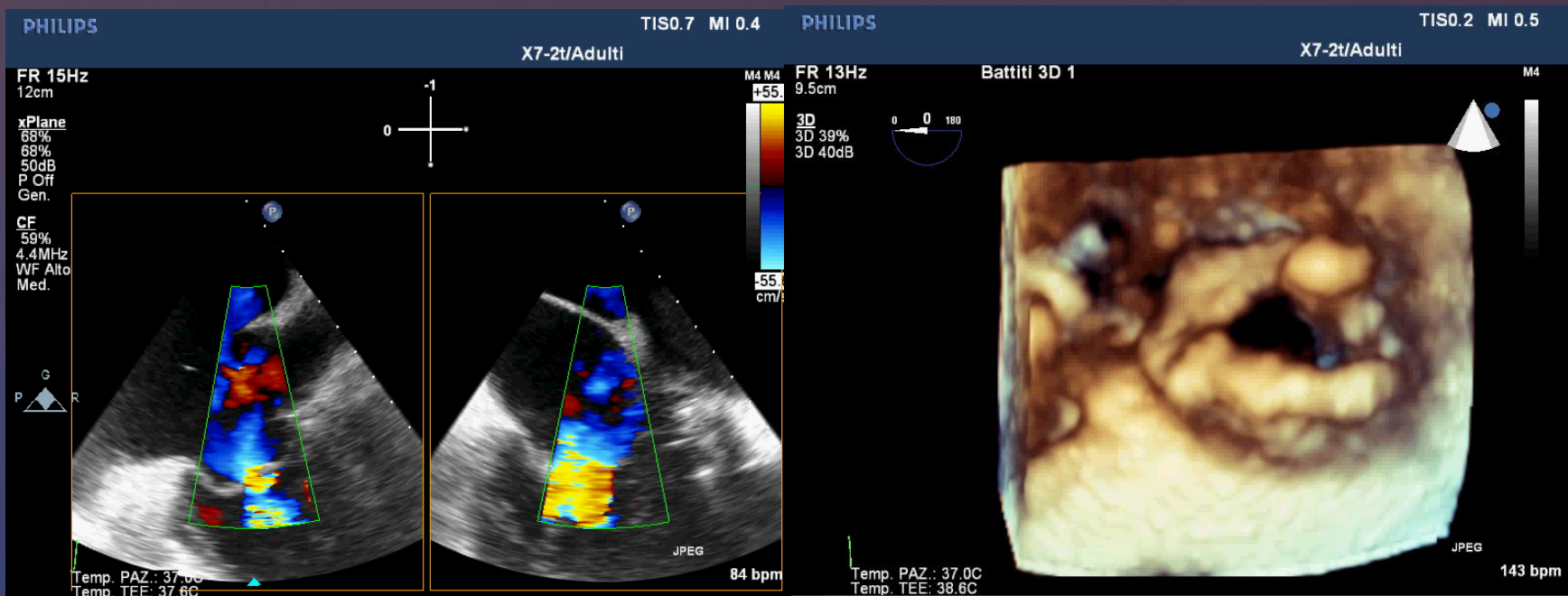
VALVOLA TRICUSPIDE TEE 3D





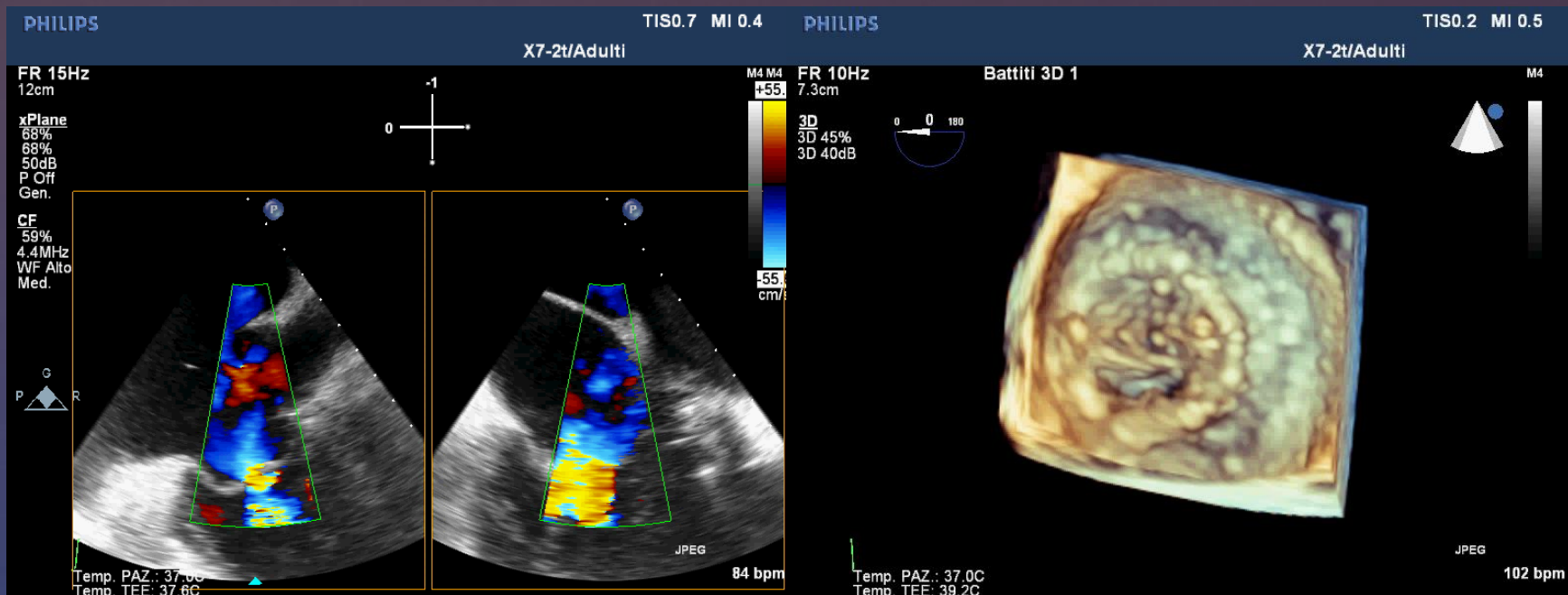
INTERFERENZA MOTILITA' DEI LEMBI DELLA VAL TRICUSPIDE DA PARTE CATETERE STIMOLATORE





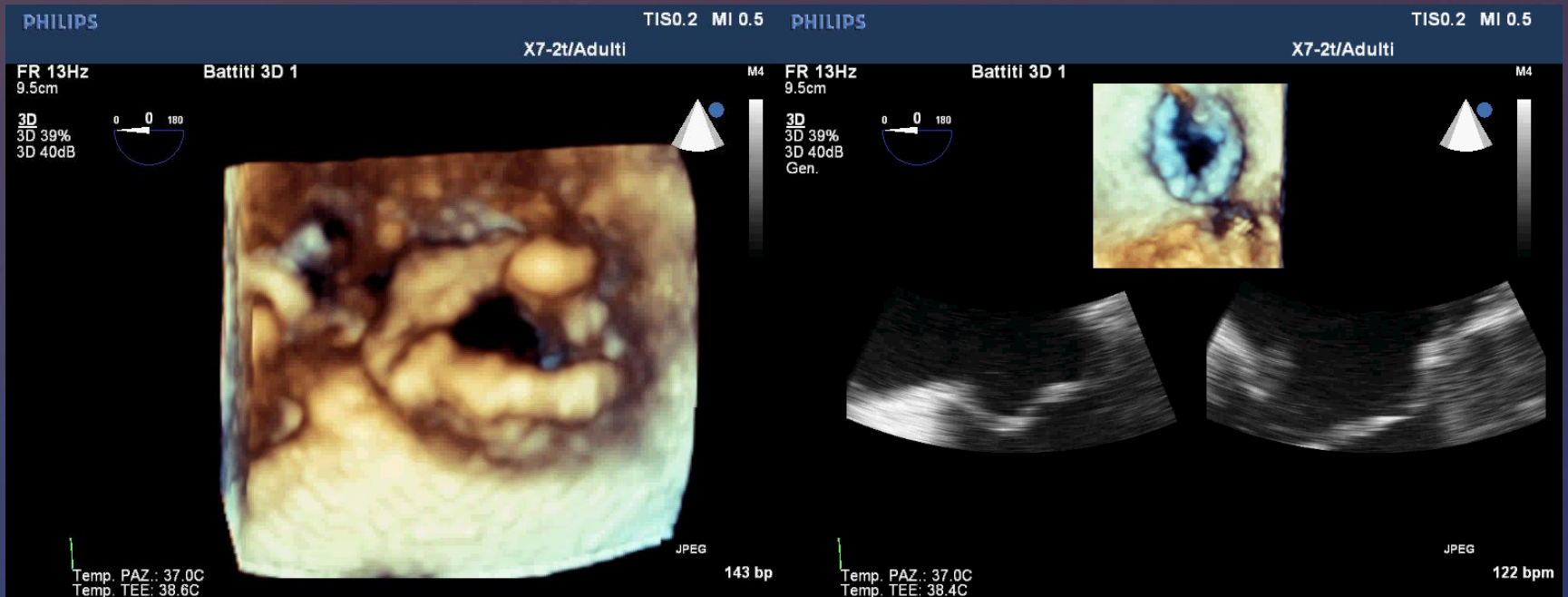
TEE 3D ITR - PM





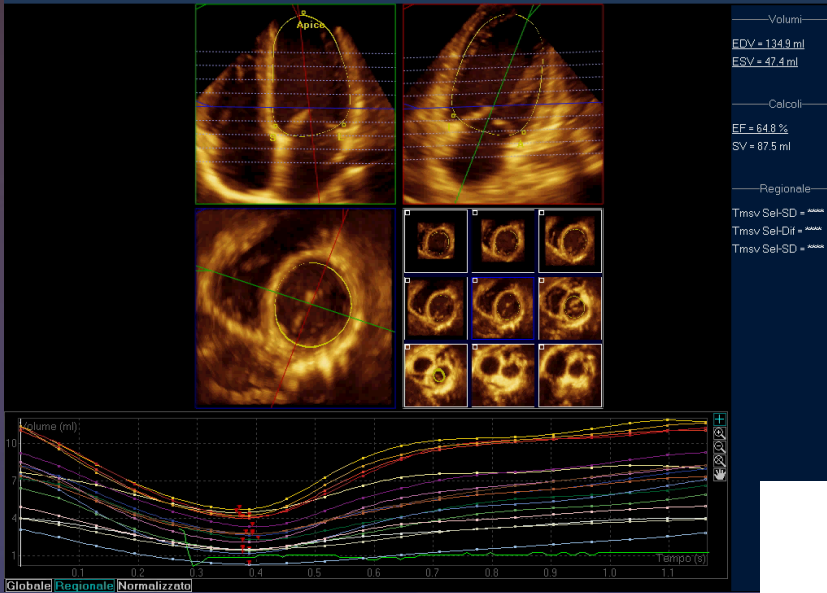
PROTESI MITRALICA MECCANICA ITR 3 + PM TEE 3D





TEE 3D VAL TRIC + PM





Echocardiographic Assessment of Right Ventricular Function

How to Account for Tricuspid Regurgitation and Pulmonary Hypertension

Lee Fong Ling, MD, Thomas H. Marwick, MD, PhD, MPH

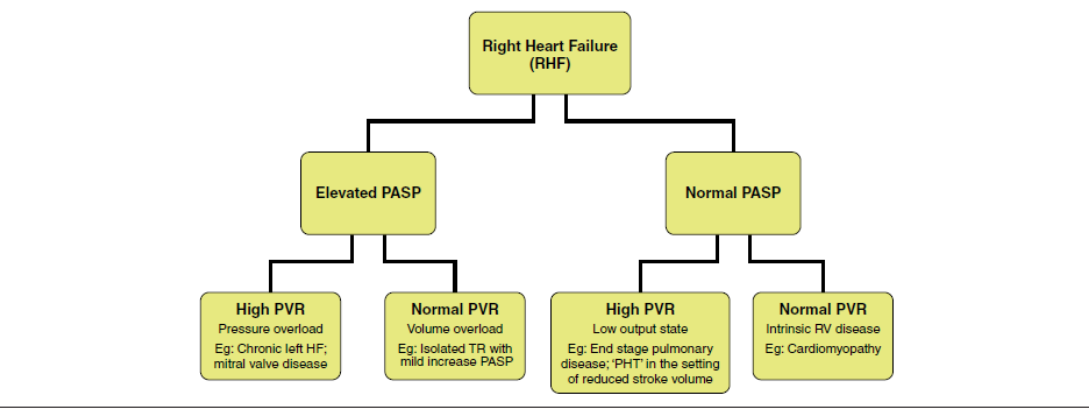
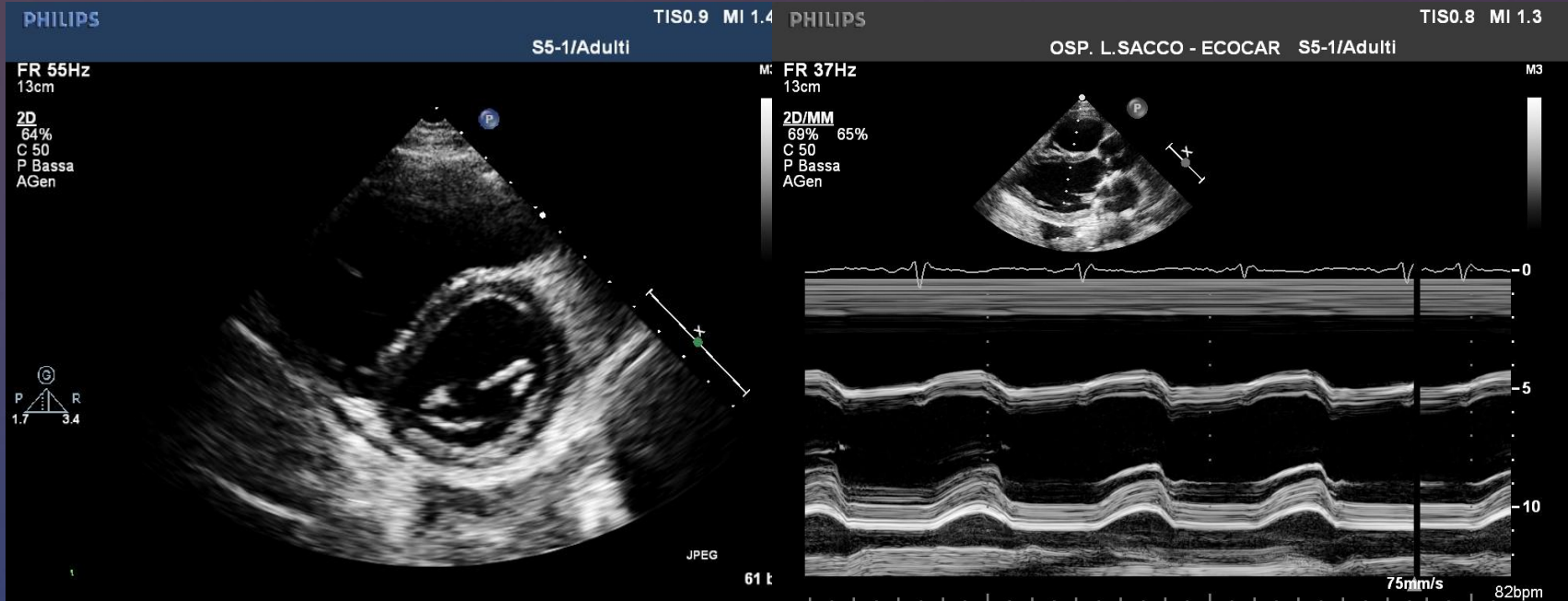


Figure 1. Diagnostic Algorithm for Classification of RV Function

First, adjudicate the presence of increased right ventricular (RV) afterload (consider using pulmonary vascular resistance [PVR] if RV function is decreased). RV impairment may be confirmed or refuted using a combination of techniques. HF = heart failure; PASP = pulmonary artery systolic pressure; PHT = pulmonary hypertension; TR = tricuspid regurgitation.

VALUTAZIONE VD





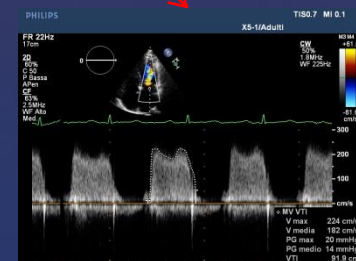
PAZIENTE IN TIPO
POST INTERVENTO

VALUTAZIONE VD



INDICAZIONE OPERATORIA SUGGERIMENTI

- 1) Indicazione posta cardiocirurgo e cardioanestesista
- 2) Discussione collegiale (se possibile) marcare caratteristiche del caso
- 3) Esaminare videoclip eco (rivoluzione culturale!)
- 4) Segnalare al paziente rischio intervento





CAMPIONATO CARDIOLOGI 2011



ROMA 27-30 September 2012
XXXII WORLD CONGRESS
OF SPORTS MEDICINE



CAMPIONATO
CARDIOLOGI 2012

Podisti.Net



Cialfi Caterina

CAPITANO U18
UNENDO
YAMAMAY



photo by Stefano "Peo" Moroni