

Le tecniche complesse di plastica dell'apparato valvolare mitralico

Lucia Torracca

Cardiologia

Ospedali Riuniti Ancona



Milano 5-7-Maggio 2014

VII CONGRESSO DI **ECOCARDIOCHIRURGIA**

Le lesioni complesse

- Prolasso/flail del lembo anteriore
- Prolasso/flail **esteso** (LPM/LAM)
- Prolasso bilembo
- Barlow
- La patologia reumatica
- L'endocardite

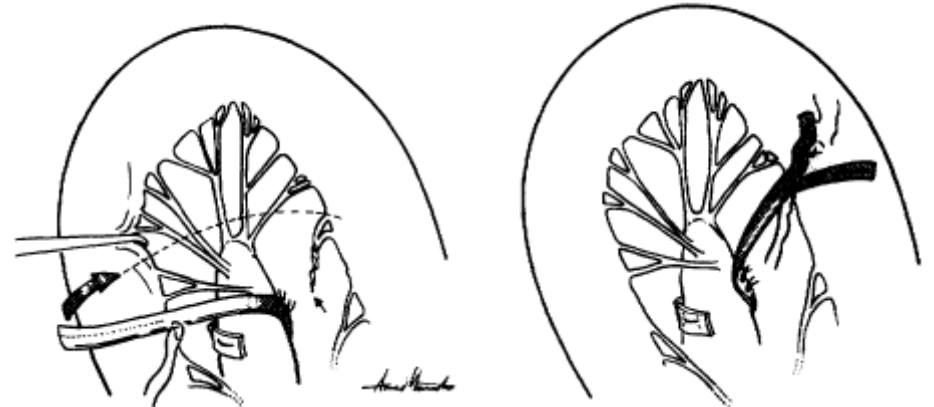
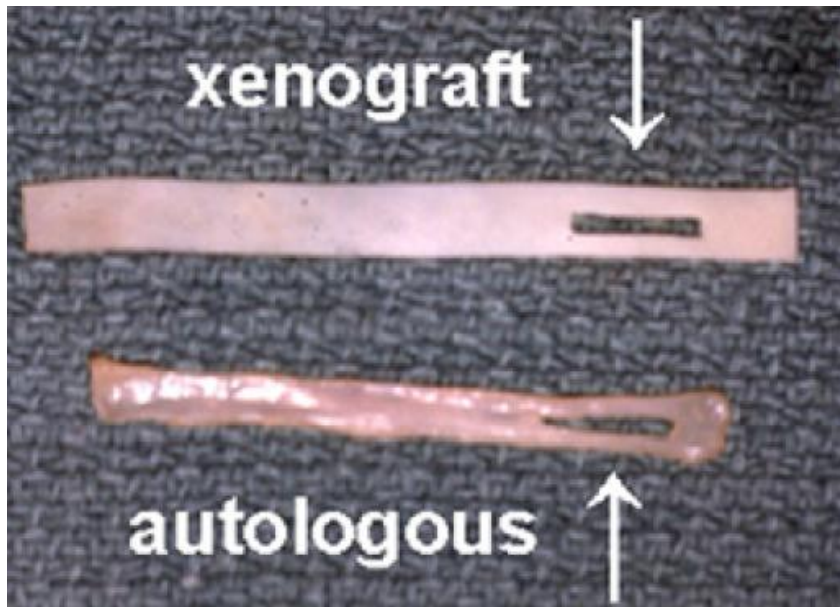
Le corde artificiali



Storia

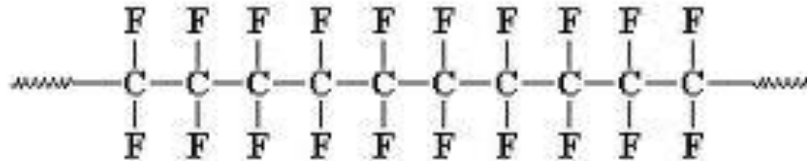
Vennero utilizzati numerosi materiali per sostituire le corde tendinee:

- seta, nylon, mersilene, polipropilene
- pericardio trattato o non con glutaraldeide



Storia

PTFE: politetrafluoroetilene



Gore tex: politetrafluoroetilene espanso (ePTFE)

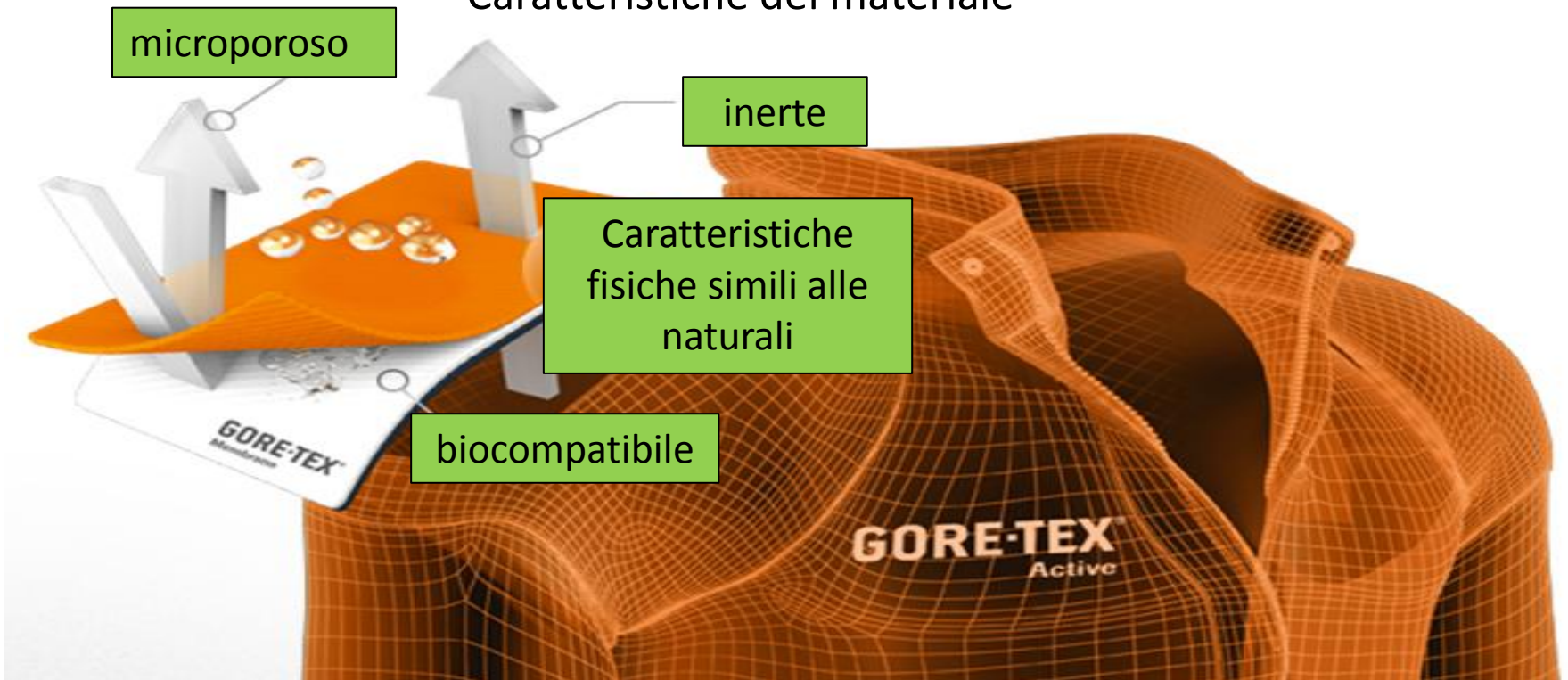
Caratteristiche del materiale

microporoso

inerte

Caratteristiche
fisiche simili alle
naturali

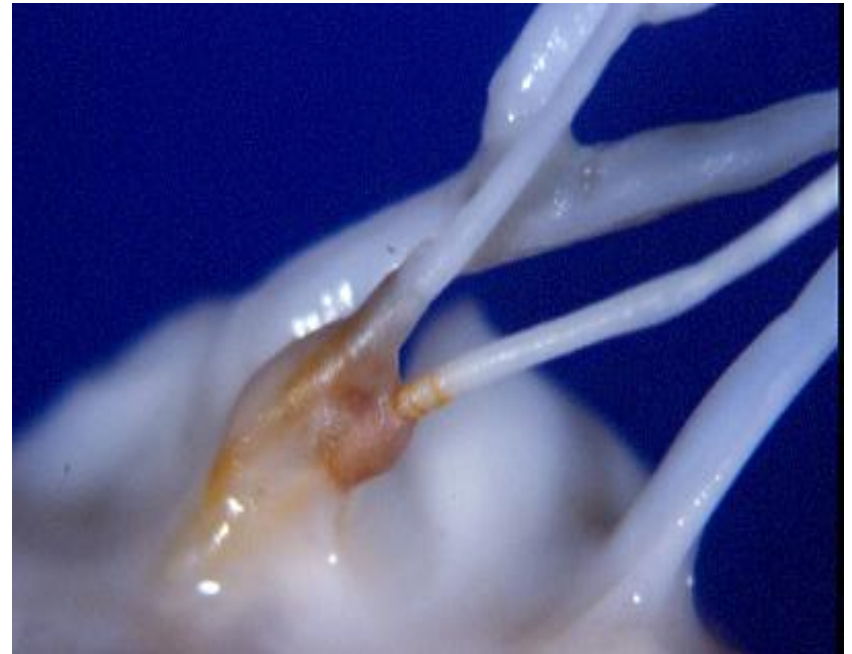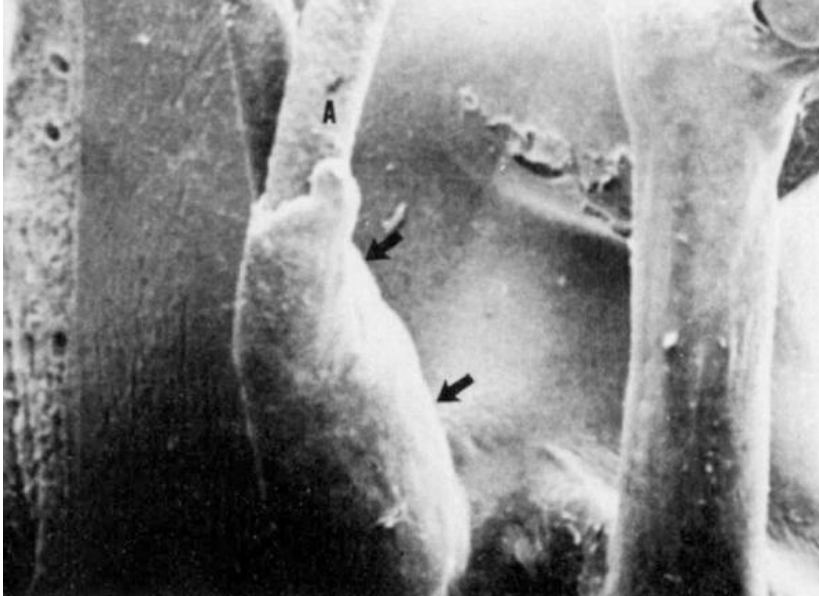biocompatibile



Storia

1986 Vetter → utilizzo di Goretex CV-2. Ottima endotelizzazione, ma scarsa flessibilità.

1990 Zussa → Goretex CV-5.

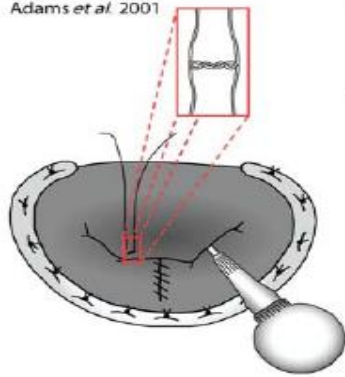


Tecniche d'impianto

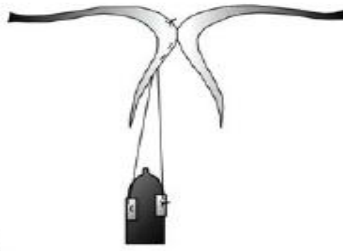La riparazione mitralica con impianto di corde tendinee ha due fasi critiche che possono determinare una failure della plastica

1. Determinazione della lunghezza delle neo corde
2. Fissazione

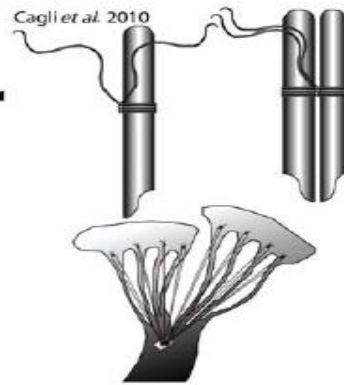
Adams *et al.* 2001



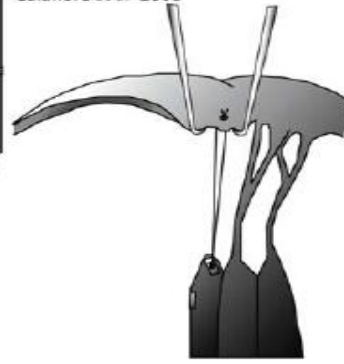
Brunsting *et al.* 2009



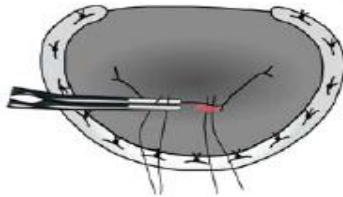
Cagli *et al.* 2010



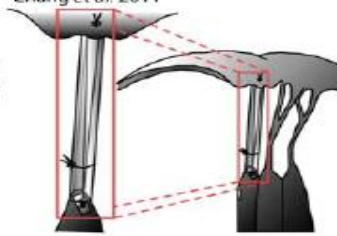Calafiore *et al.* 2008



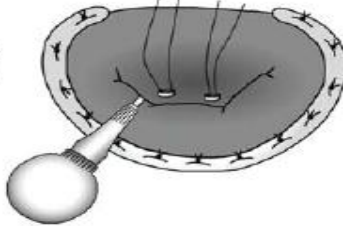
Chan *et al.* 2008



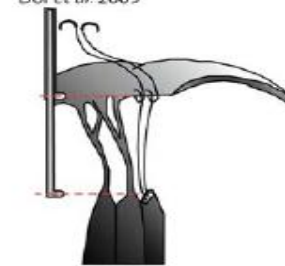Chang *et al.* 2011



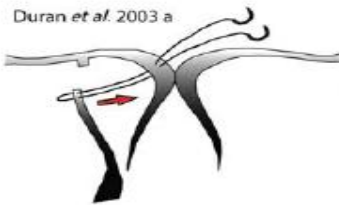Chocron *et al.* 2007



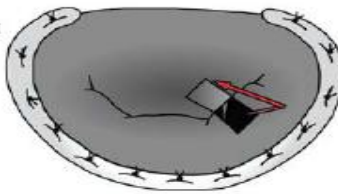
Doi *et al.* 2009



Duran *et al.* 2003 a



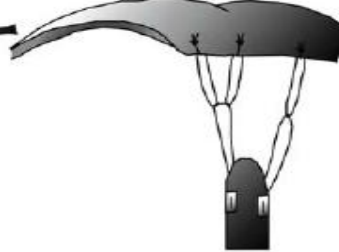Duran *et al.* 2003 b



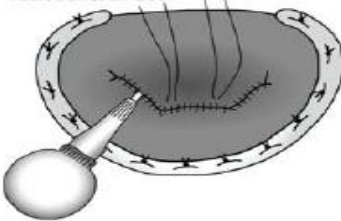
Duran *et al.* 2003 c



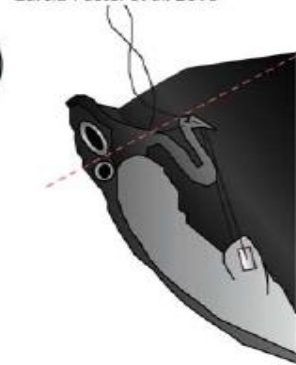Duran *et al.* 2003 d



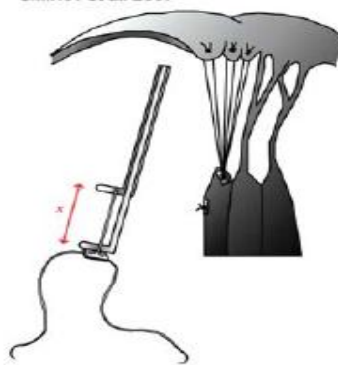Fattouch *et al.* 2007



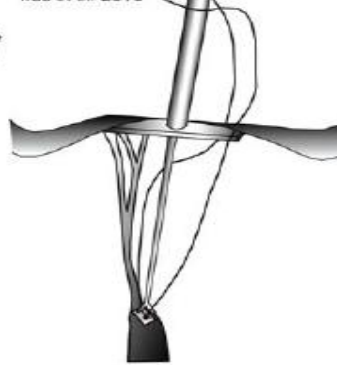
Garcia-Fuster *et al.* 2010



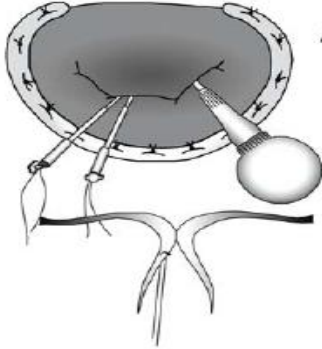
Gillinov *et al.* 2007



Iida *et al.* 2010



Kasegawa *et al.* 1994



Maisano *et al.* 2011



Mandegar *et al.* 2007



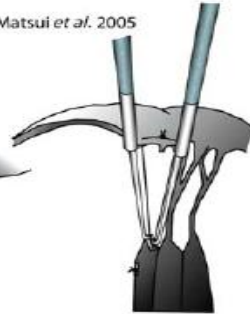Maselli *et al.* 2007



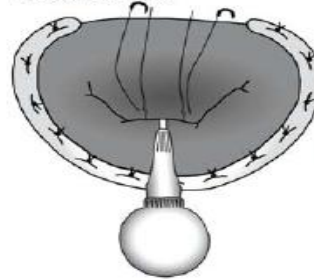
Maselli *et al.* 2010



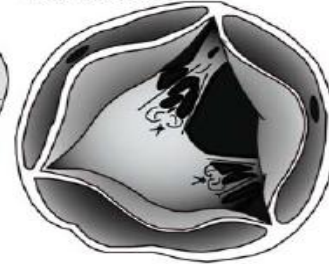Matsui *et al.* 2005



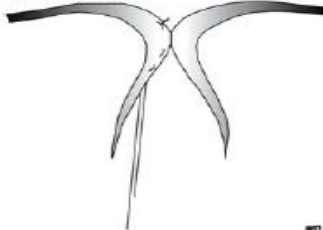Moorjani *et al.* 2009



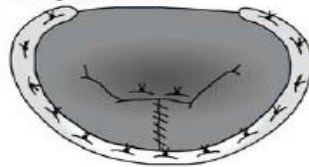
Pretre *et al.* 2006



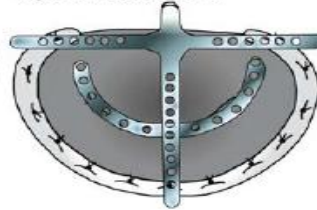
Rankin *et al.* 2006



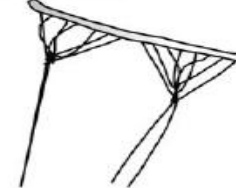
Rodriguez *et al.* 2008



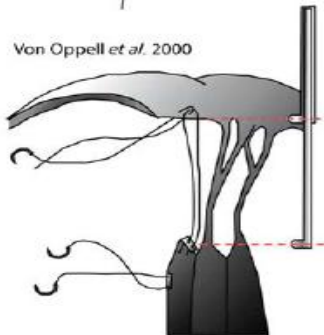
Ruyra-Baliarda *et al.* 2010



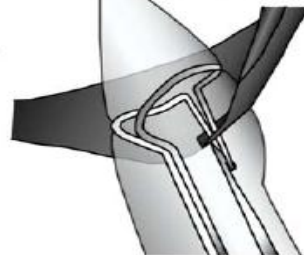
Scorsin *et al.* 2007



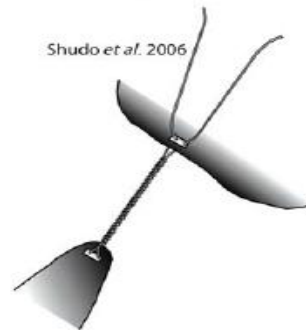Von Oppell *et al.* 2000



Seeburger *et al.* 2011



Shudo *et al.* 2006

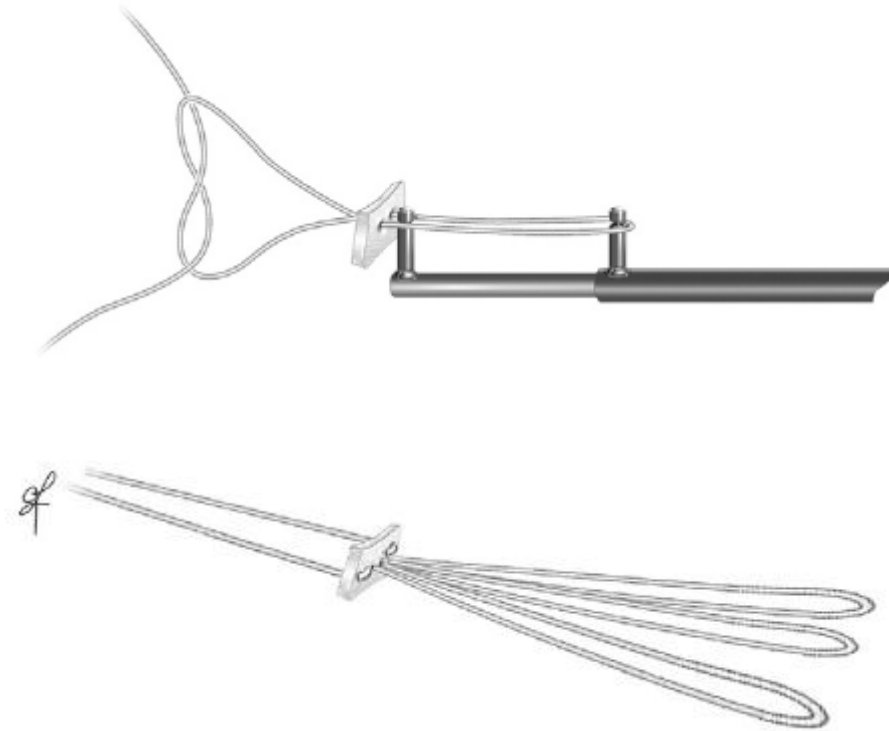
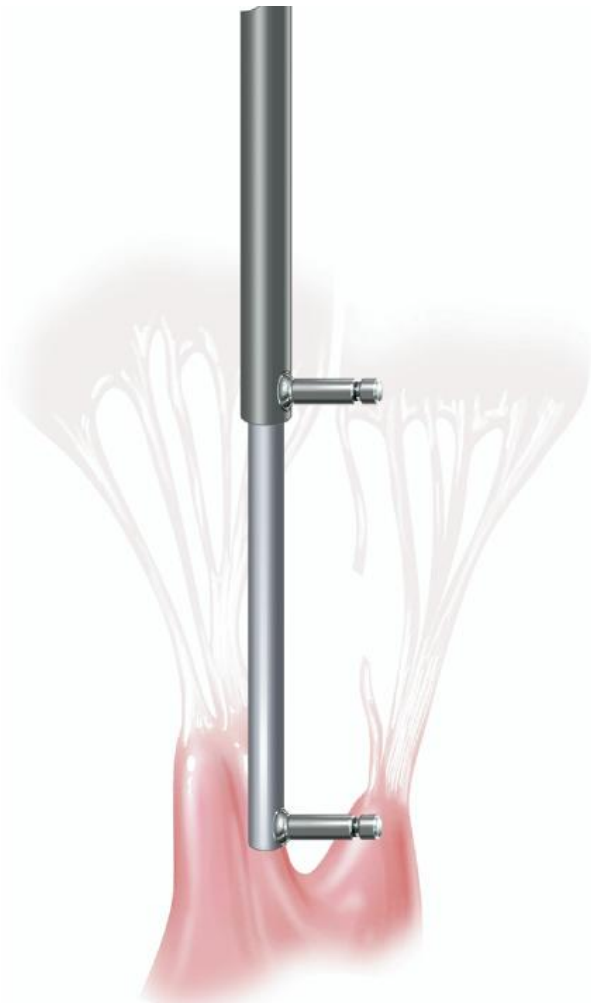

Smith *et al.* 2008



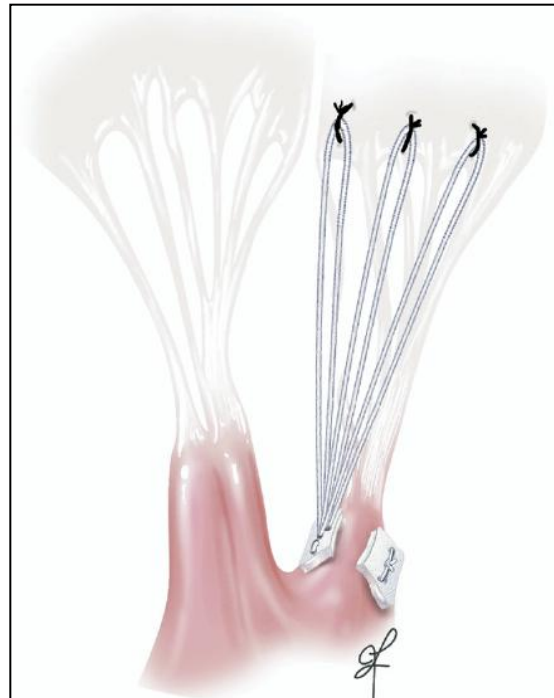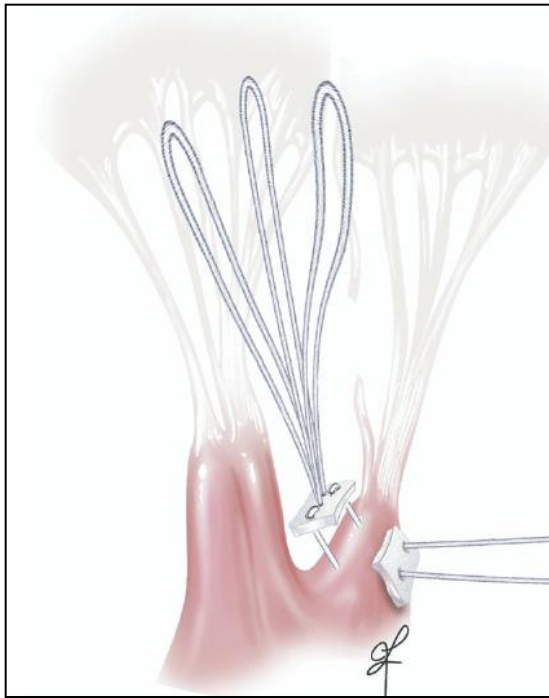
Tecniche d'impianto

Loops premisurate

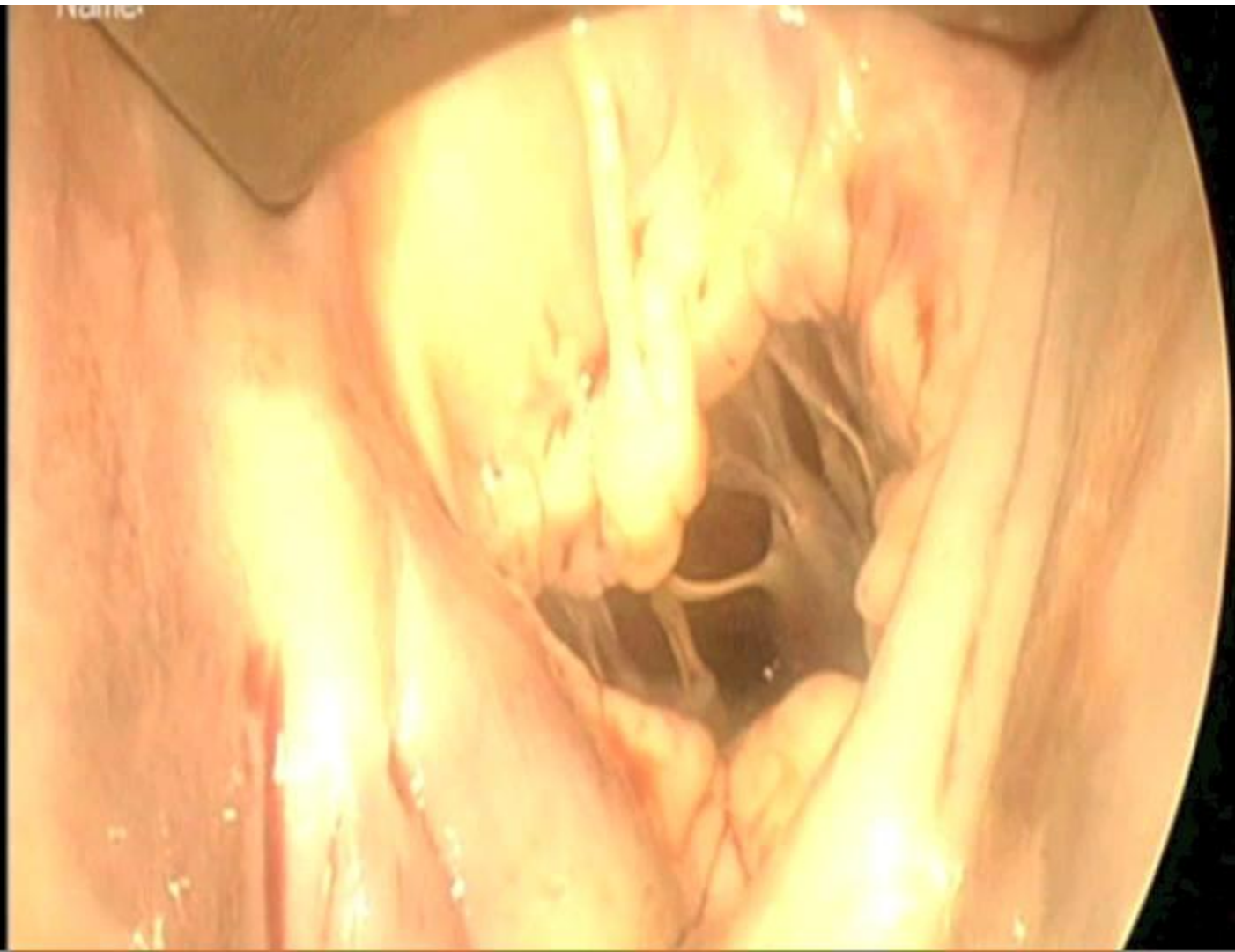


Tecniche d'impianto

Loops premisurate

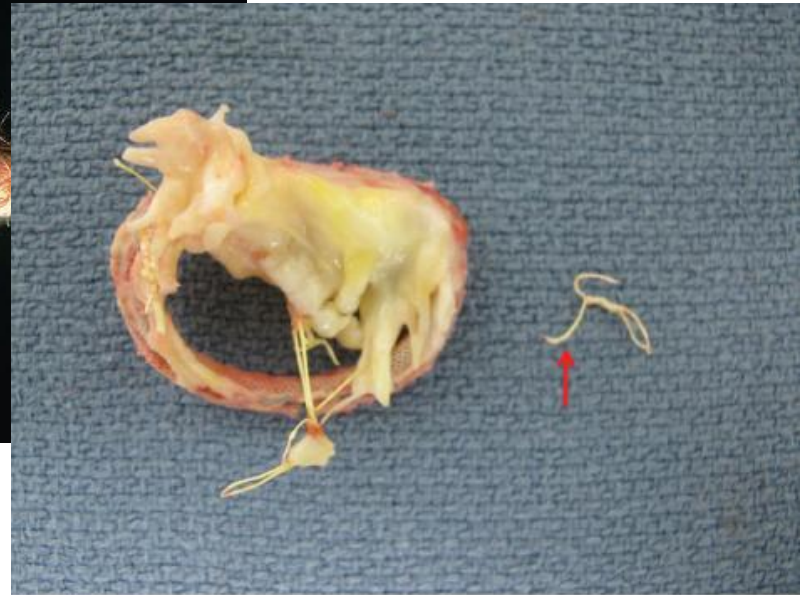
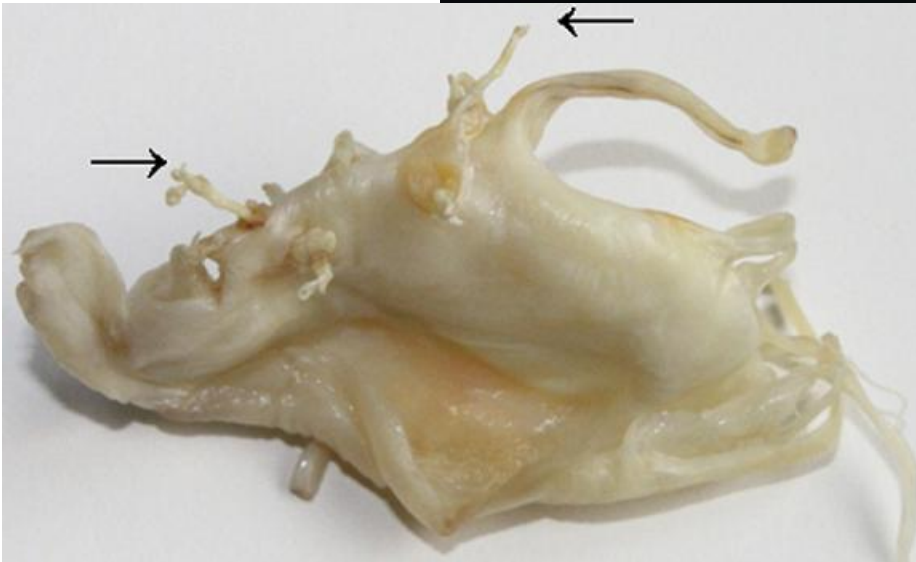

Von Oppell Ann Thorac Surg 2000

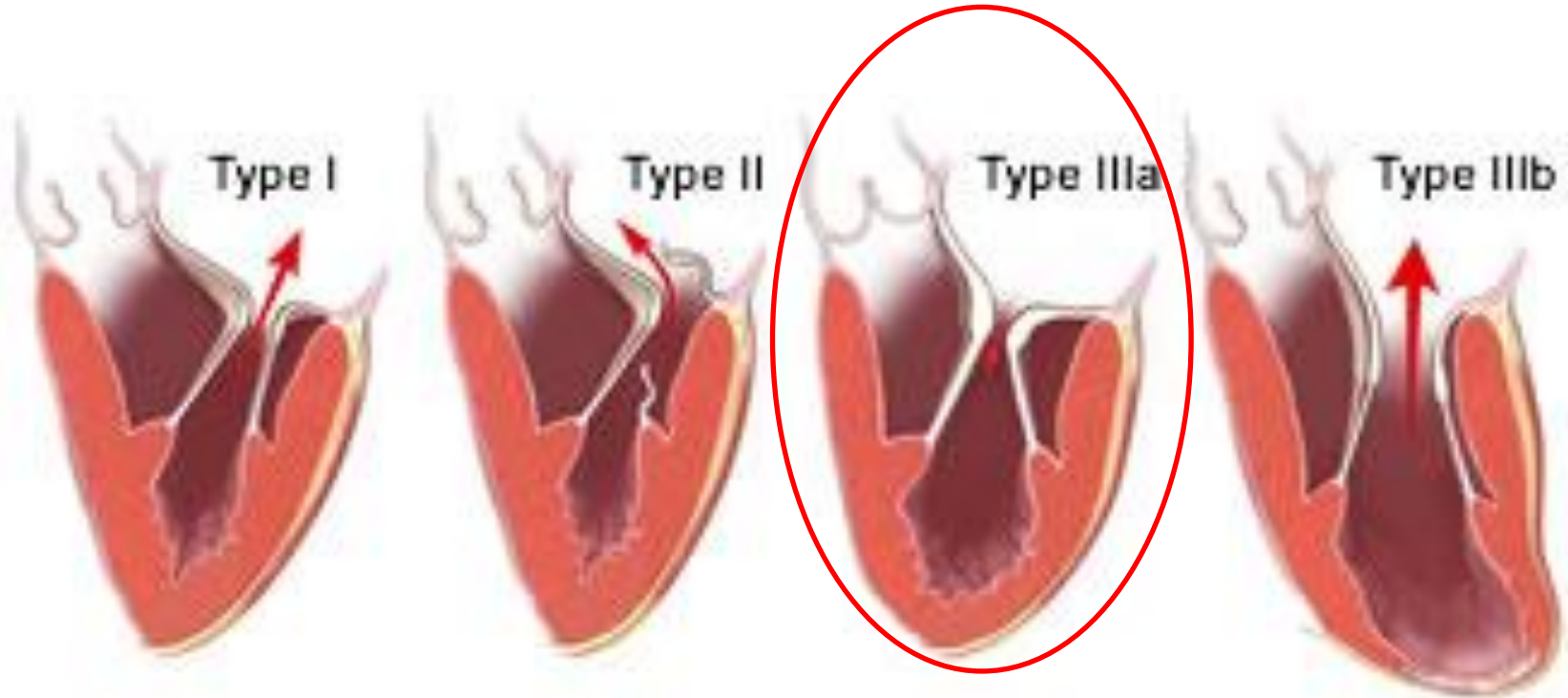


Patologia correlata alle neocorde

Sono stati descritti casi di rottura precoce e tardiva di neocorde dopo anni dall'impianto per calcificazione.



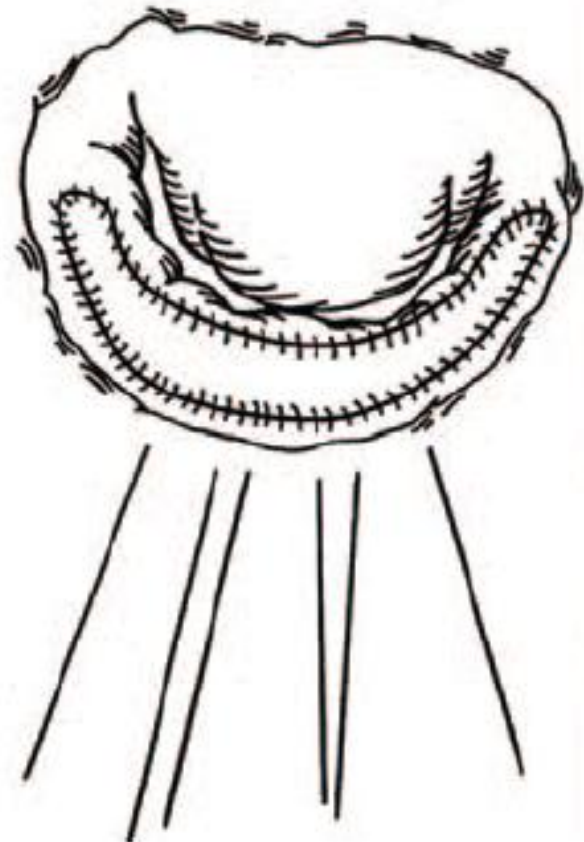

La patologia reumatica



Lesioni dominanti:

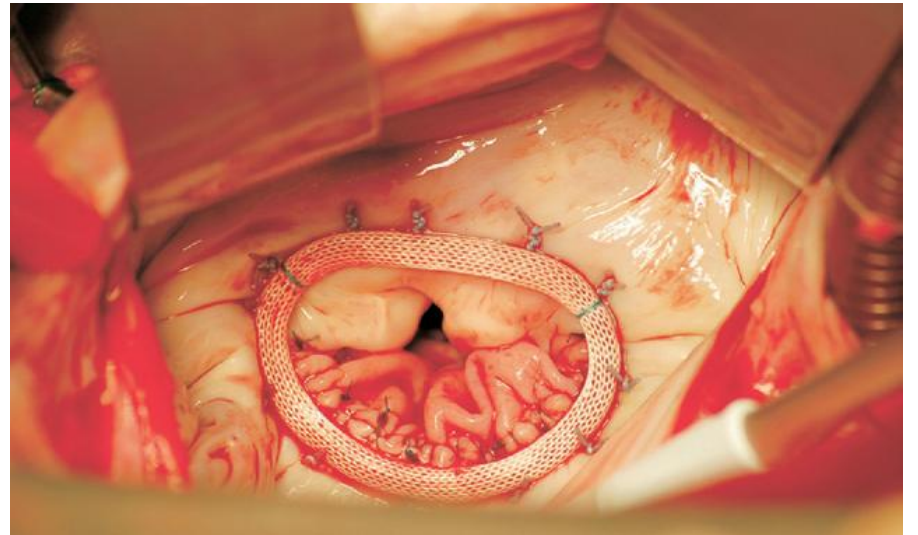
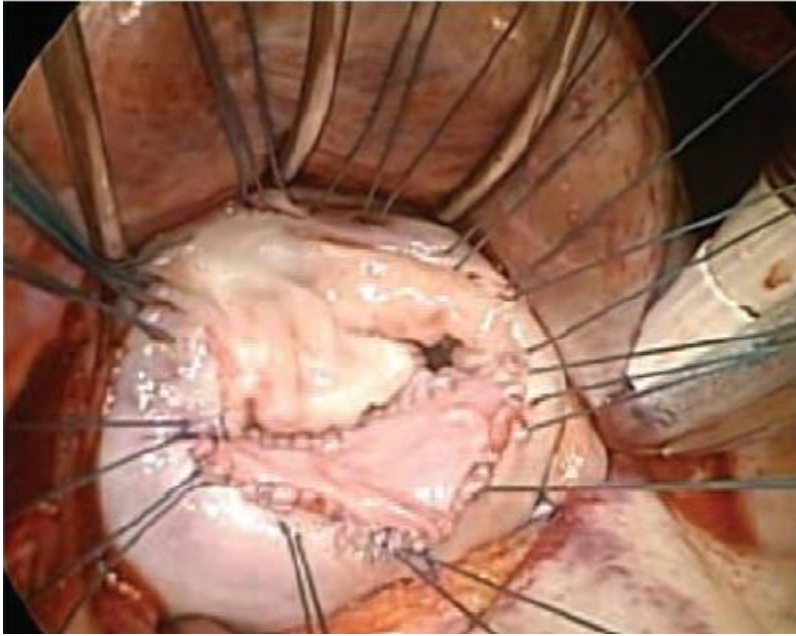
- Fibrosi e retrazione dei lembi
- Ispessimento e retrazione delle corde tendinee
- Prolasso o pseudo-prolasso

L'ampliamento dei lembi

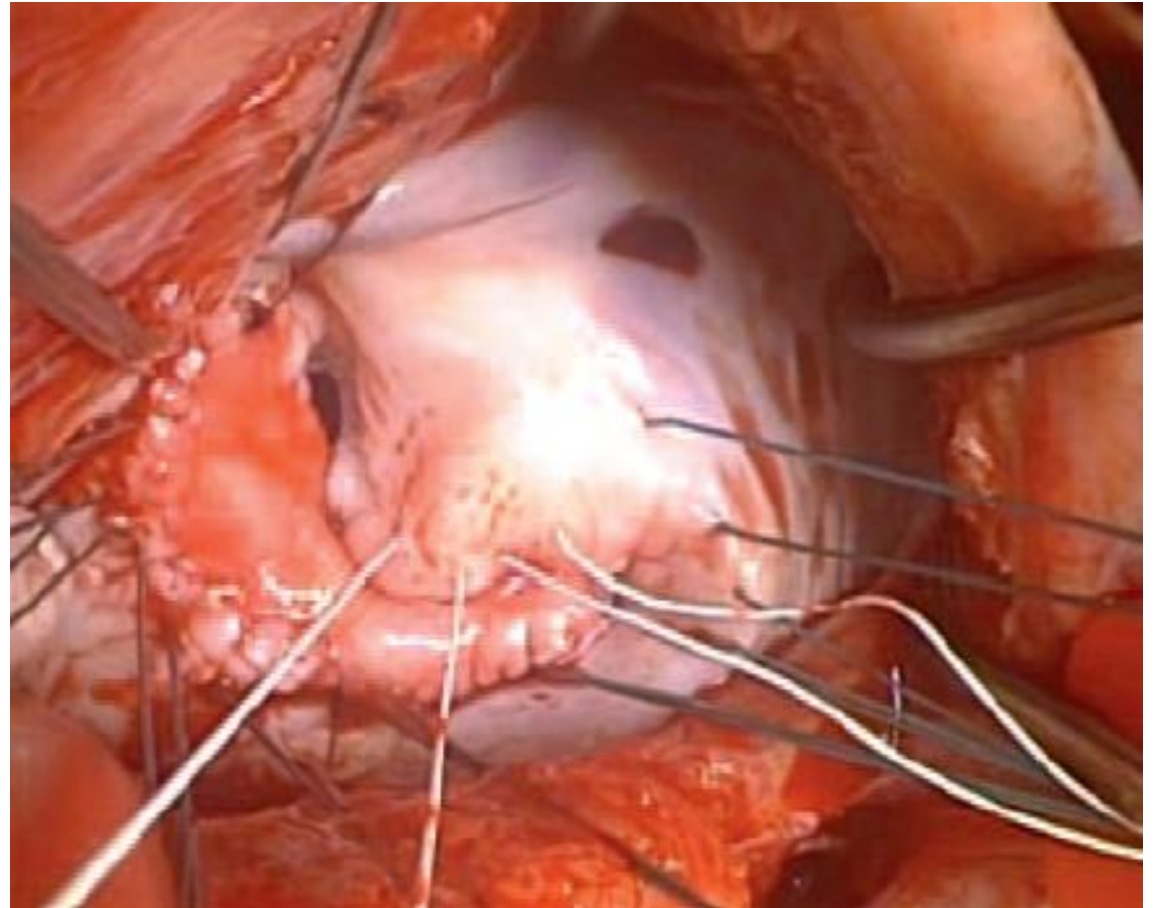
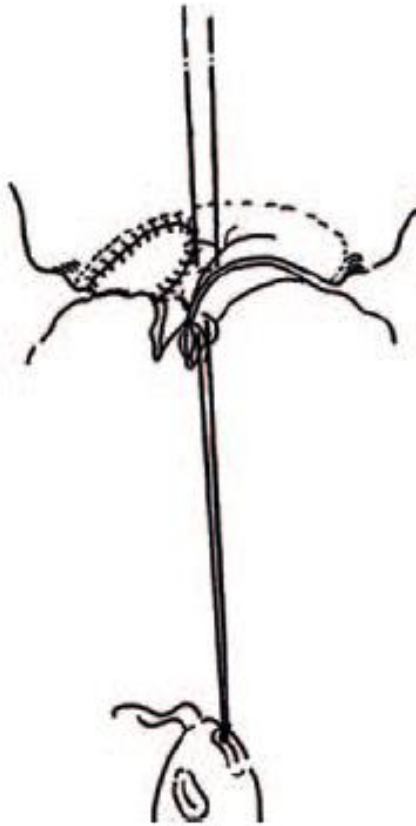


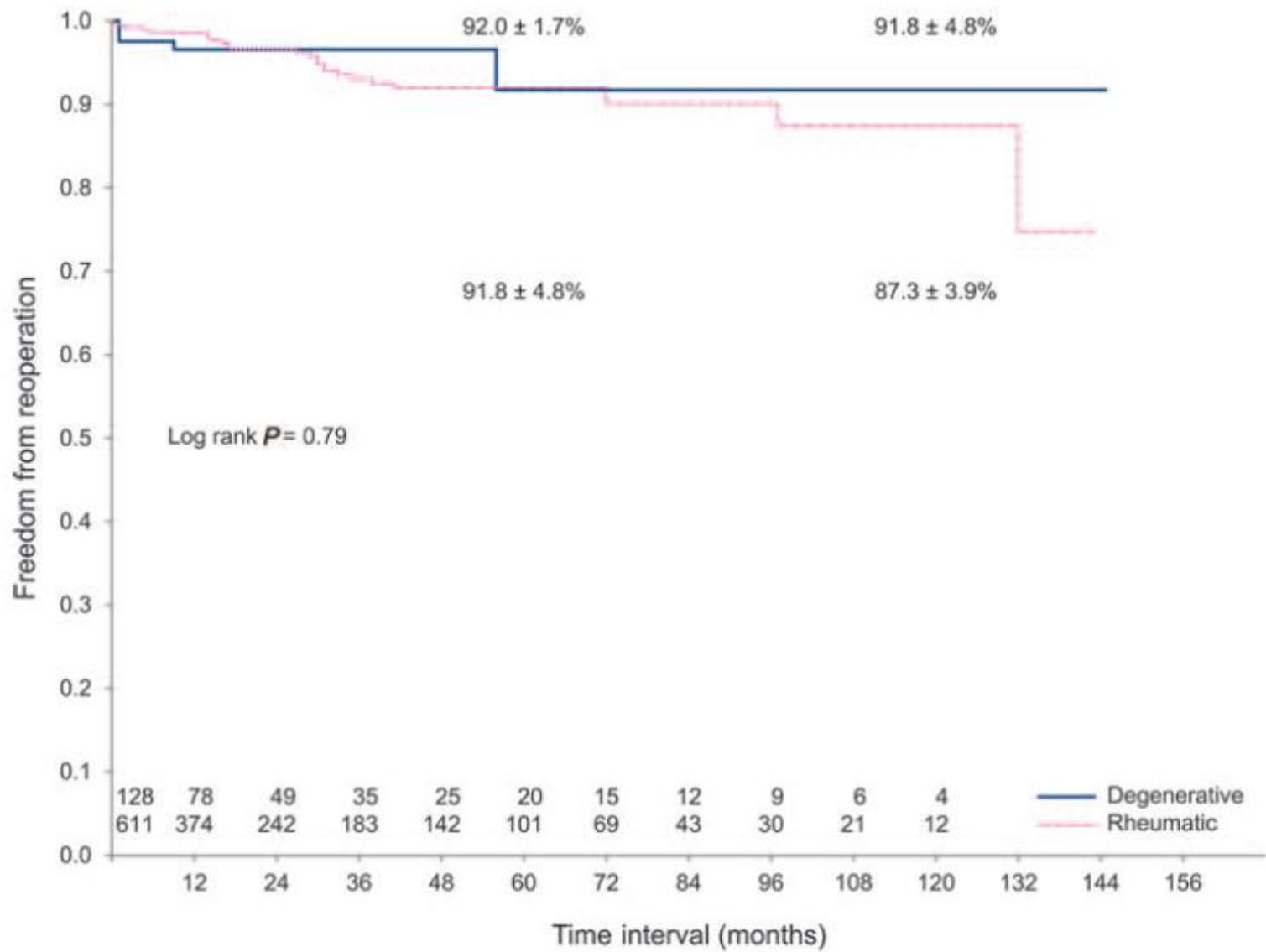
Ampliamento del lembo posteriore

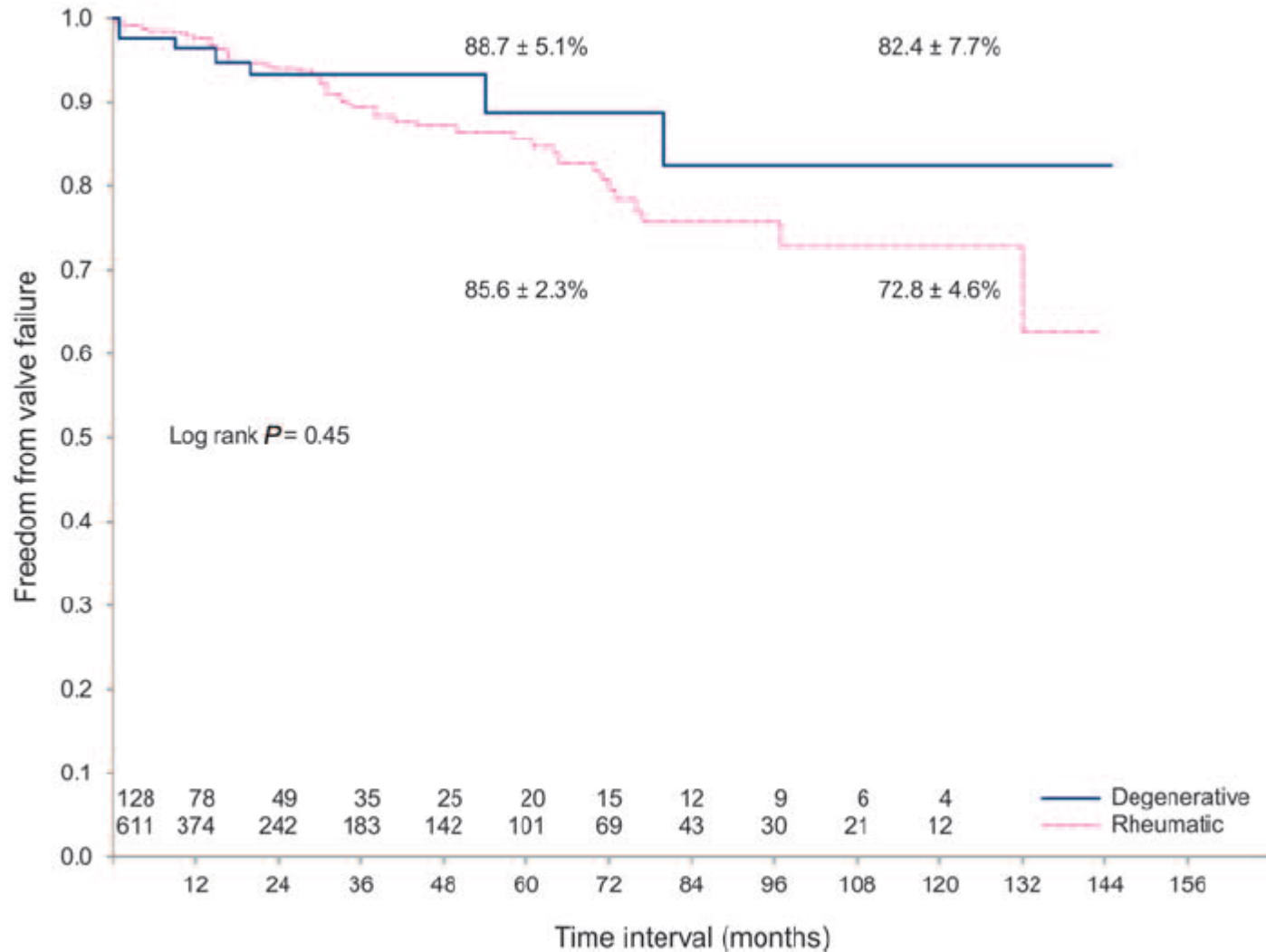
- ✓ il lembo posteriore e' quello piu frequentemente coinvolto nel processo reumatico
- ✓ il distacco del lembo posteriore dall'anello consente di lavorare agevolmente sull'apparato sottovalvolare mediante la resezione delle corde retratte



Le lesioni multiple







L'endocardite

Estrema eterogeneità
delle lesioni valvolari

Distruzione del tessuto:

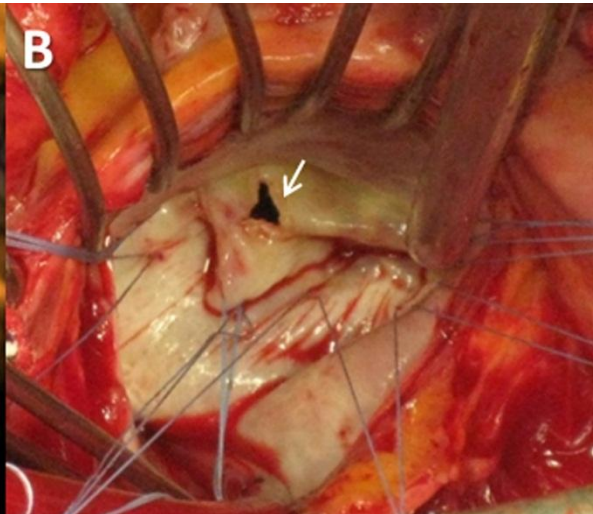
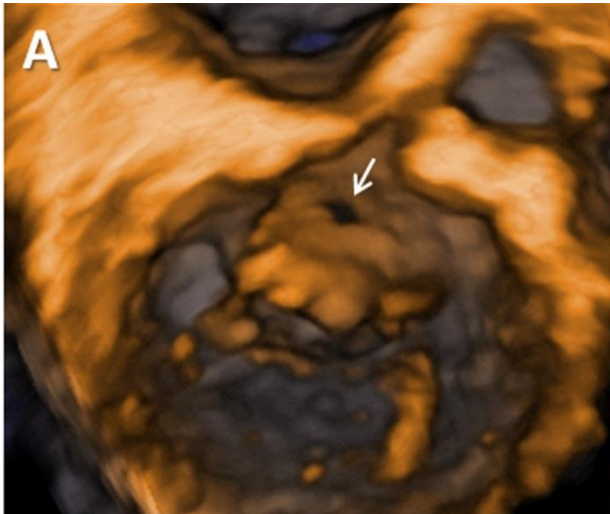
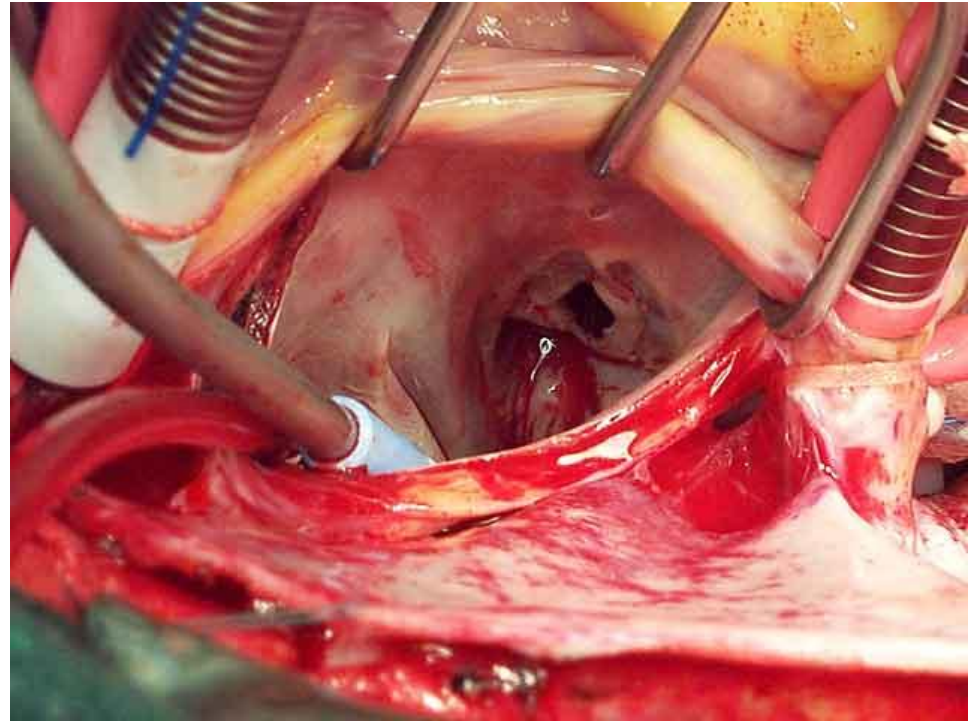
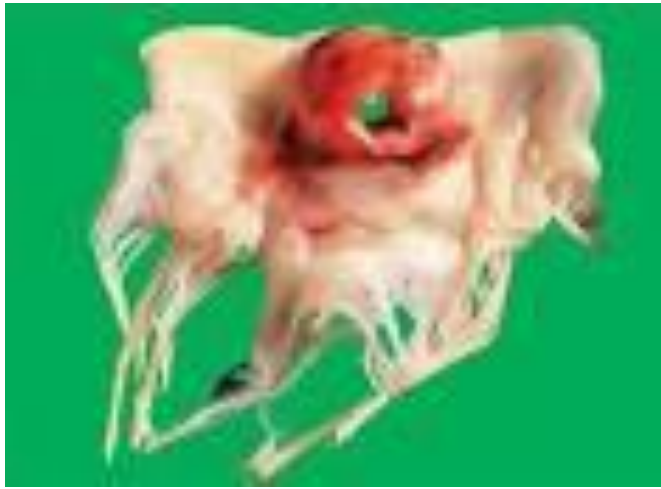- ❖ perdita di sostanza a carico dei lembi
- ❖ rottura corde

Trattamento chirurgico:

- rimozione di TUTTO il tessuto infetto
- ricostruzione

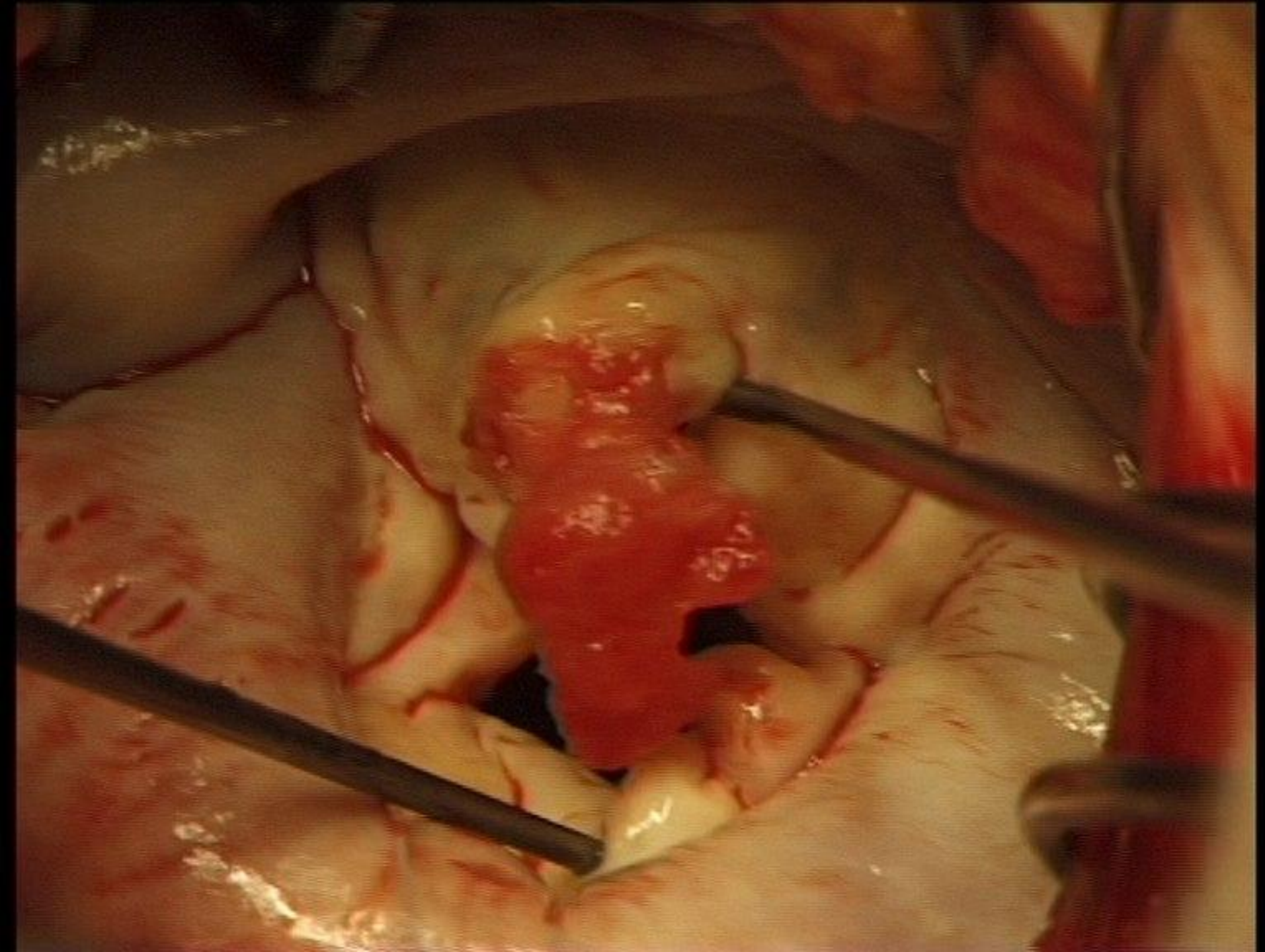
L'endocardite

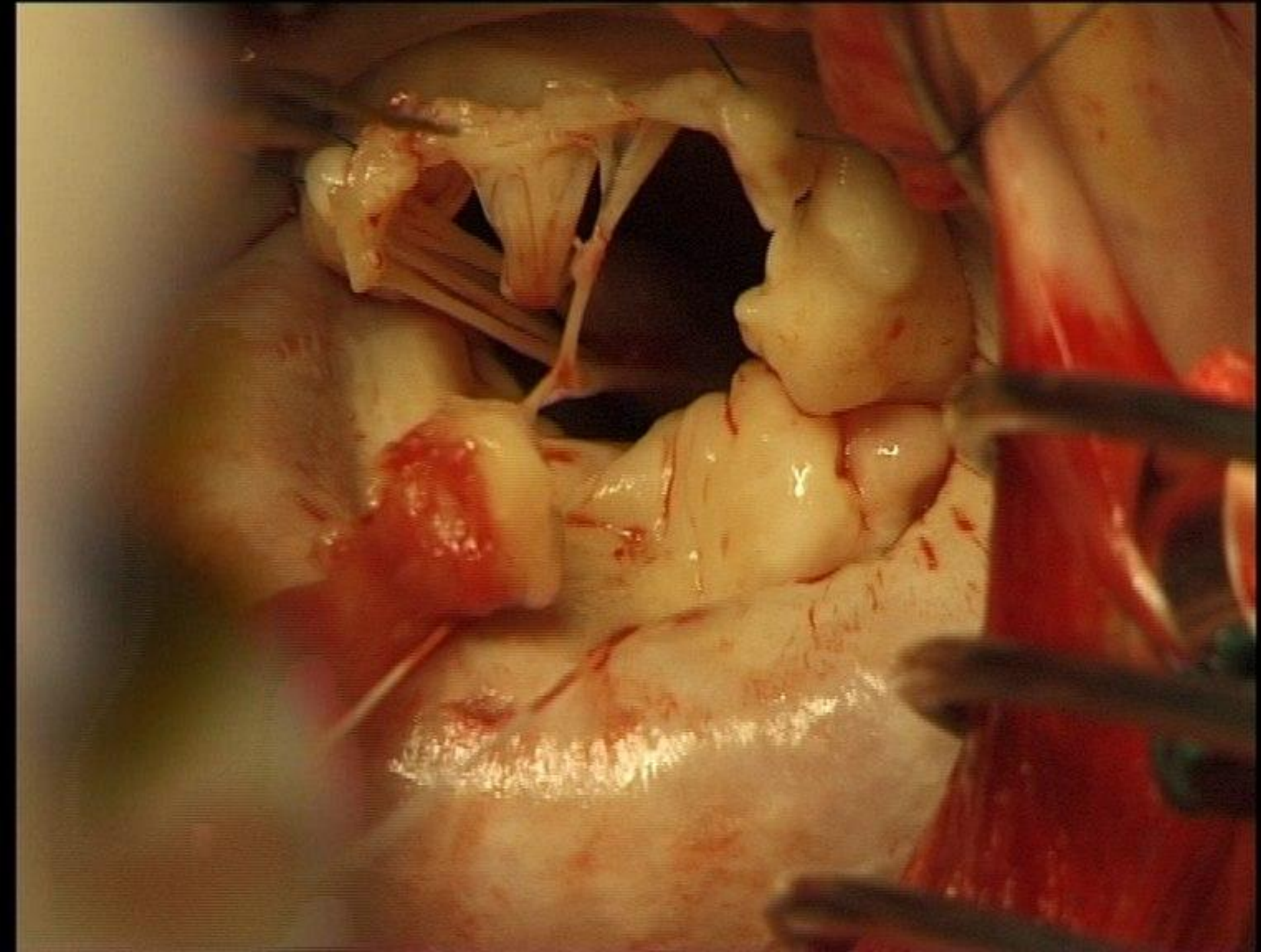
- Estensione e sede della distruzione tissutale
- Coinvolgimento del bordo libero dei lembi

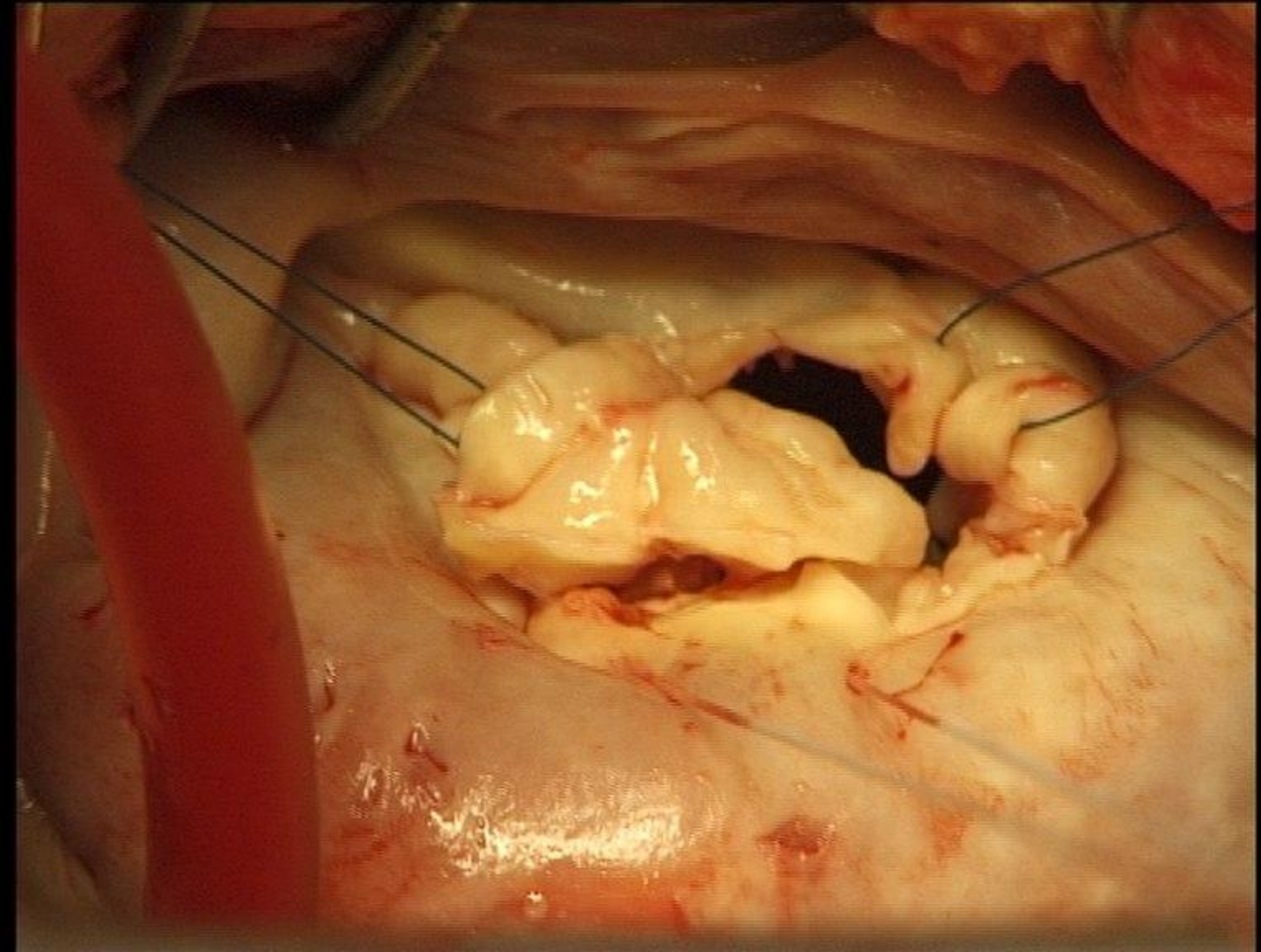


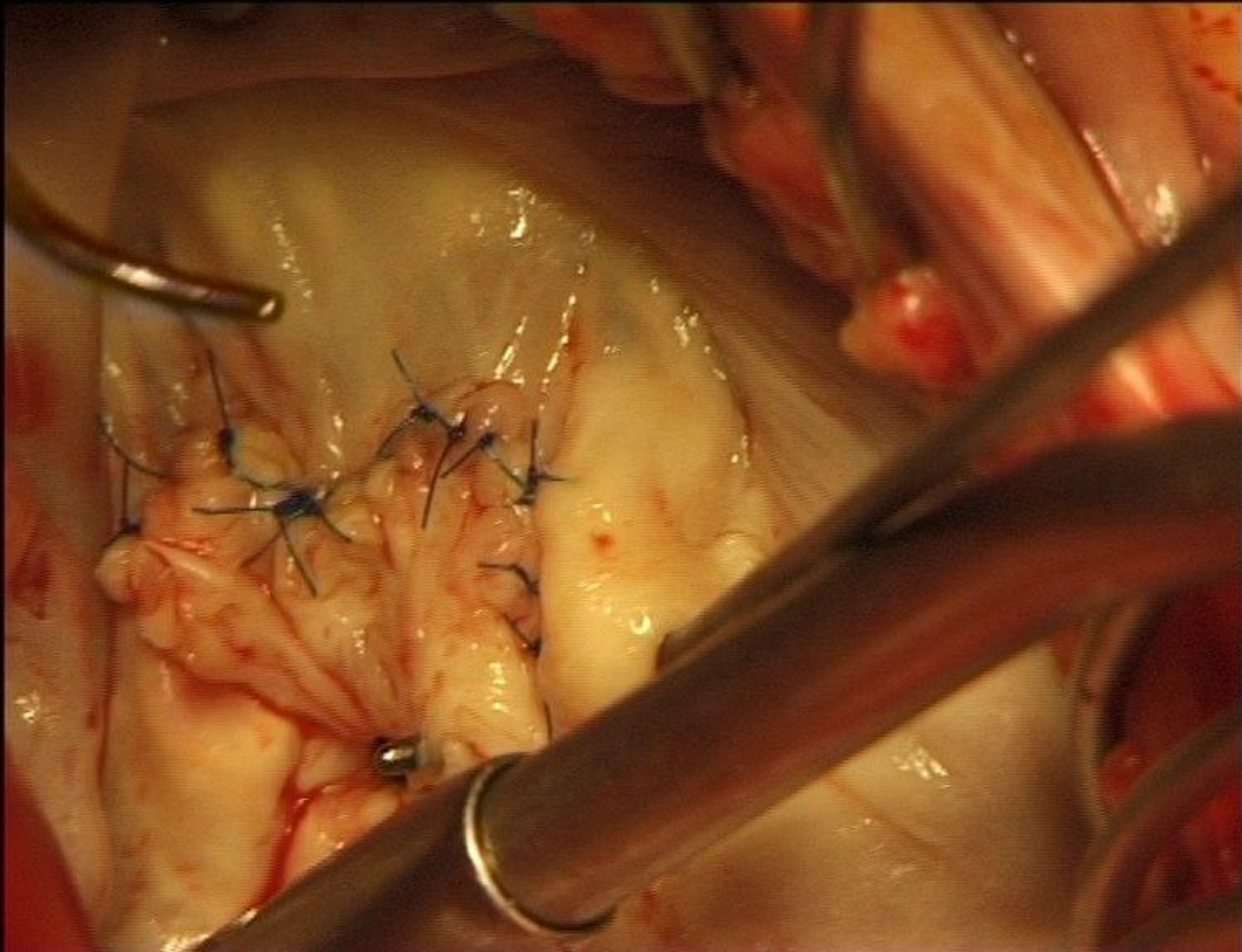
Distruzione ampia e/o coinvolgimento del bordo libero

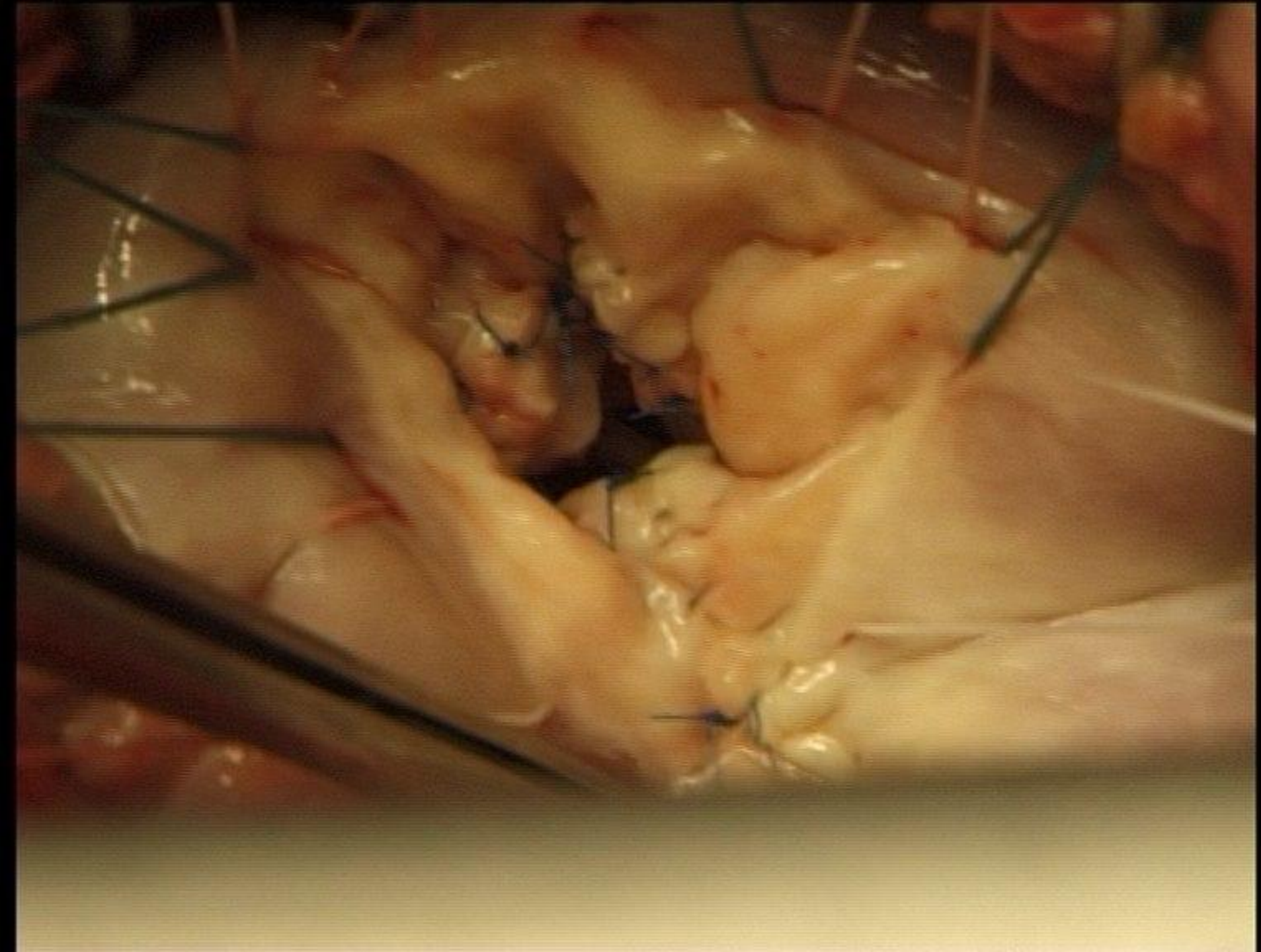
- Trasposizione tessuto mitralico
- Trasposizione tessuto tricuspide
- Ricostruzione con patch di pericardio e sospensione mediante corde artificiali

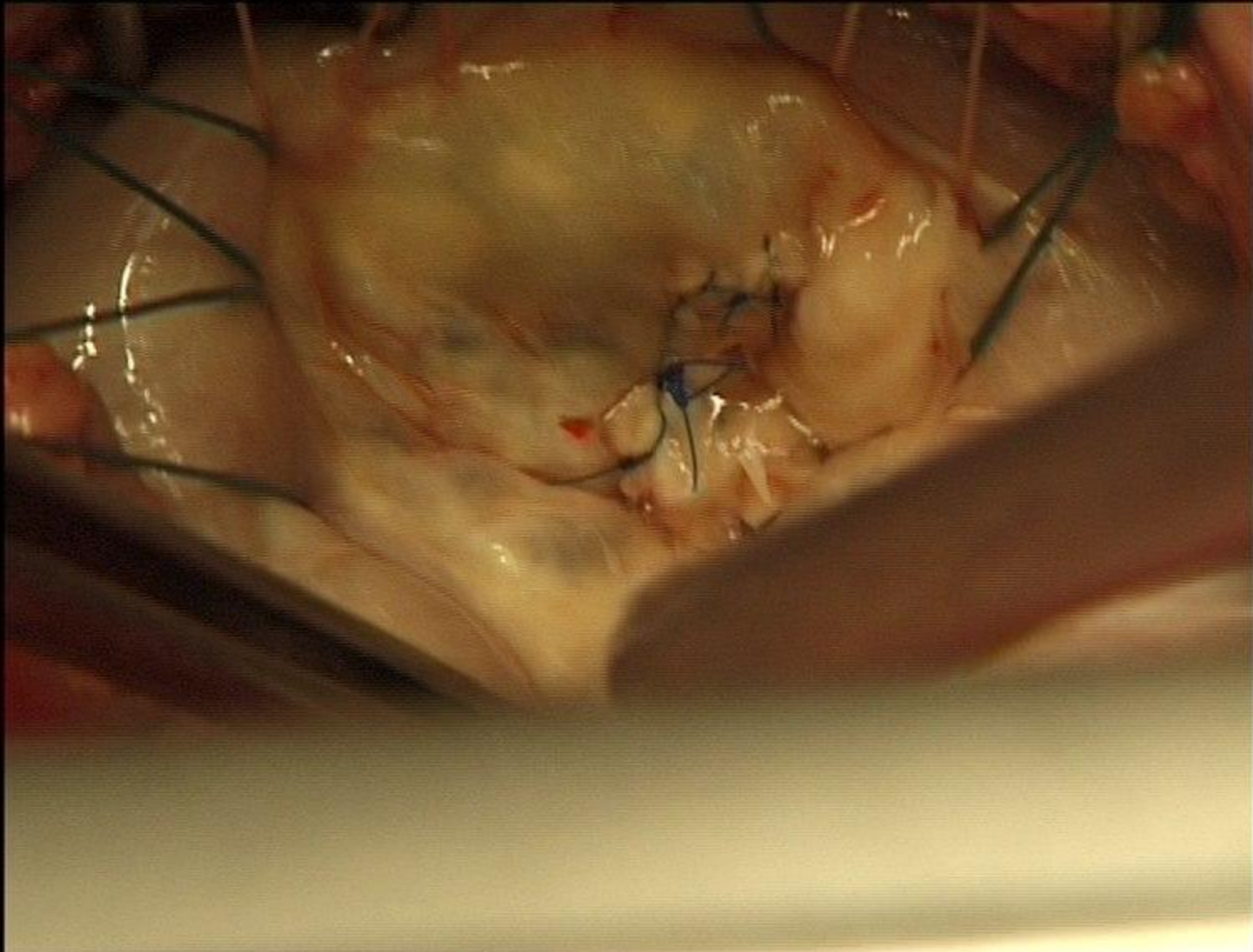


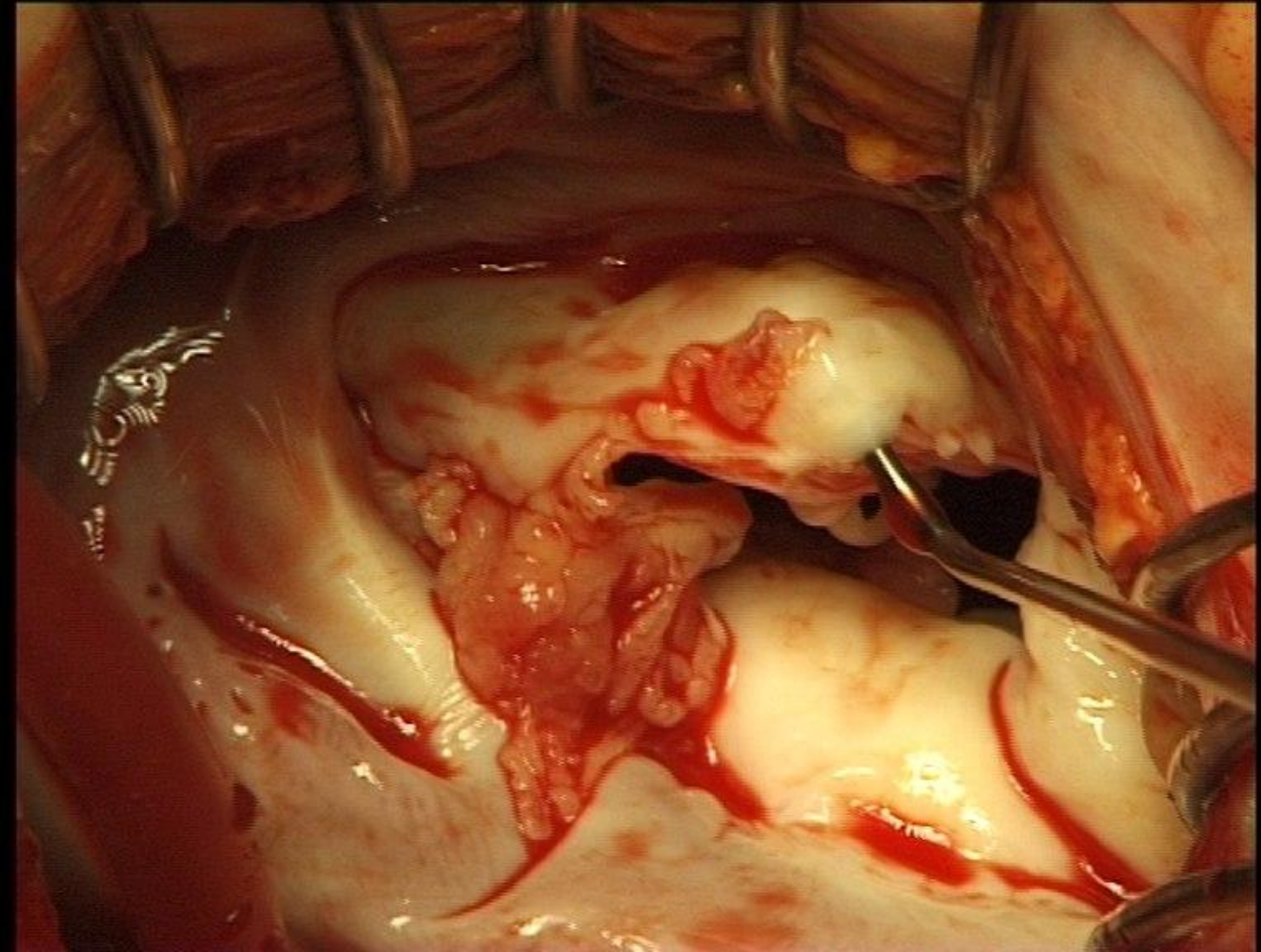


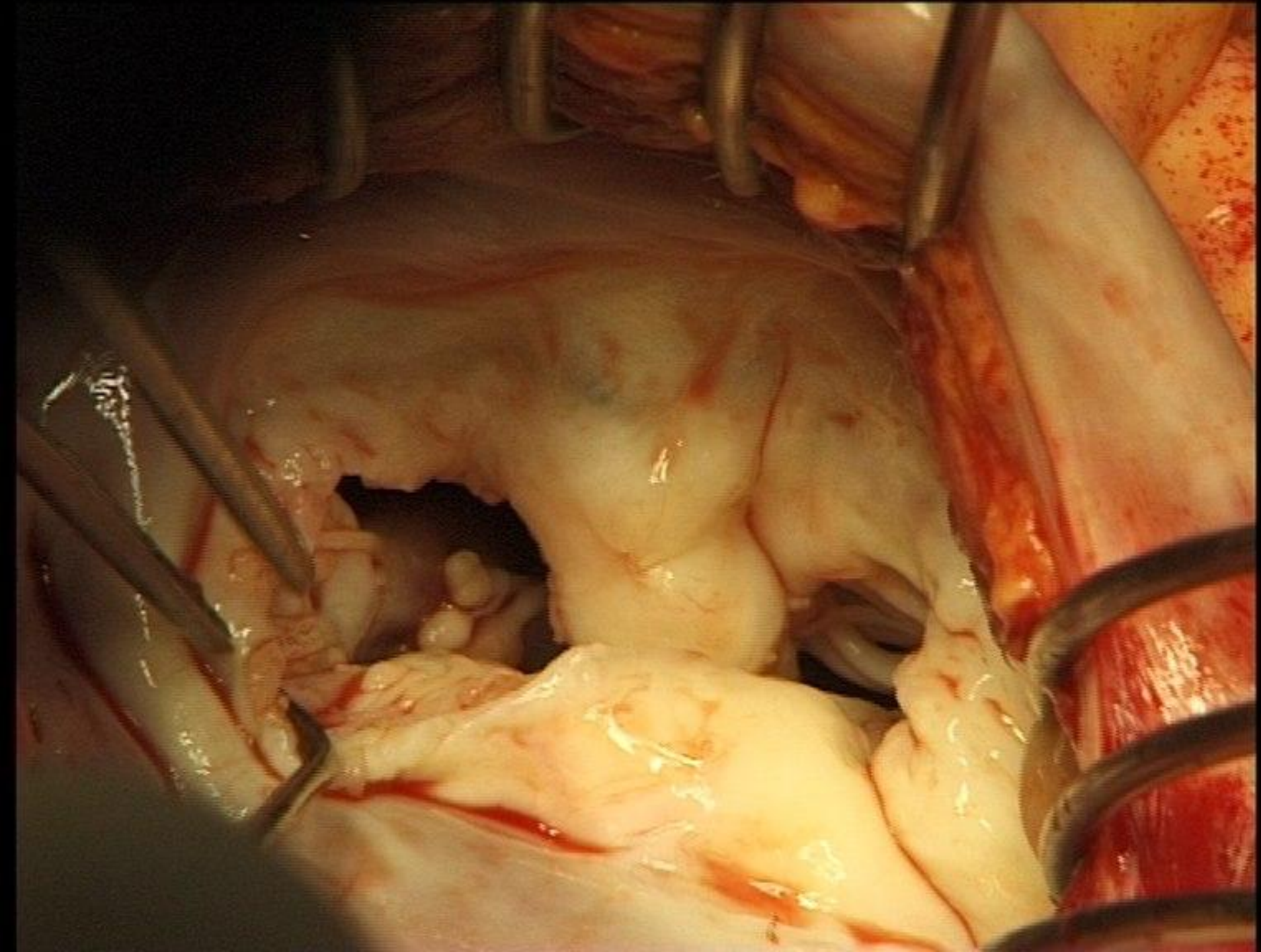








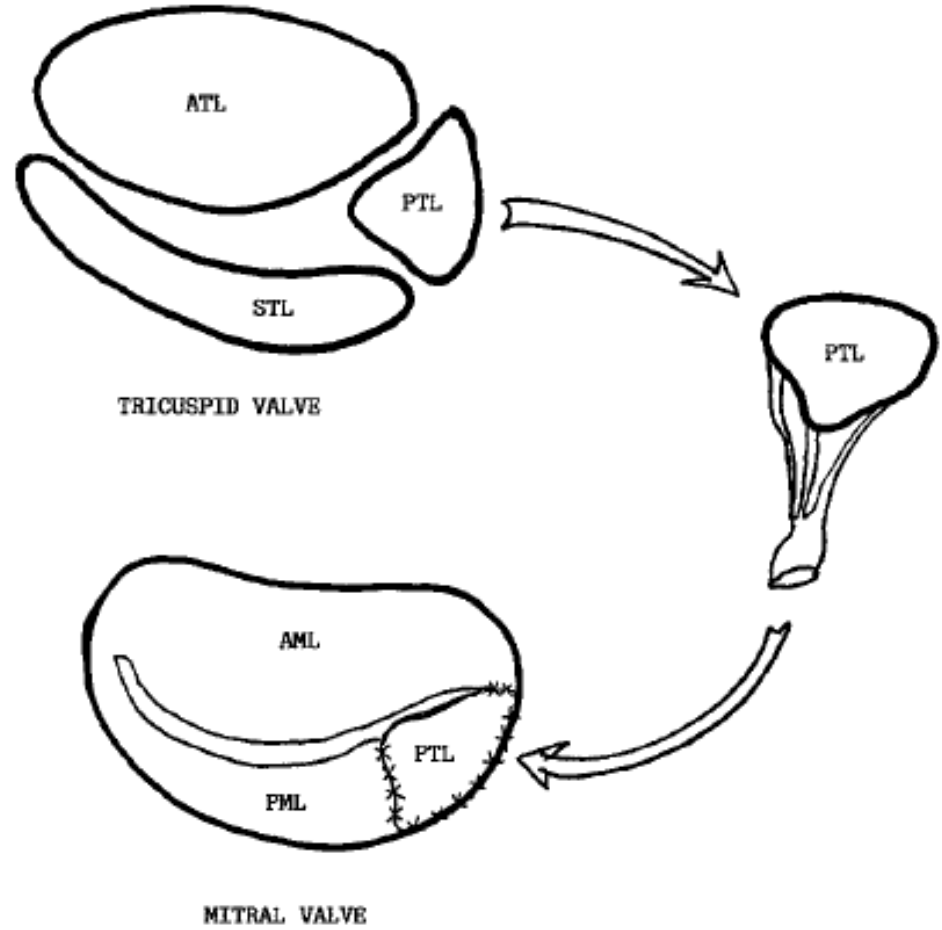


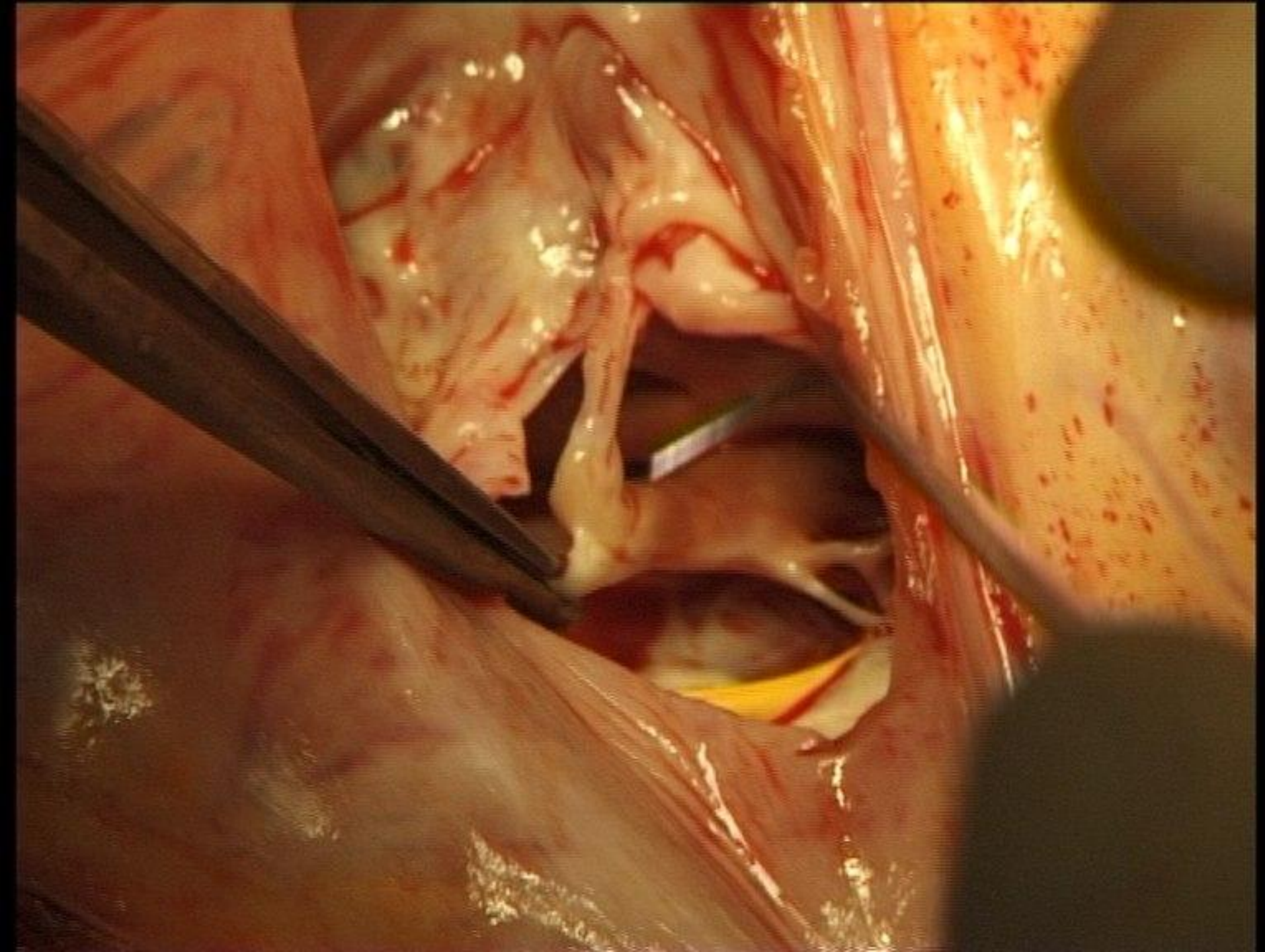


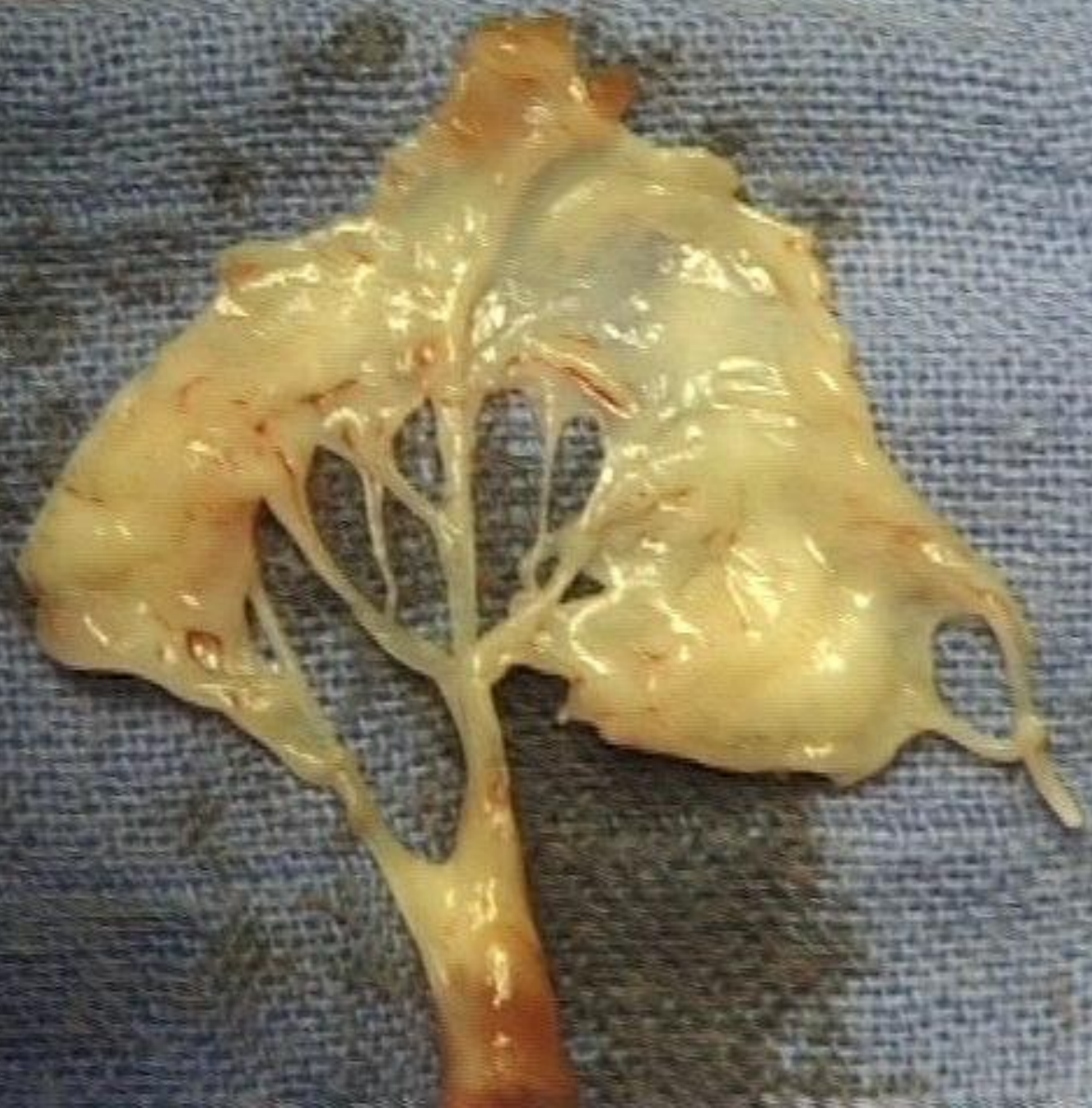TRANSFER OF THE POSTERIOR TRICUSPID LEAFLET AND CHORDAE FOR MITRAL VALVE REPAIR

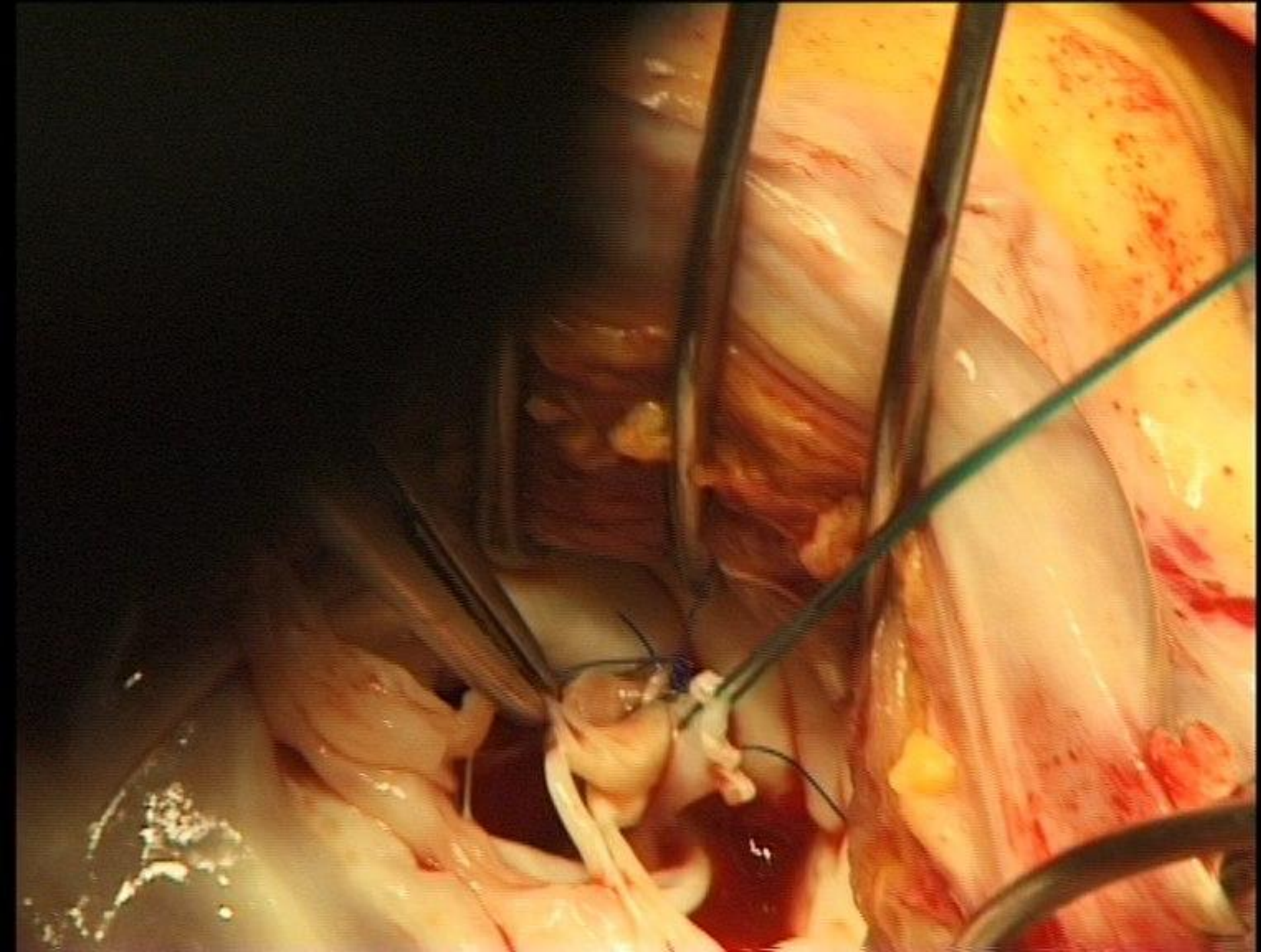
Ulrik Hvass, MD,^a José Calliani, MD,^a Isabelle Nataf,^a Jean Michel Julliard, MD,^b and Alex Vahanian, MD,^c *Paris, France*

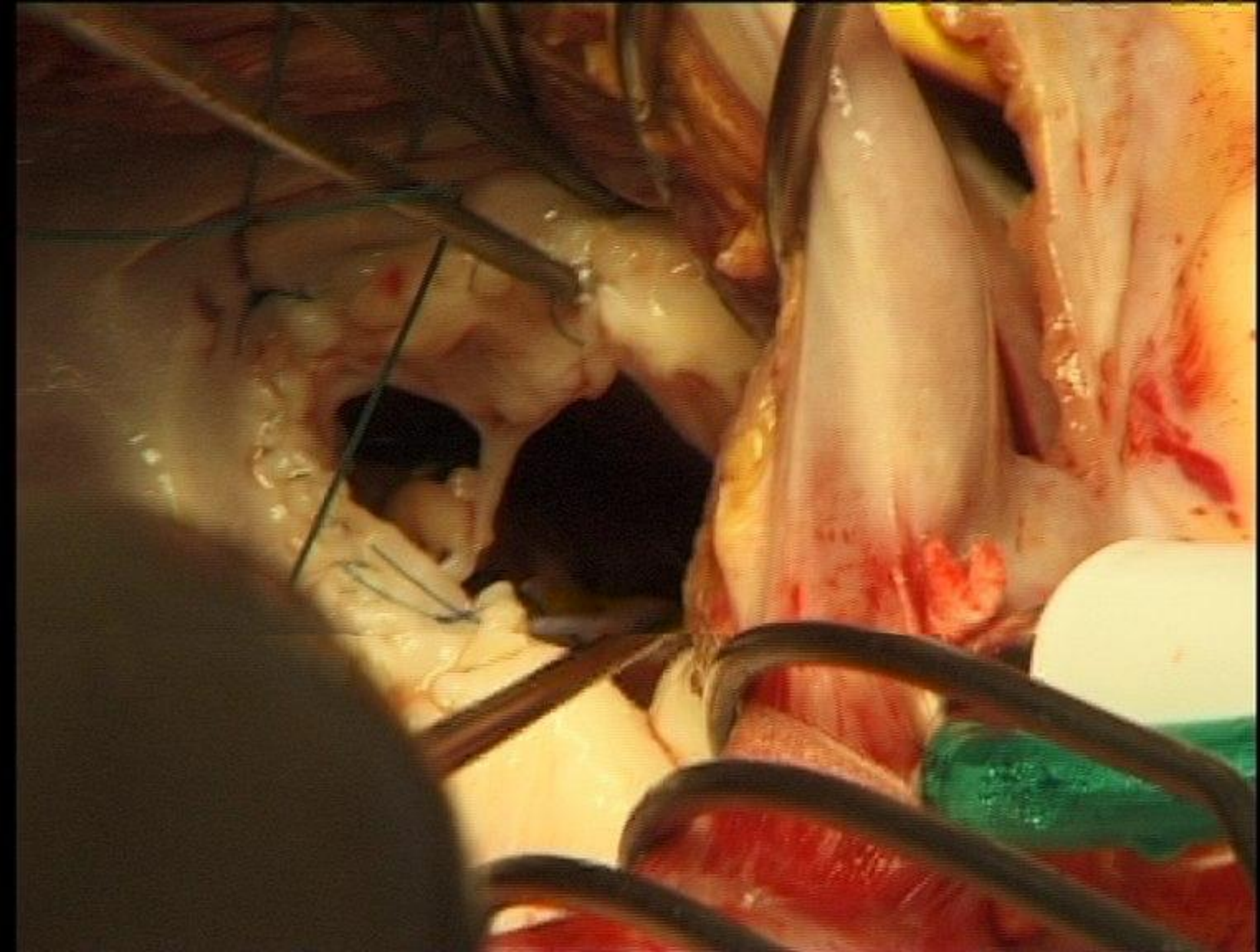
JTCVS 1995

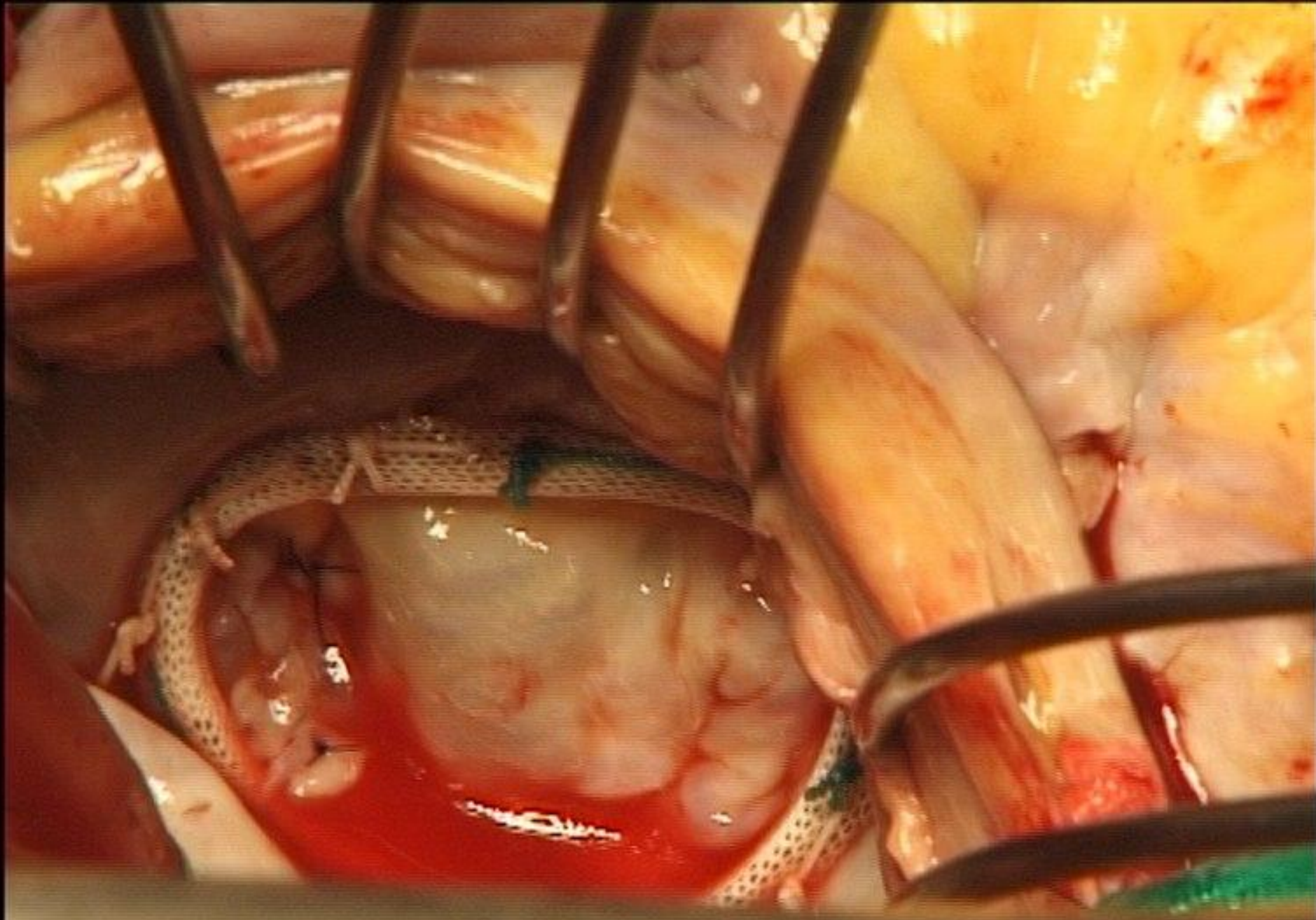


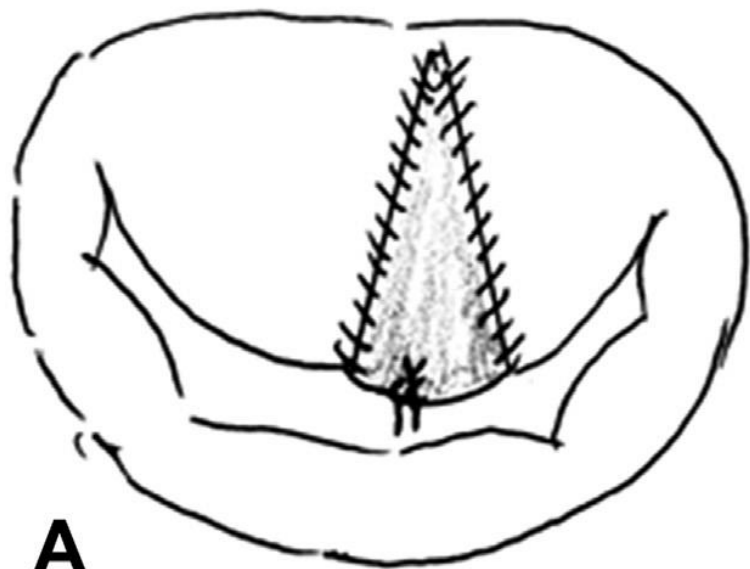




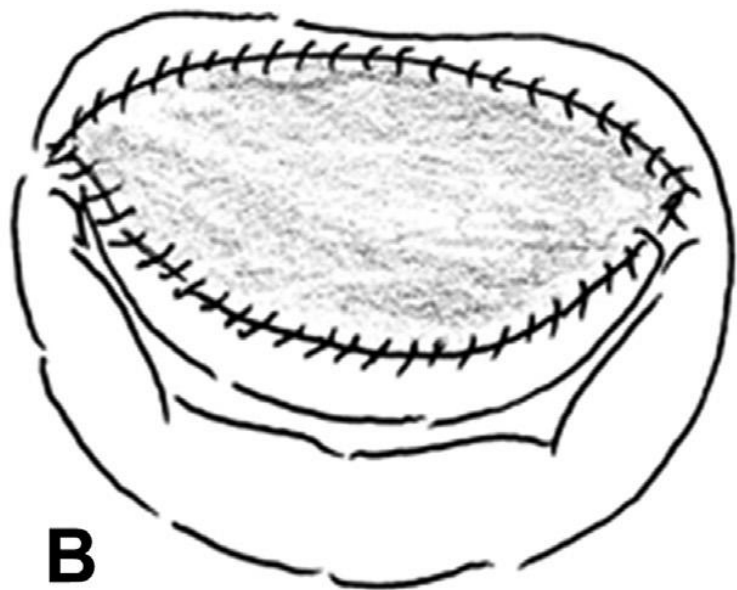



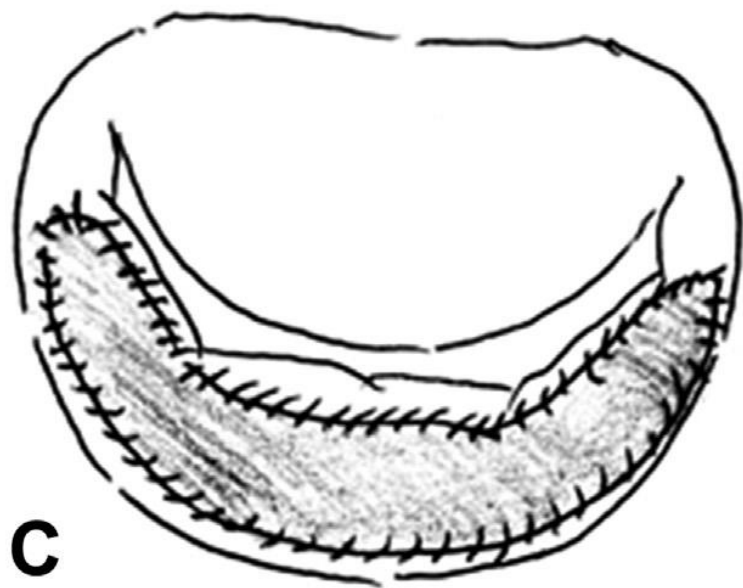




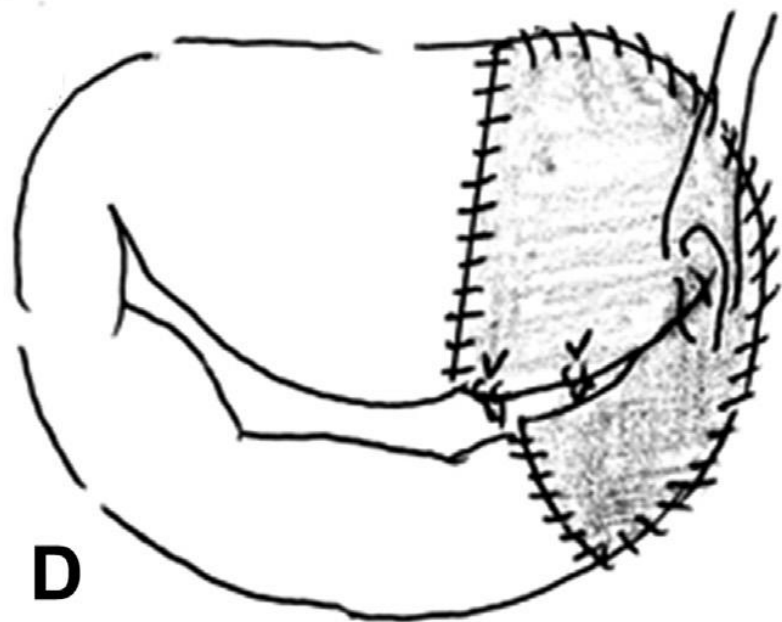
A



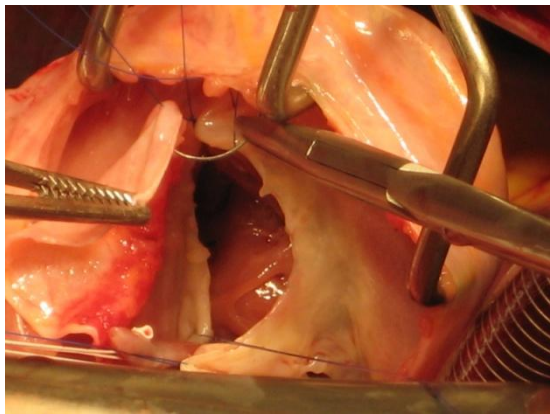
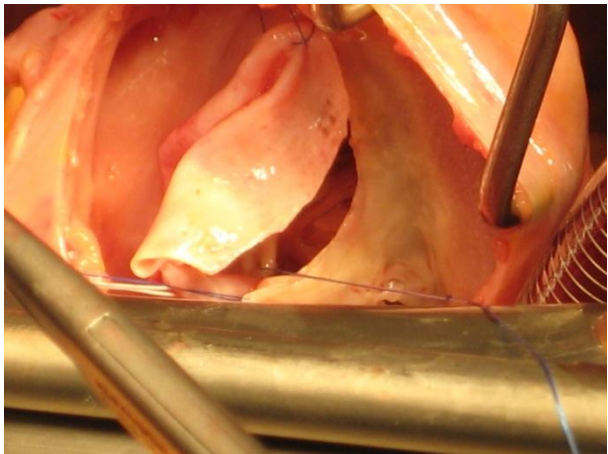
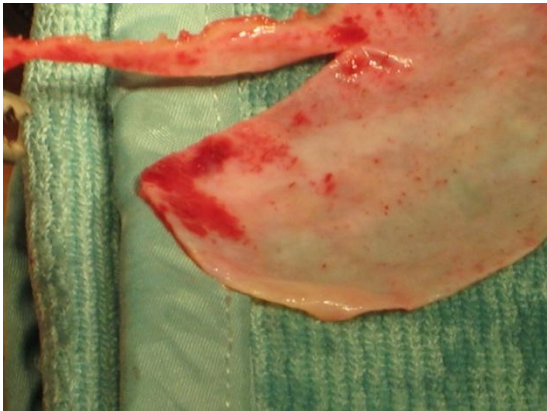
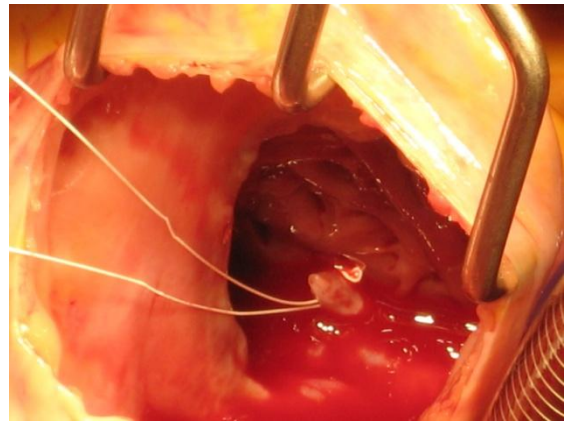
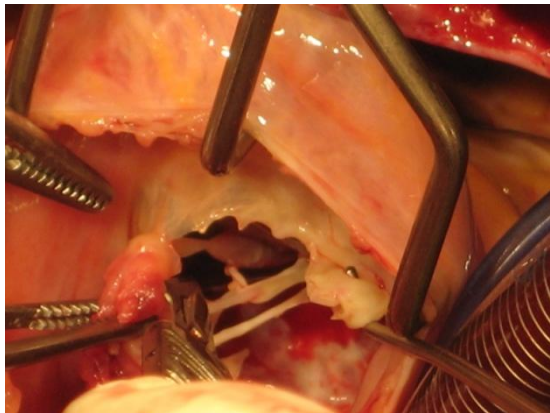
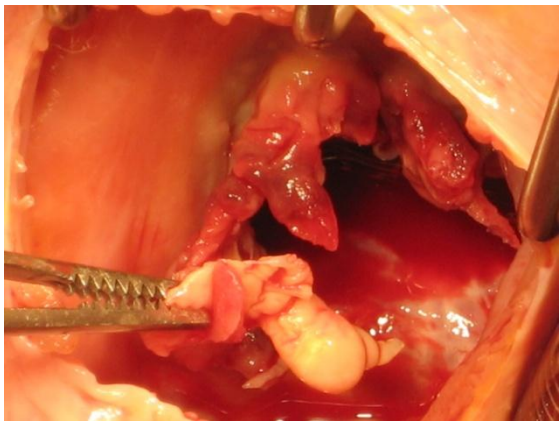
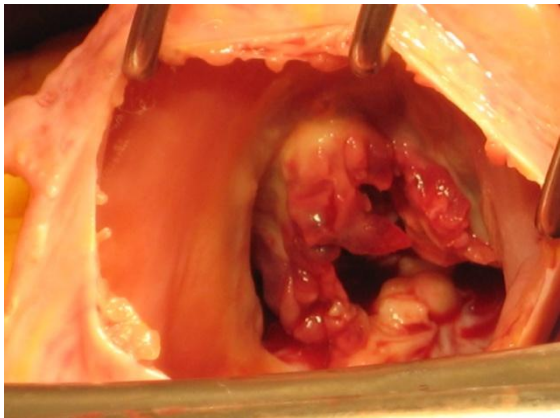
B

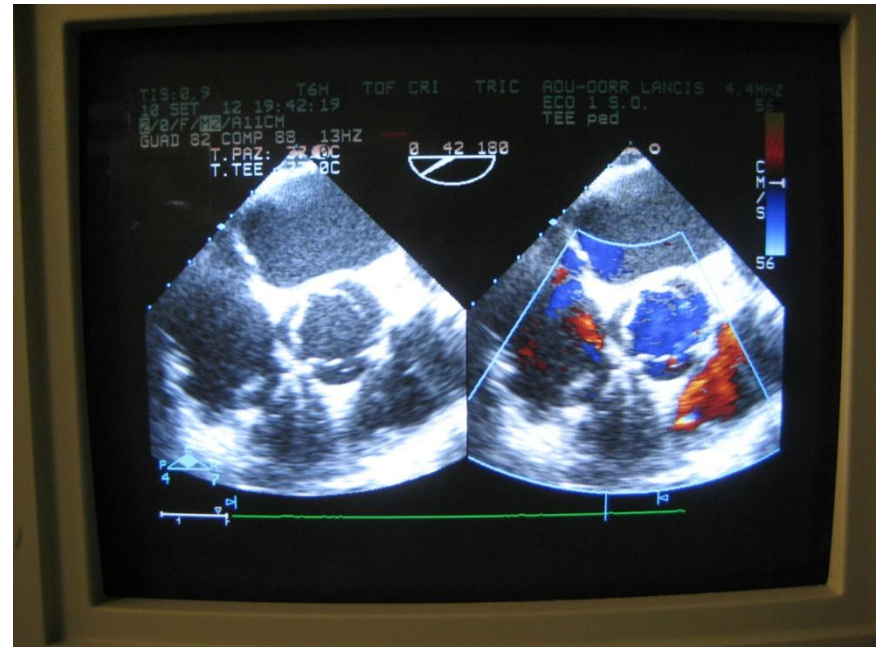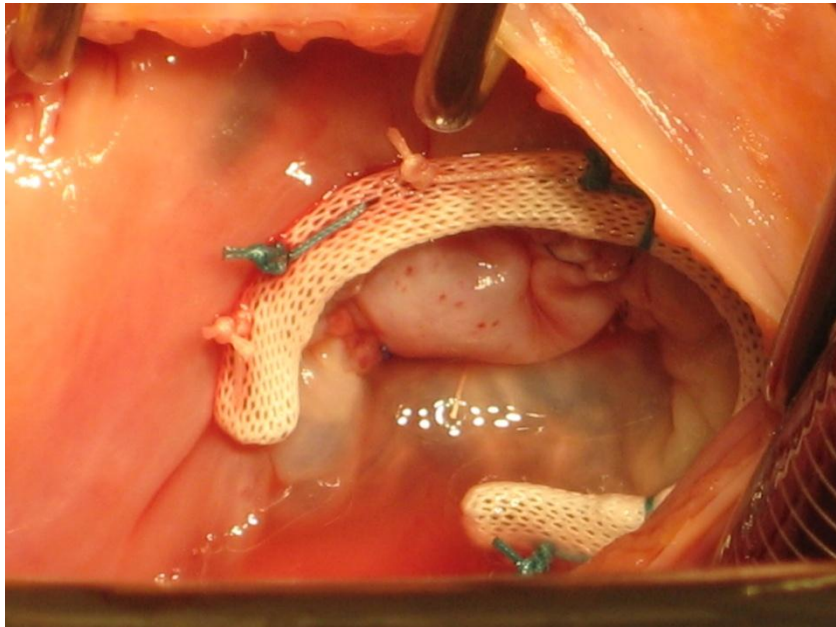
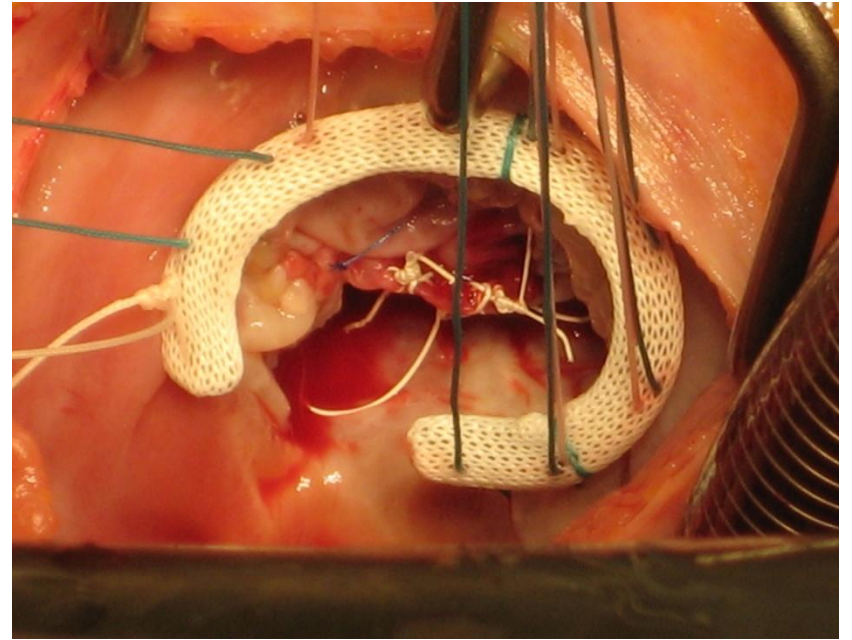
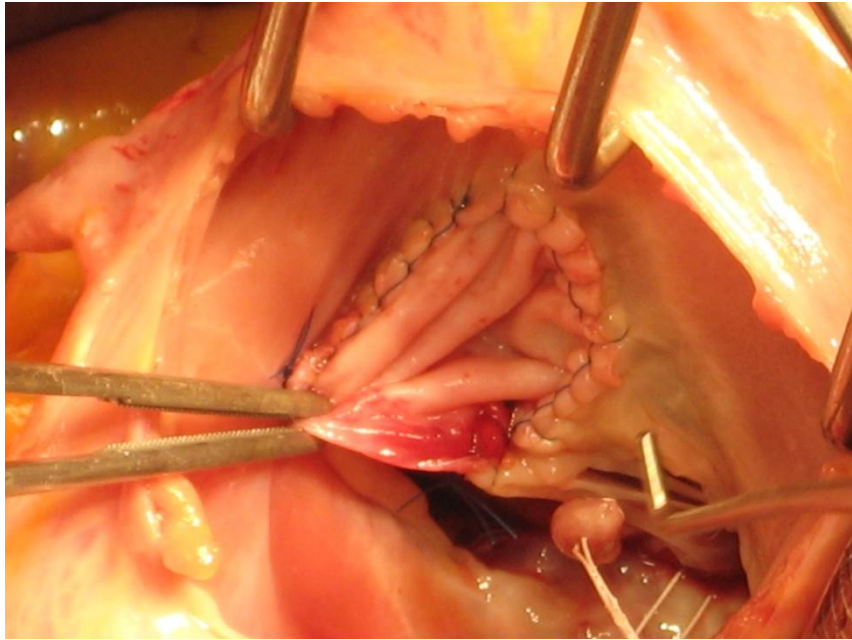


C

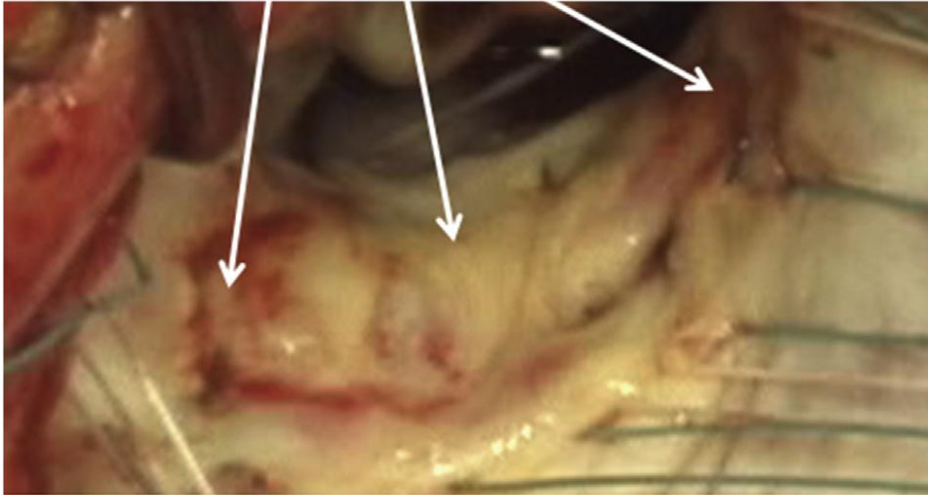


D



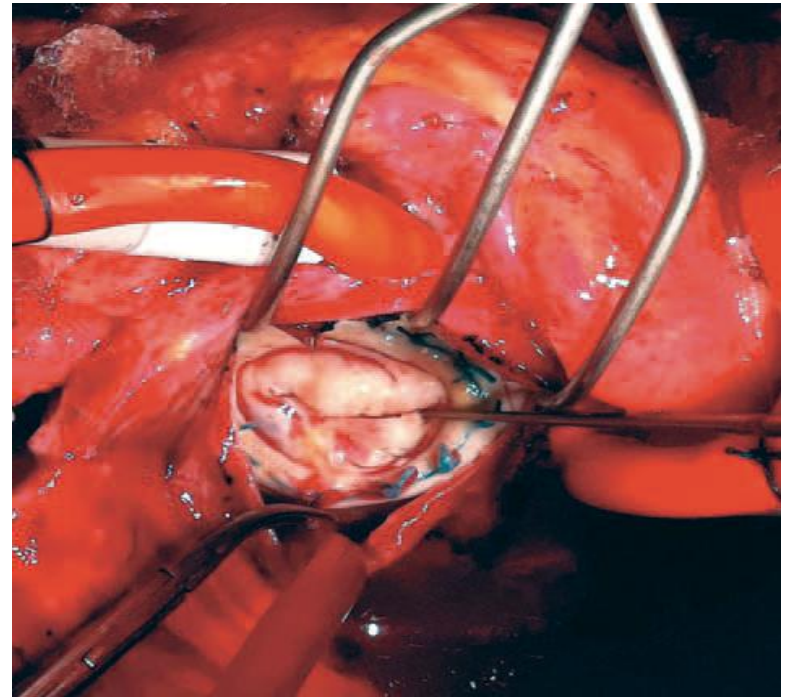


Pericardium 19 years after posterior mitral leaflet augmentation



posterior mitral leaflet

A distanza di 7 aa dalla riparazione



Late Results of Mitral Valve Repair With Glutaraldehyde-Treated Autologous Pericardium

Yu Shomura, MD, Yukikatsu Okada, MD, Michihiro Nasu, MD, Tadaaki Koyama, MD, Mitsuru Yuzaki, MD, Takashi Murashita, MD, Naoto Fukunaga, MD, and Yasunobu Konishi, MD

Department of Cardiovascular Surgery, Kobe City Medical Center General Hospital, Kobe, Japan

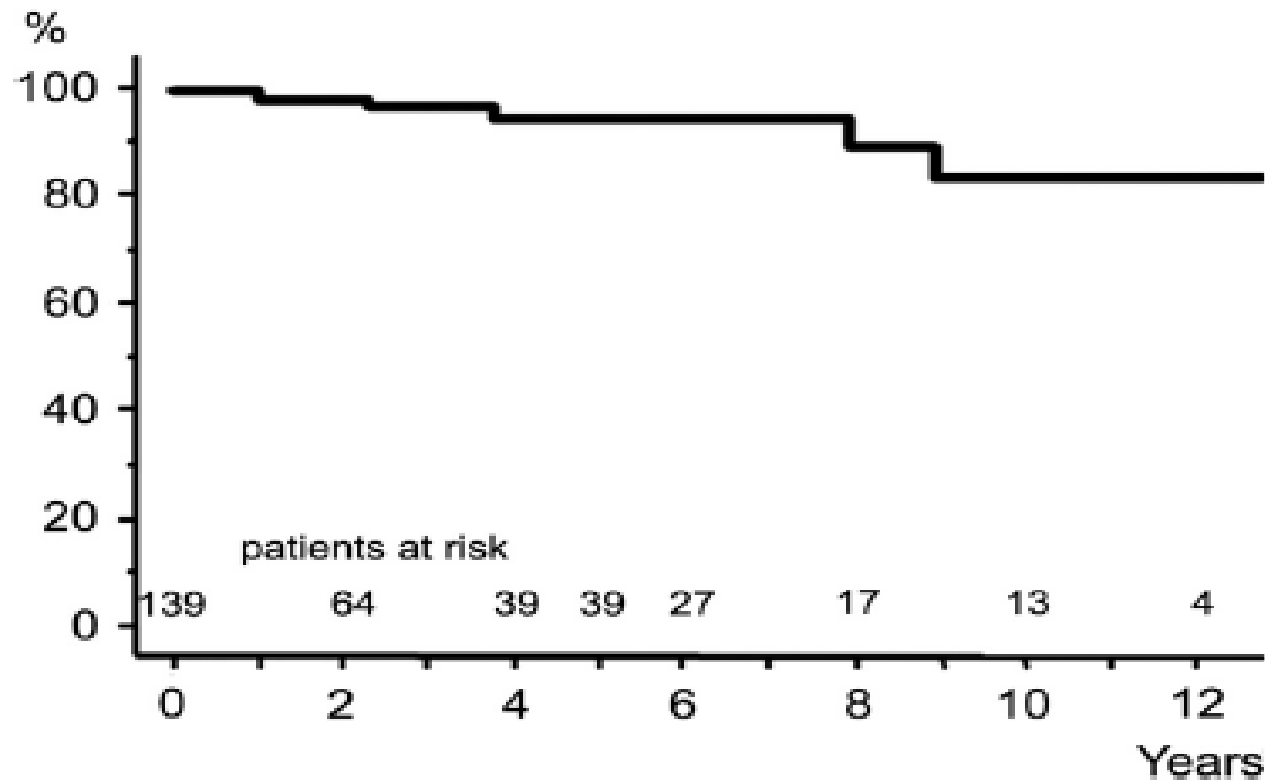


Fig 3. Actuarial freedom from mitral regurgitation grade more than 2+ after mitral valve repair with glutaraldehyde-treated autologous pericardium.

Conclusioni

- L'utilizzo di diverse tecniche chirurgiche e la loro associazione consente oggi di estendere con successo la chirurgia riparativa anche a lesioni molto complesse
- L'esperienza chirurgica gioca un ruolo fondamentale nella applicabilità delle tecniche complesse