



La terapia della stenosi aortica con TAVI : Indicazioni e tecnica

Procedura Eco guidata con 3D. Perché eco 3D. Un'indicazione che presenta aspetti clinici e tecnici. Un esempio di stretta collaborazione tra cardiocirurgo e cardiologo esperto in imaging.

***Dr. Gloria Tamborini
Responsabile Servizio Interventistica Strutturale,
Area Imaging Cardiovascolare, Centro Cardiologico Monzino***

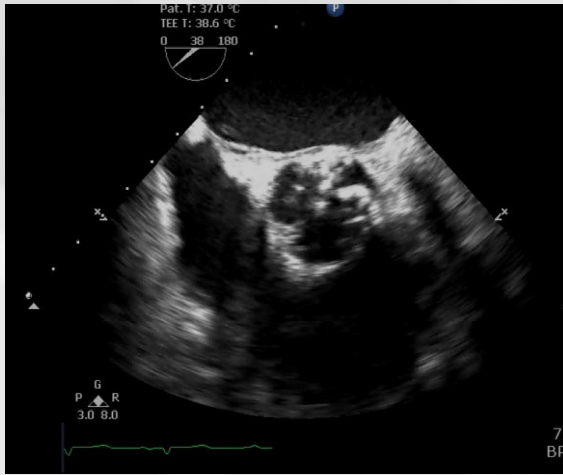
Procedura eco-guidata

- ✓ *Valutazione preoperatoria*
- ✓ *Monitoraggio intraoperatorio*
- ✓ *Valutazione del risultato*

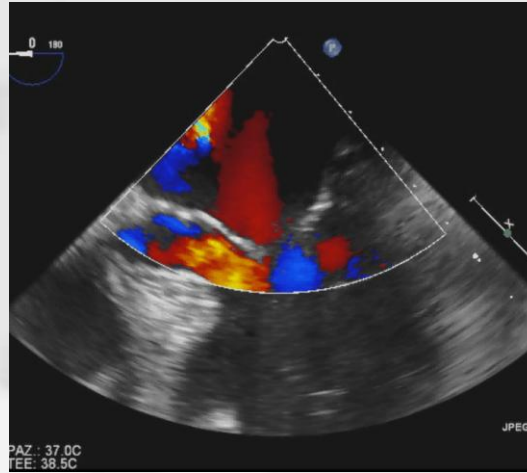
Procedura eco-guidata

- ✓ *Valutazione preoperatoria*
- ✓ *Monitoraggio intraoperatorio*
- ✓ *Valutazione del risultato*

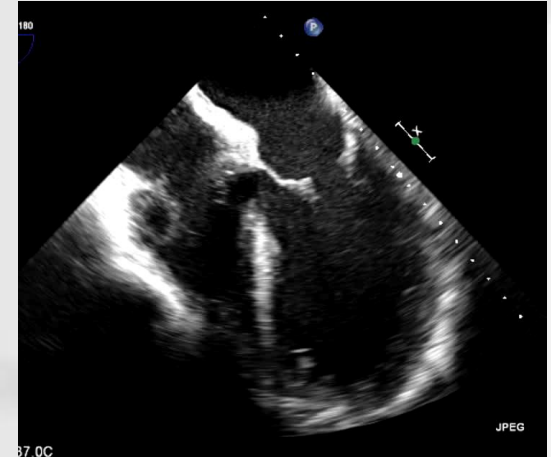
VALUTAZIONE TEE PREOPERATORIA



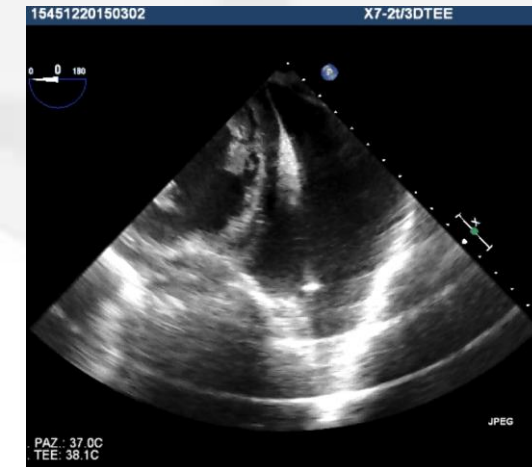
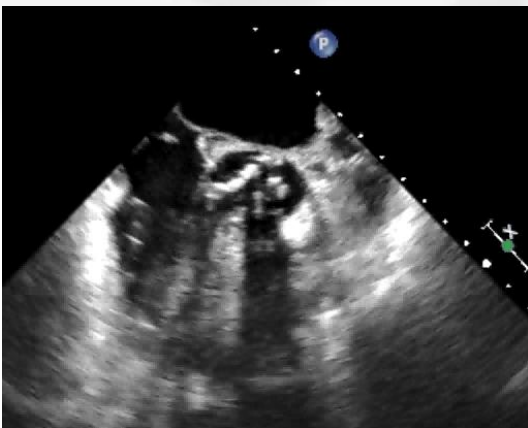
Anatomia valvolare



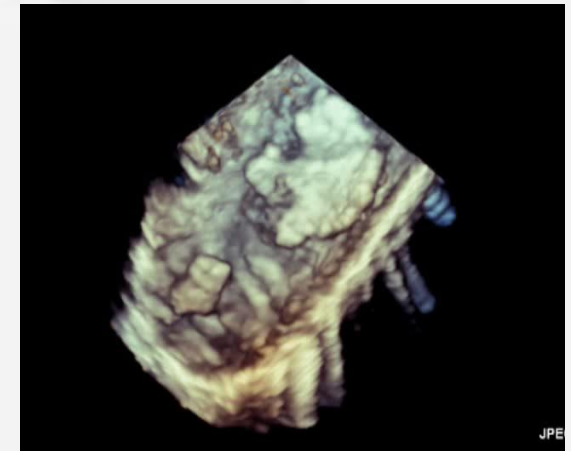
**Rigurgito mitralico
e/o aortico**



Funzione ventricolare sx



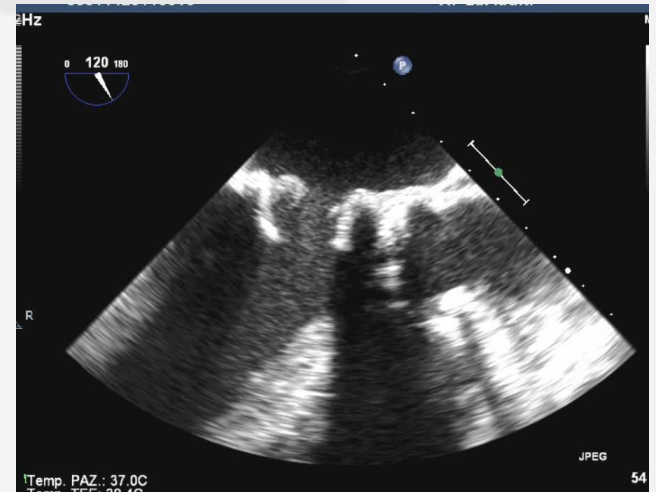
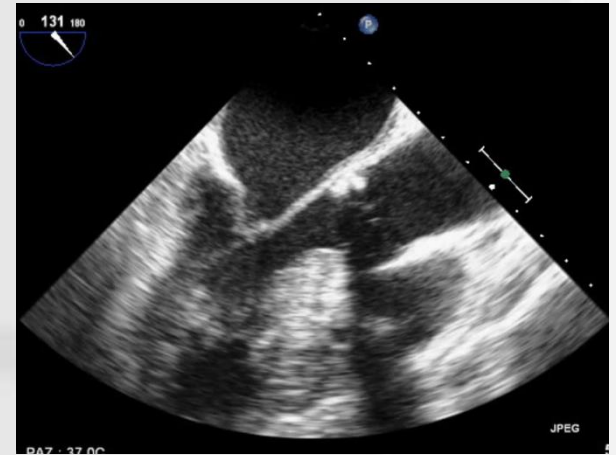
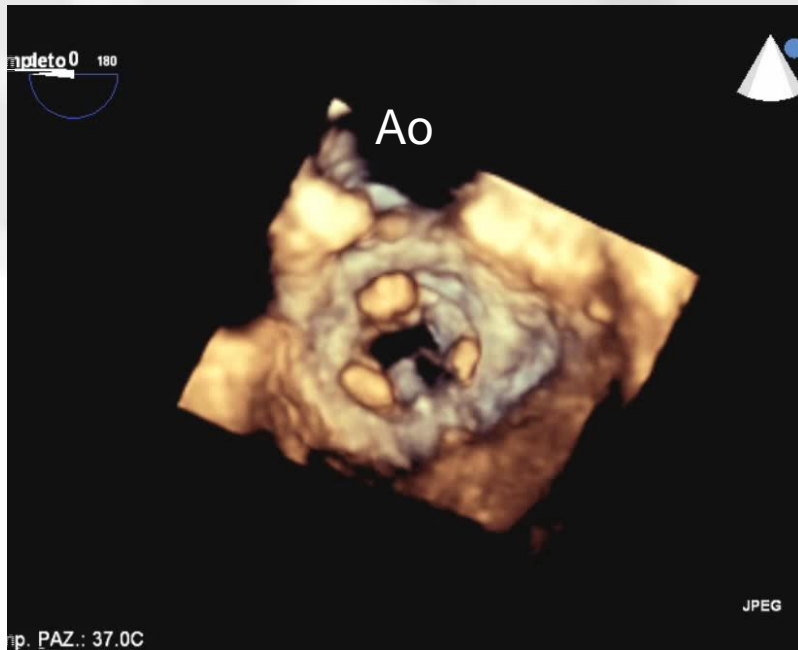
Anatomia del pericardio



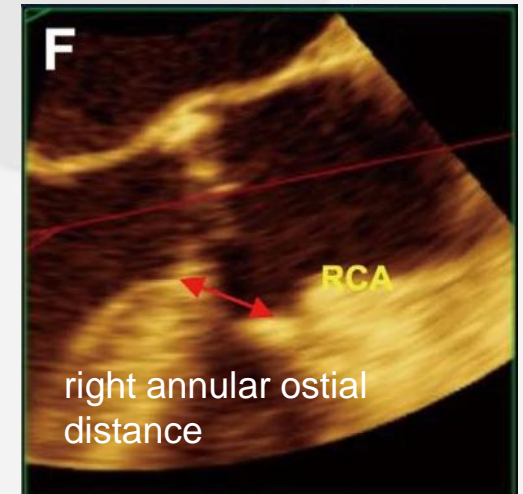
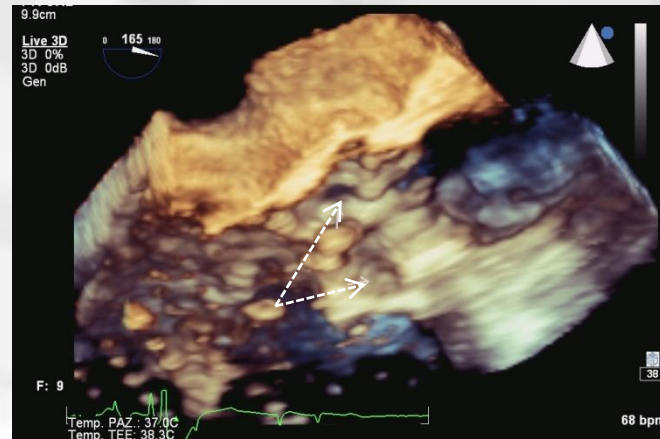
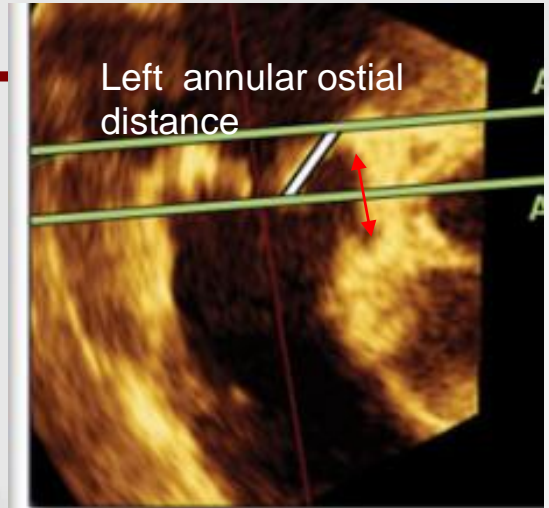
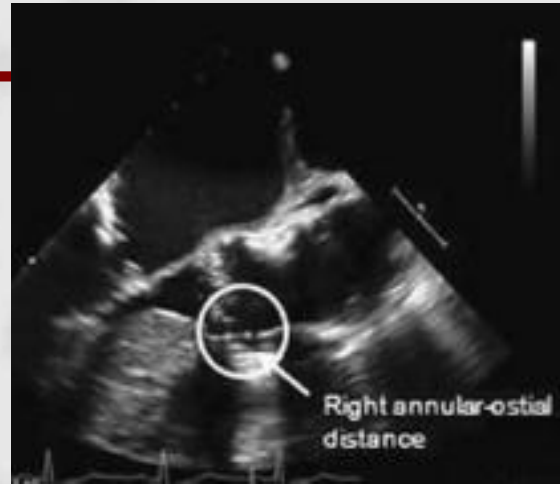
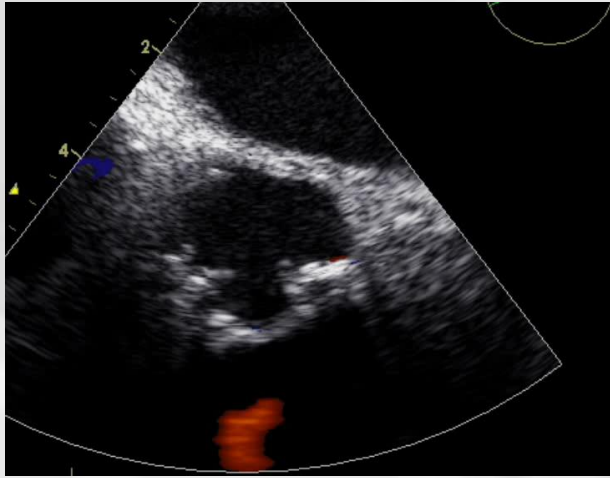
Aterosclerosi aortica

VALUTAZIONE TEE PREOPERATORIA

- ✓ *Anatomia della radice*
- ✓ *Anatomia del tratto d'efflusso*



VALUTAZIONE TEE PREOPERATORIA



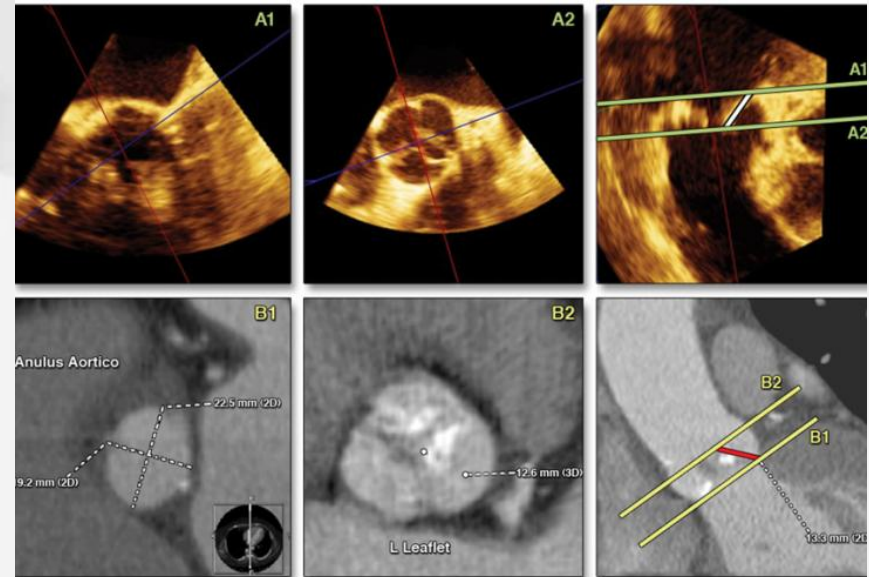
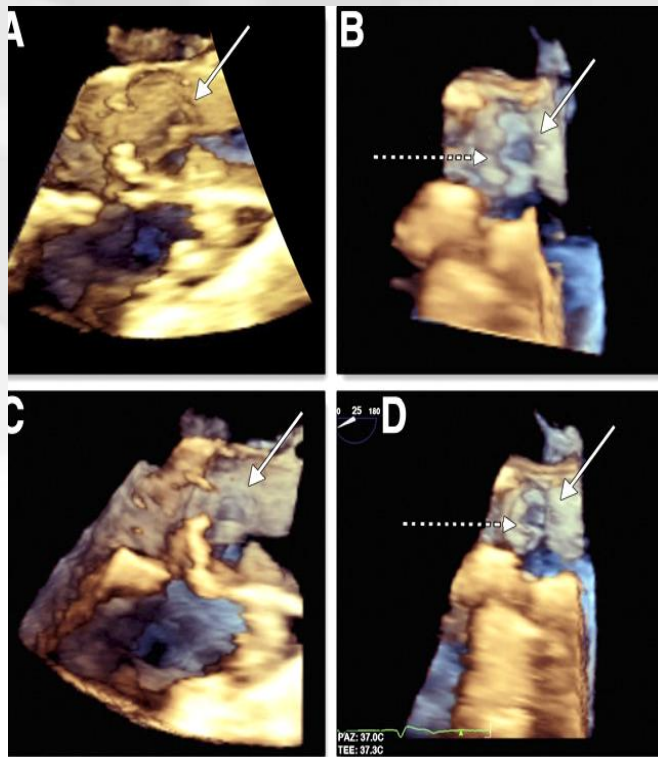
✓ *Flusso coronarico*

✓ *Distanza ostio – coronarico anello aortico*

Feasibility and Accuracy of 3DTEE Versus CT for the Evaluation of Aortic Valve Annulus to Left Main Ostium Distance Before Transcatheter Aortic Valve Implantation

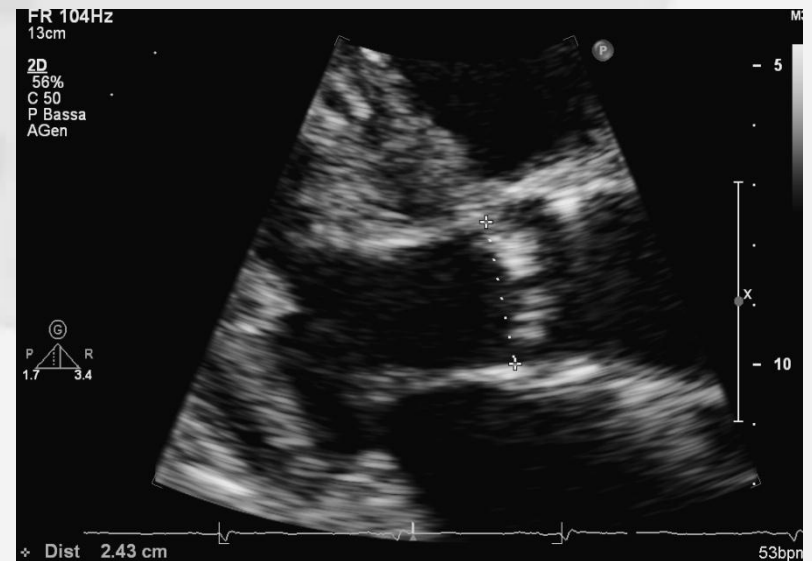Gloria Tamborini, MD,* Laura Fusini, MS,* Paola Gripari, MD,* Manuela Muratori, MD,*
Claudia Cefalù, MD,* Francesco Maffessanti, PhD,* Francesco Alamanni, MD,*†
Antonio Bartorelli, MD,*† Gianluca Pontone, MD,* Daniele Andreini, MD,*
Erika Bertella, MD,* Cesare Fiorentini, MD,*† Mauro Pepi, MD*

3DTEE e coronararie



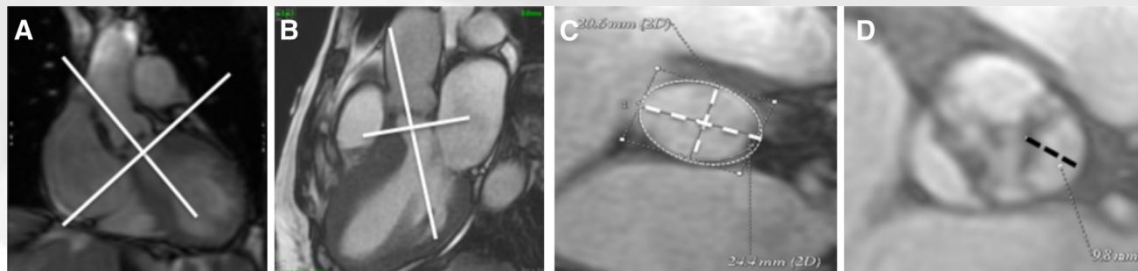
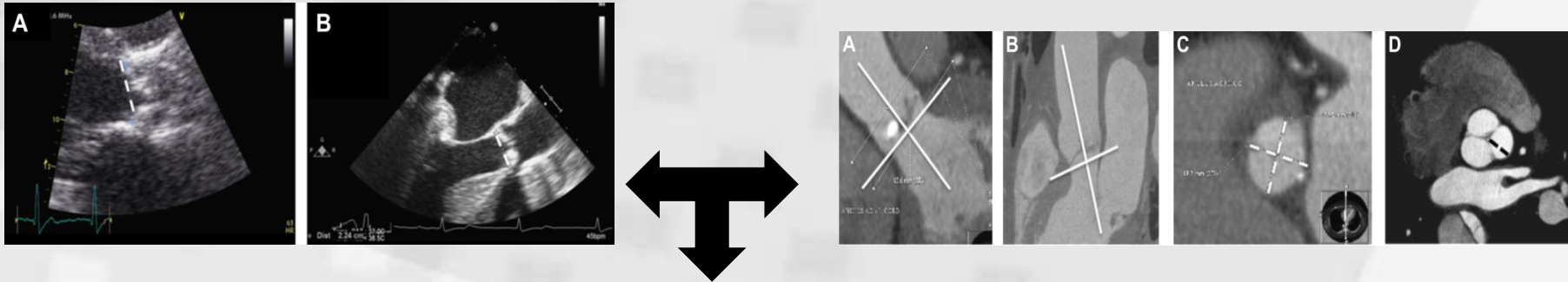
VALUTAZIONE TEE PREOPERATORIA

- ✓ *Anatomia valvolare aortica*
(*calcificazioni/bicuspidia*)
- ✓ *Anatomia della radice*
- ✓ *Rigurgito mitralico e/o aortico*
- ✓ *Flusso coronarico*
- ✓ *Anatomia del pericardio*
- ✓ *Aterosclerosi aortica*
- ✓ *Funzione ventricolare sx*
- ✓ ***DIMENSIONI DELL'ANELLO VALVOLARE AORTICO***



Comparison of Accuracy of Aortic Root Annulus Assessment With Cardiac Magnetic Resonance Versus Echocardiography and Multidetector Computed Tomography in Patients Referred for Transcatheter Aortic Valve Implantation.

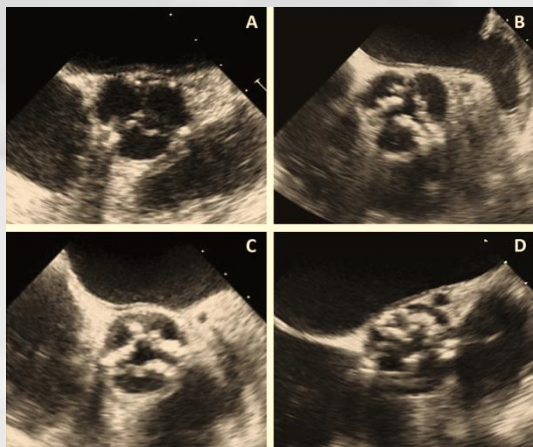
Pontone et al. Am J Cardiol 2013



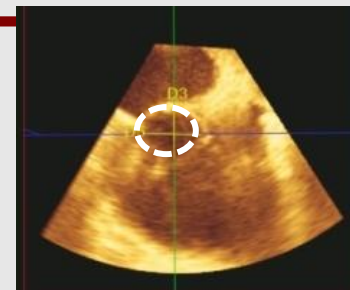
Variable	CMR	TTE	TEE	MDCT
AoA maximum diameter (mm)	26.4 ± 2.8	—	—	26.5 ± 2.8
AoA minimum diameter (mm)	20.6 ± 2.3	21.9 ± 2.4	22.6 ± 2.6	20.2 ± 2.2
AoA area (mm ²)	449.8 ± 86.2	379.6 ± 82.2	404.2 ± 89.8	444.9 ± 84.6
Aortic valve calcifications (grade 1–4)	2.9 ± 0.8	—	—	3.4 ± 0.7
Length of the left coronary leaflet (mm)	13.9 ± 2.2	—	—	14 ± 2.3
Length of the right coronary leaflet (mm)	13.3 ± 2.1	—	—	13.3 ± 2.3
Length of the noncoronary leaflet (mm)	13.4 ± 1.8	—	—	13.4 ± 2.0
AoA-to-left coronary ostium distance (mm)	16.1 ± 2.8	—	—	16.2 ± 3.1
AoA-to-right coronary ostium distance (mm)	16.1 ± 4.4	—	—	16.0 ± 4.3

Intraoperative 2D and 3D transoesophageal echocardiographic predictors of aortic regurgitation after transcatheter aortic valve implantation

Paola Gripari,¹ See Hooi Ewe,² Laura Fusini,¹ Manuela Muratori,¹ Arnold C T Ng,³ Claudia Cefalù,¹ Victoria Delgado,² Martin J Schalij,² Jeroen J Bax,² Nina Ajmone Marsan,² Gloria Tamborini,¹ Mauro Pepi¹


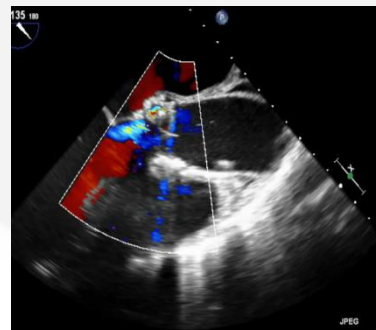
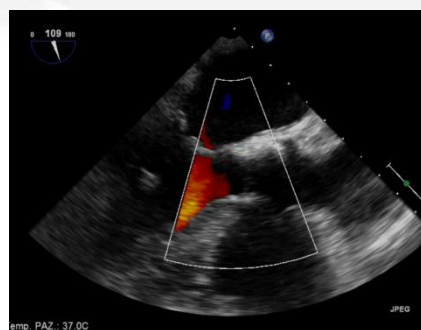


1




Commissural calcifications

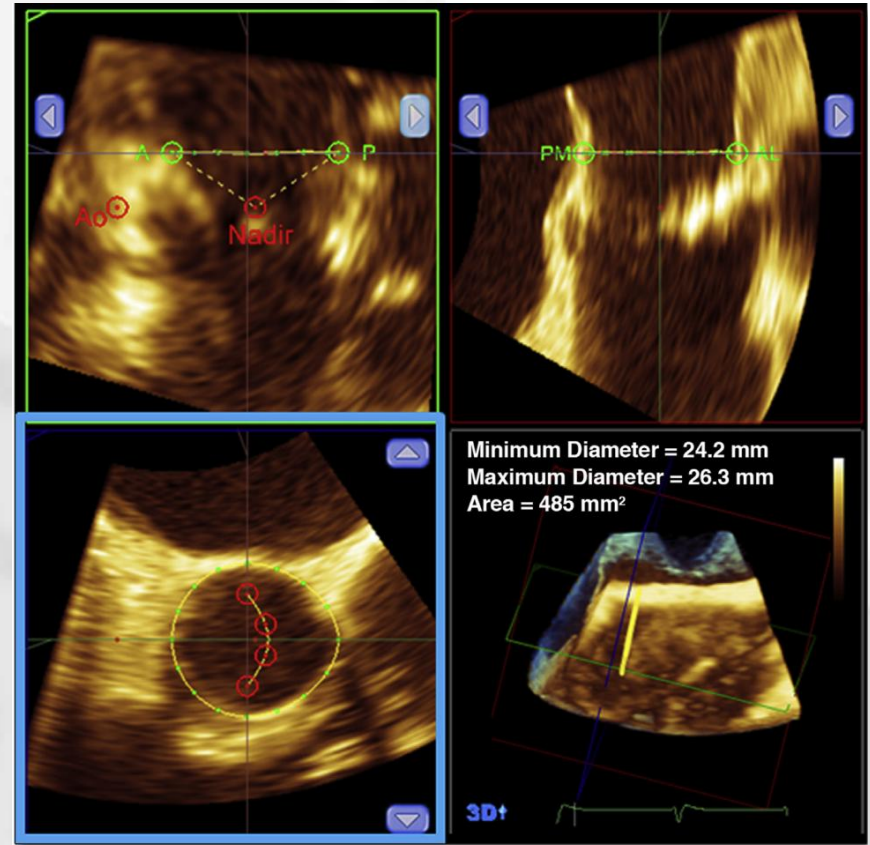
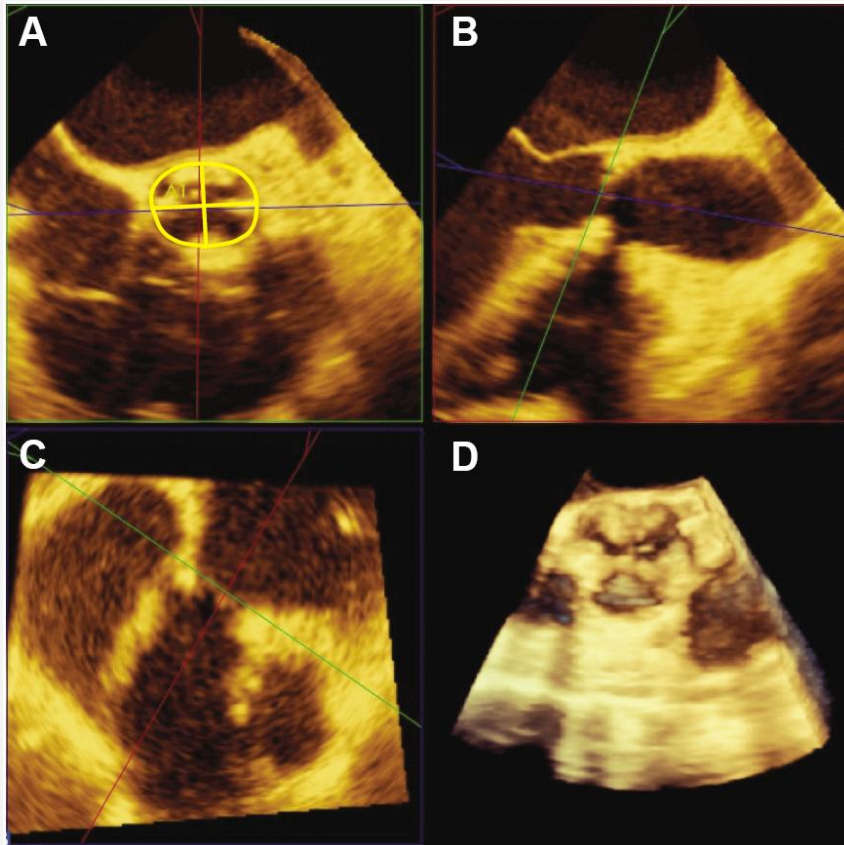
Area cover index



3DTEE e coronarie




Centro Cardiologico
Monzino



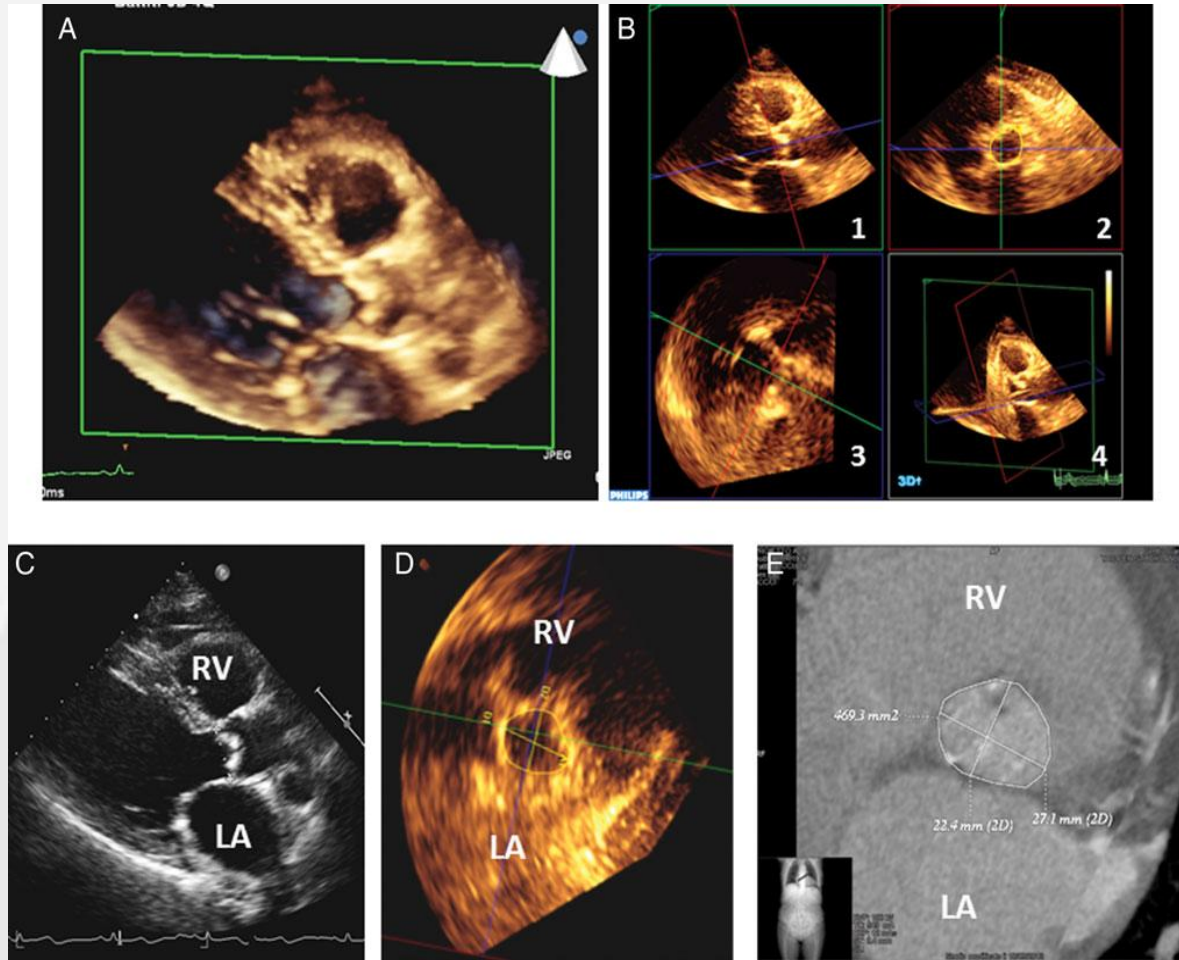
Tamborini G. et al. Jacc Imag. 2012

Hahn RT et al. JASE 2013

3DTTE e coronarie



Centro Cardiologico
Monzino



Procedura eco-guidata

- ✓ *Valutazione preoperatoria*
- ✓ *Monitoraggio intraoperatorio*
- ✓ *Valutazione del risultato*

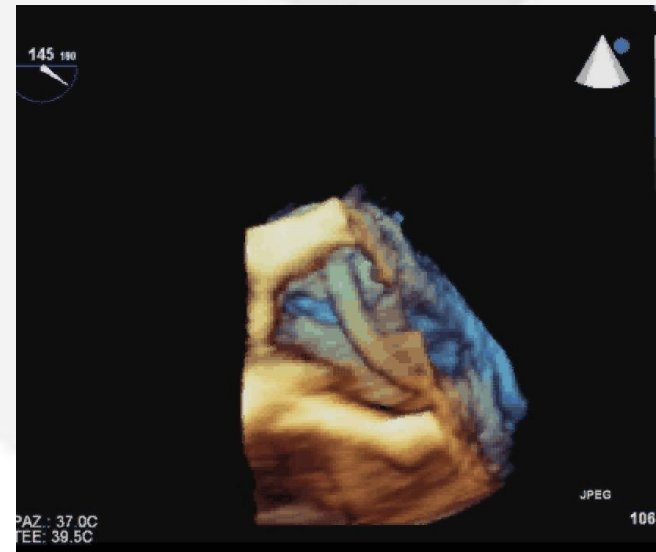
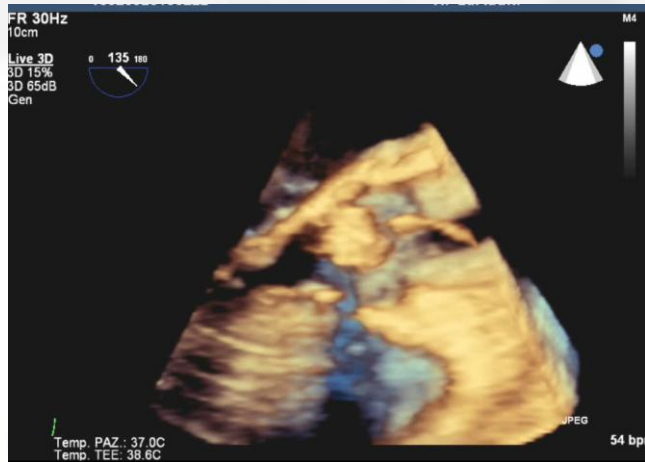
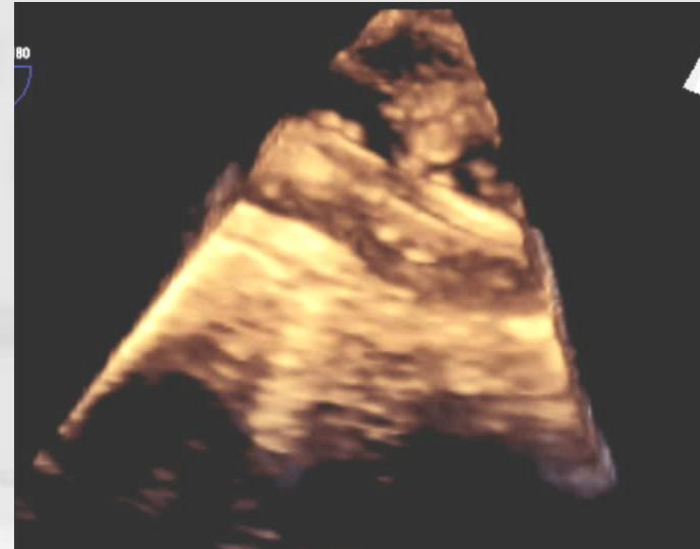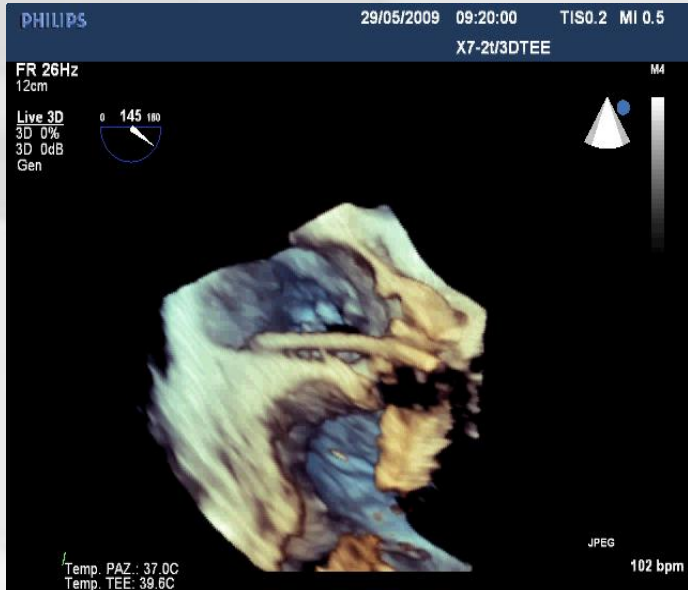
Procedura eco-guidata

✓ *Valutazione preoperatoria*

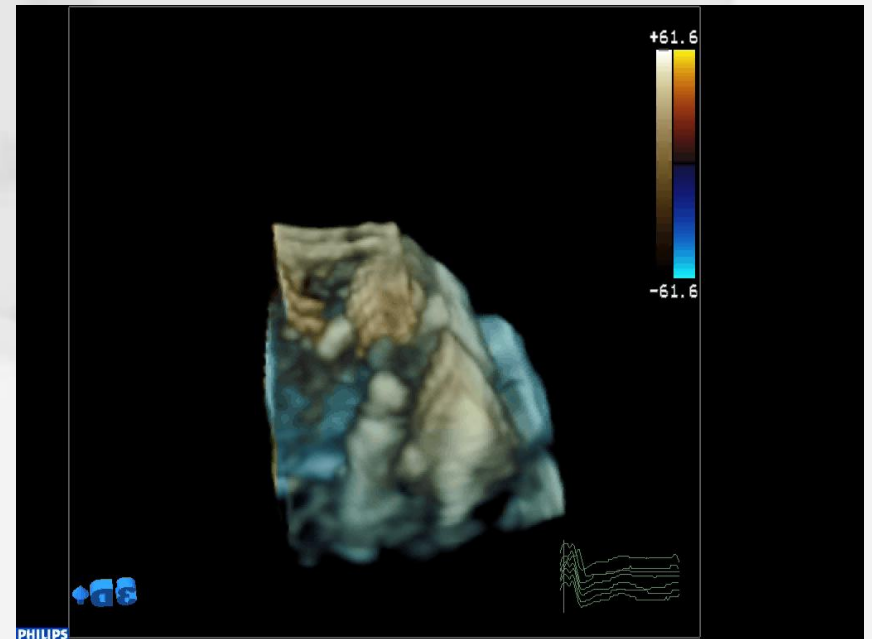
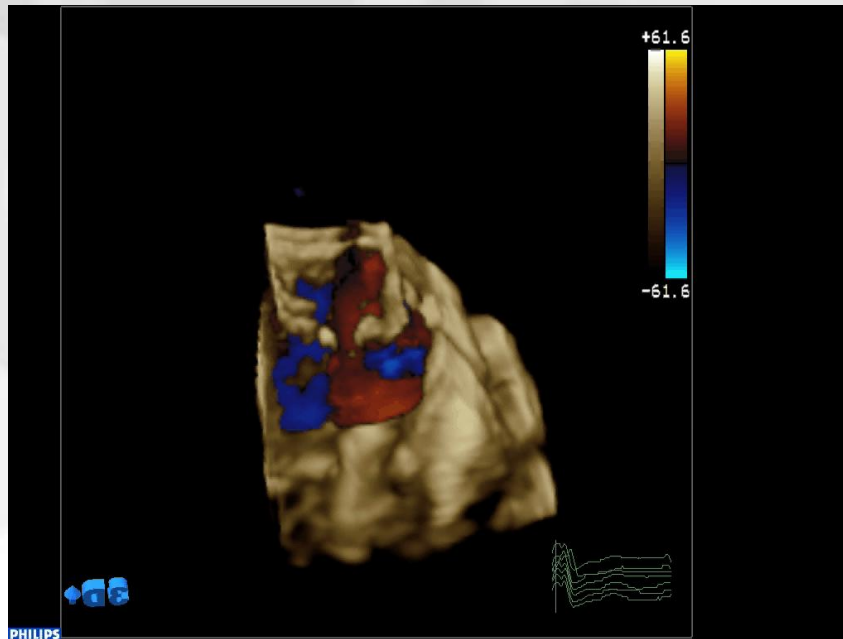
✓ *Monitoraggio intraoperatorio*

✓ *Valutazione del risultato*

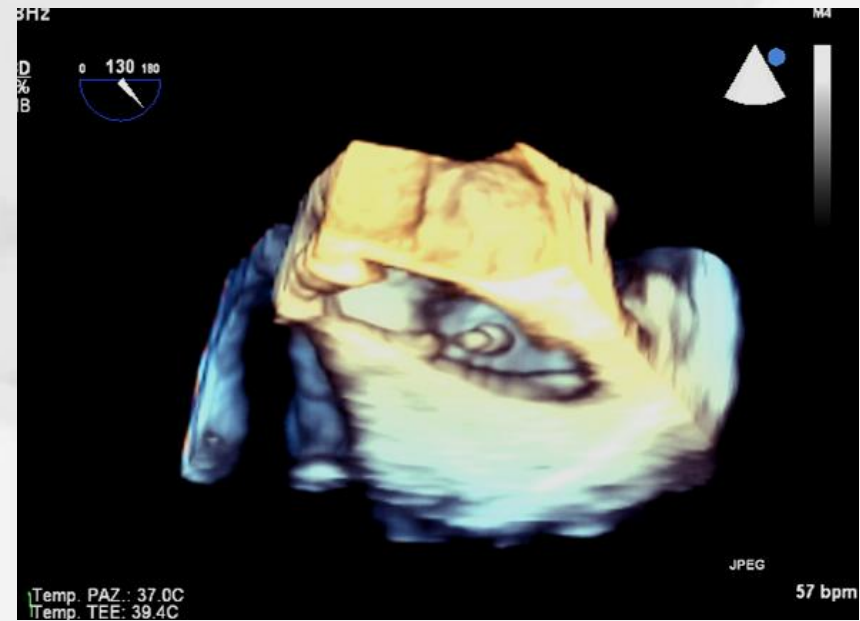
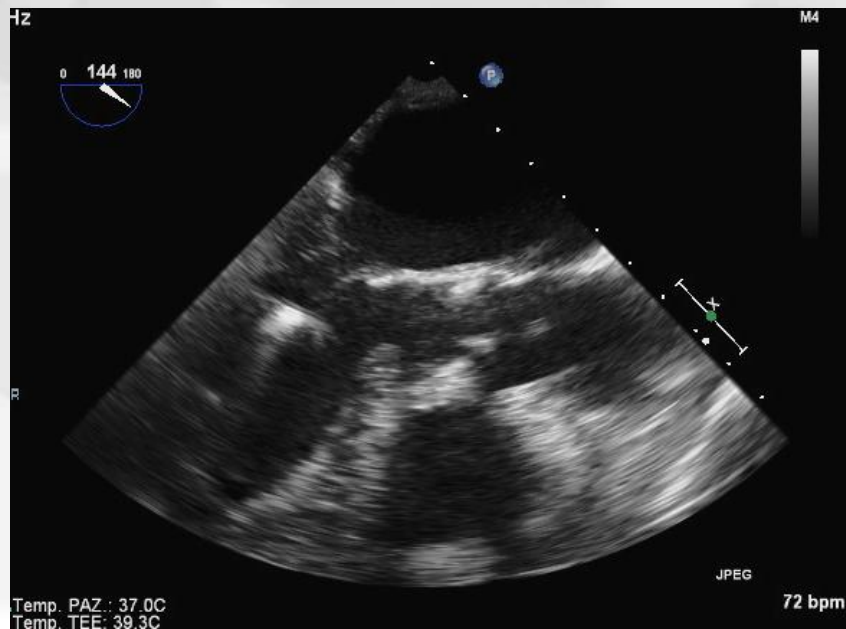
Monitoraggio procedurale



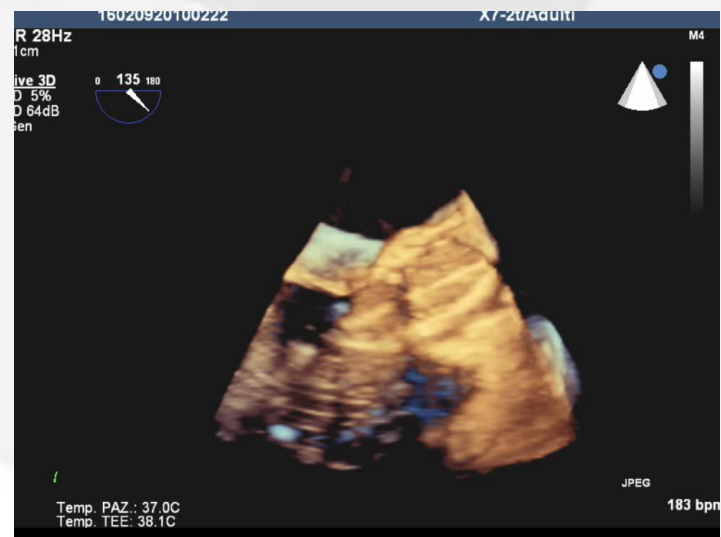
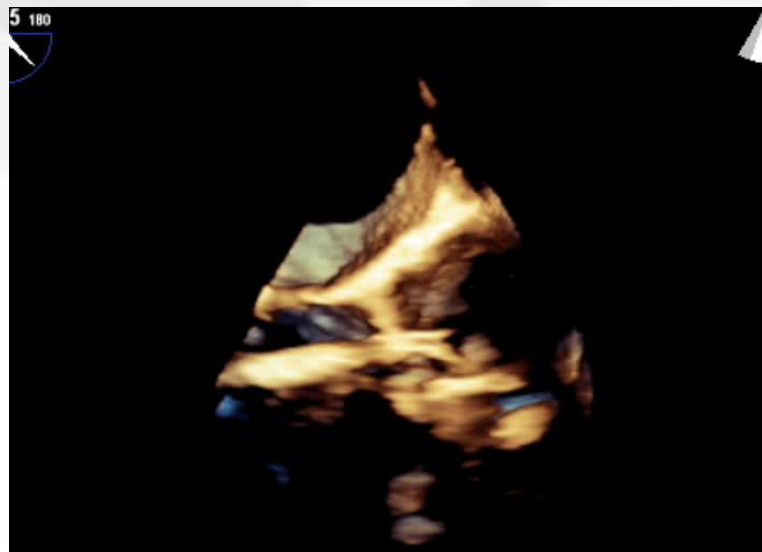
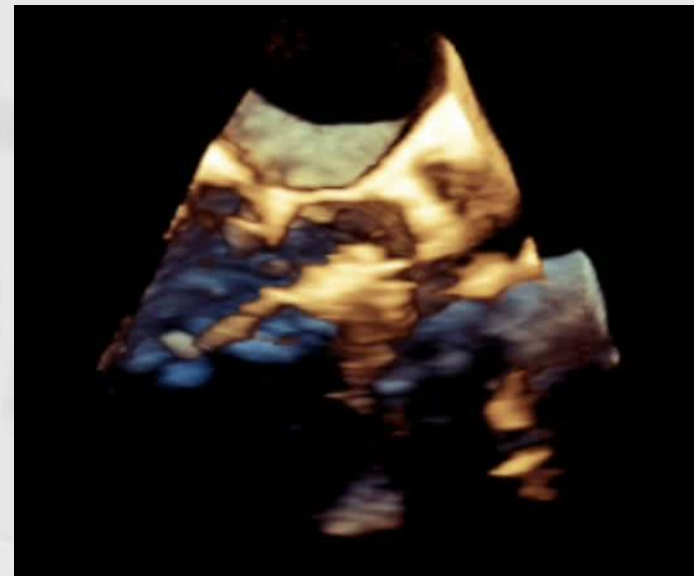
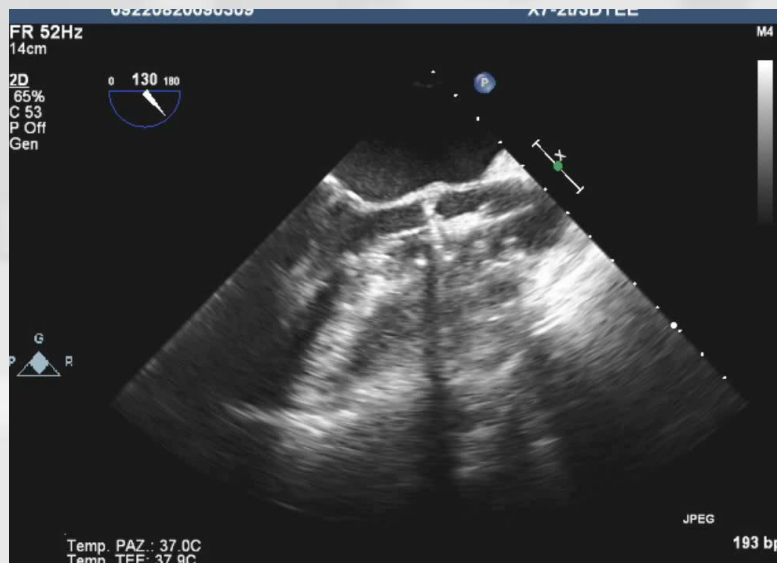
Rigurgito mitralico funzionale



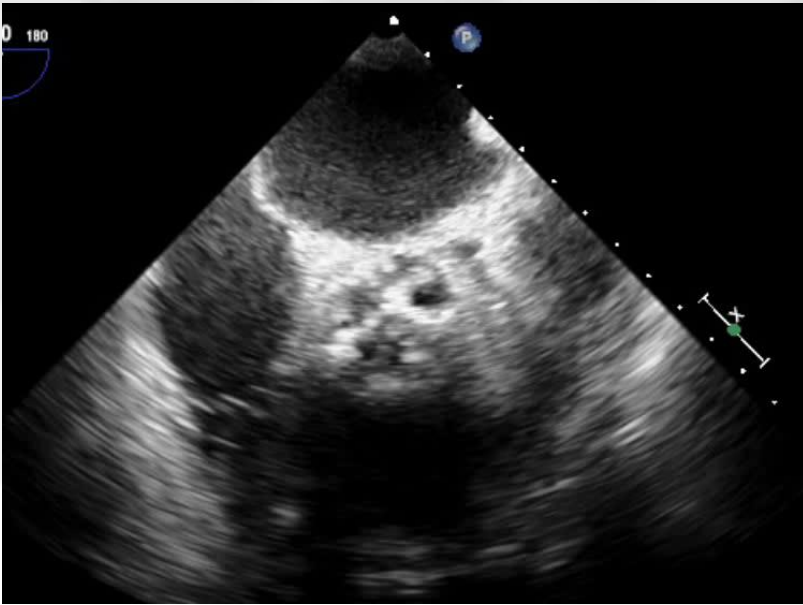
Trombo mobile sul catetere



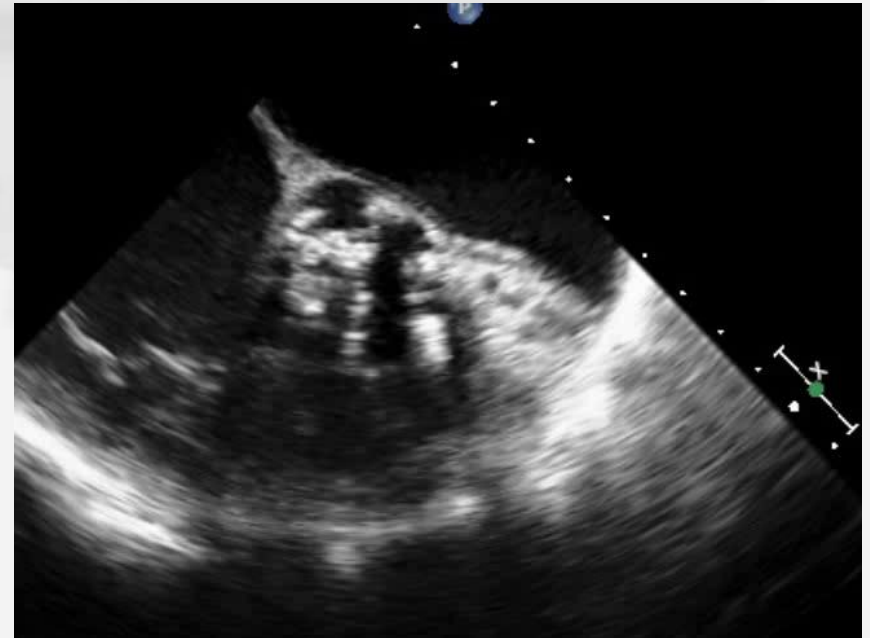
Ballooning della valvola



Ballooning della valvola

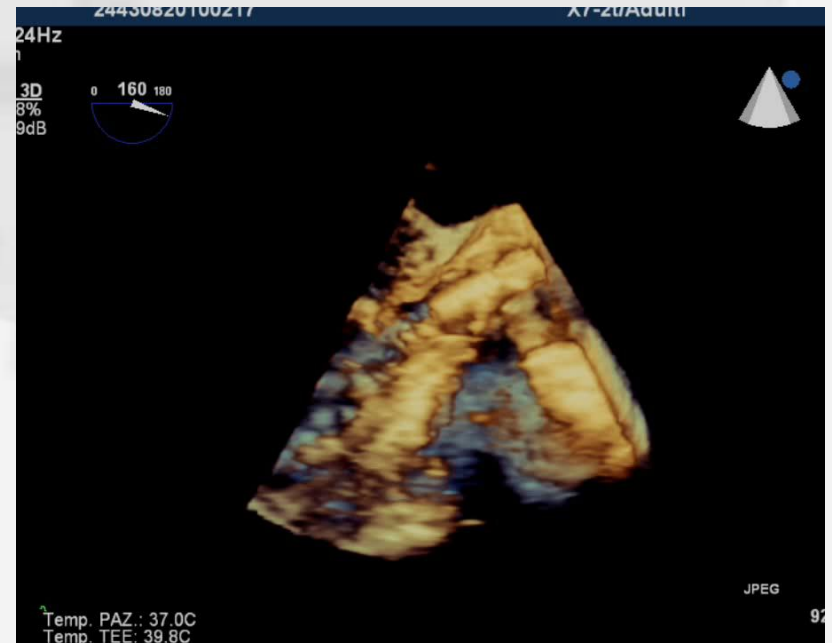
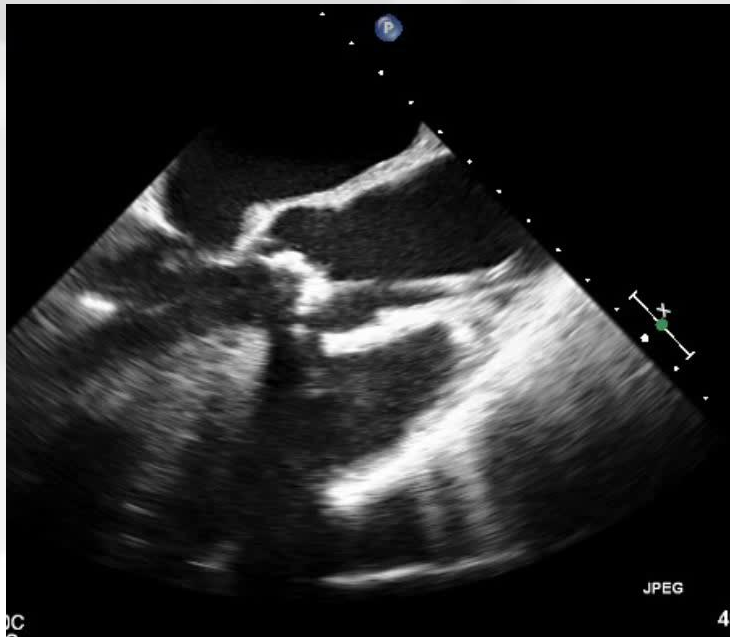


Pre-balloon

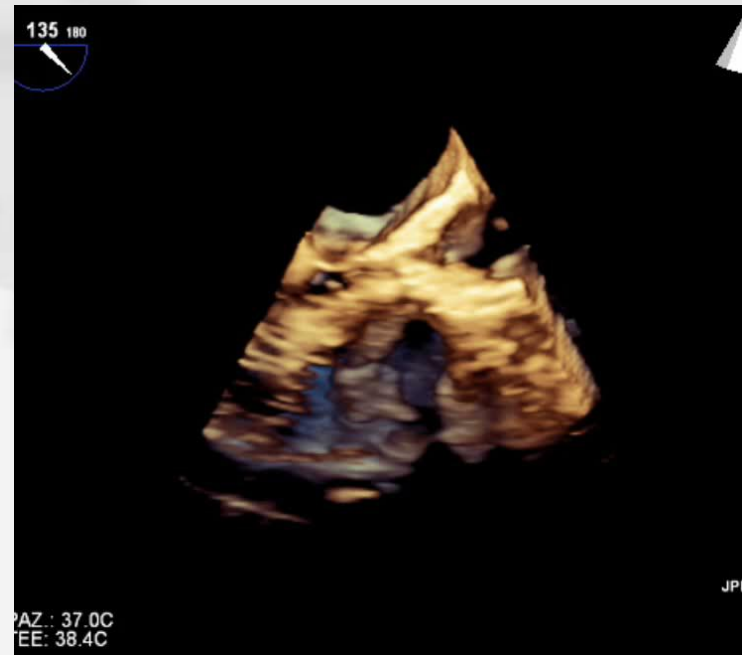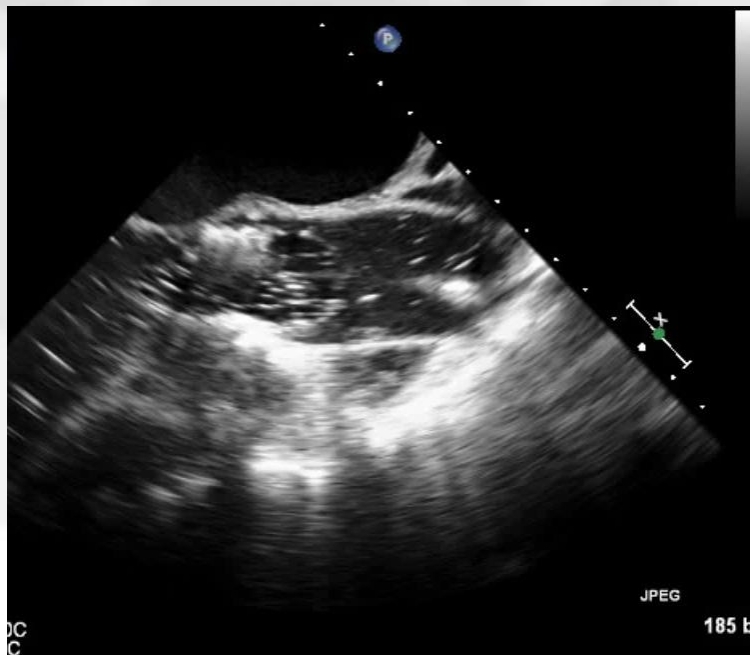


Post-balloon

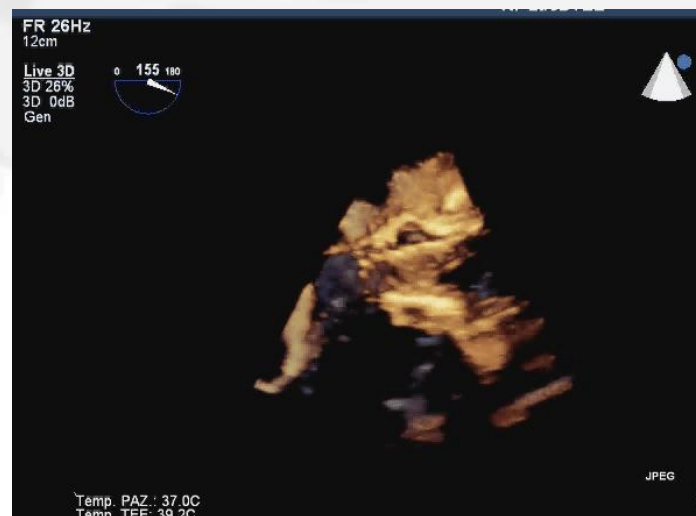
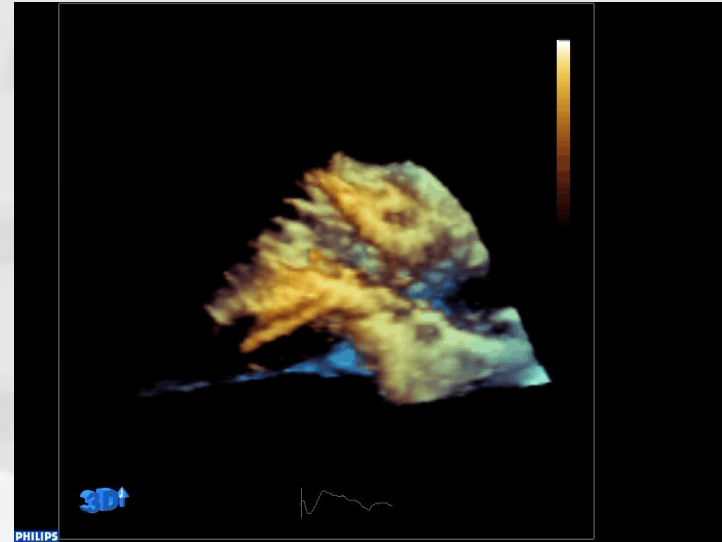
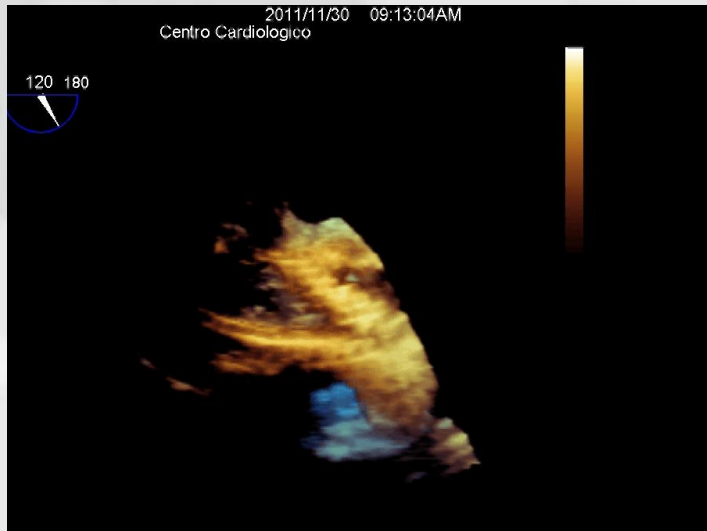
Posizionamento ed apertura della protesi



Posizionamento ed apertura della protesi

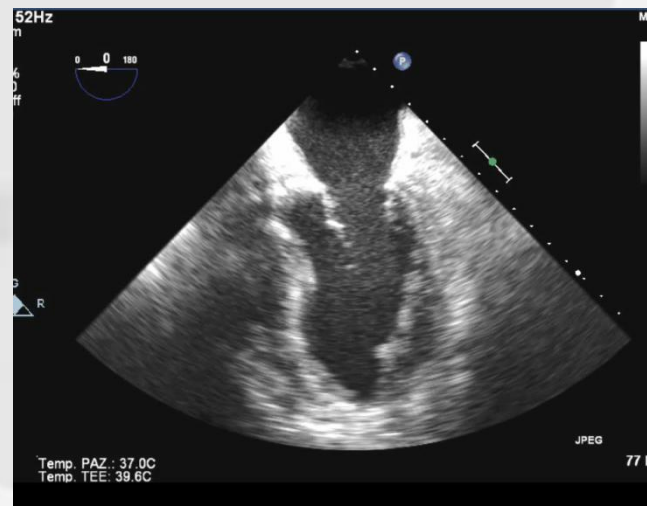
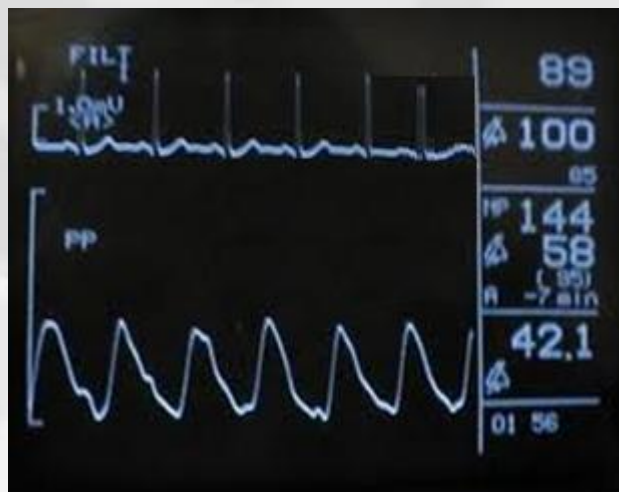



Posizionamento ed apertura della protesi

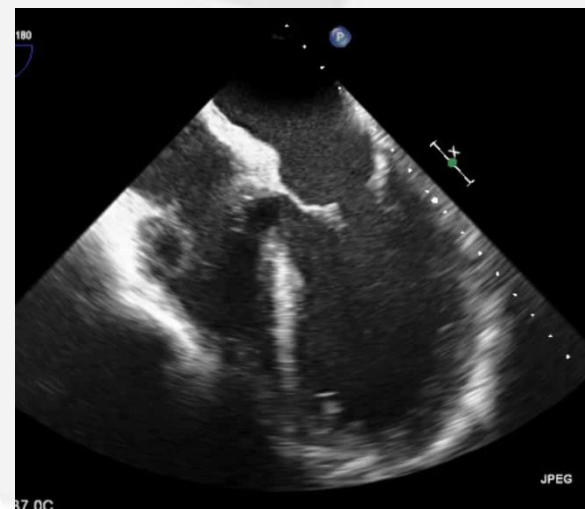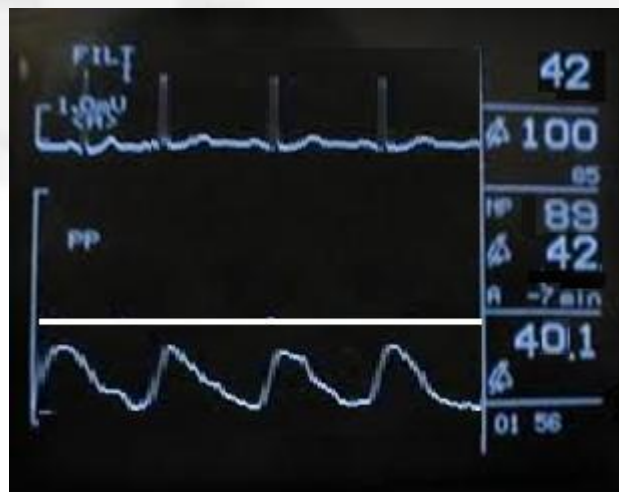


MONITORAGGIO DEGLI IMPREVISTI

Pre

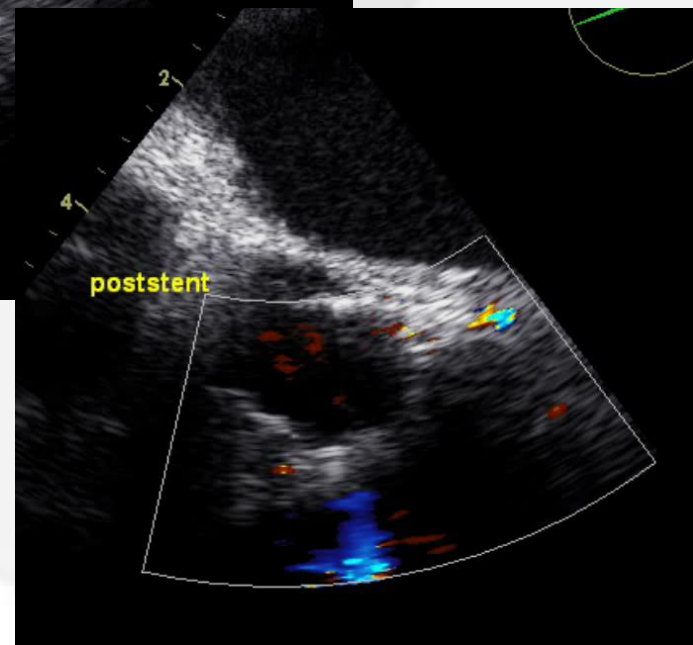
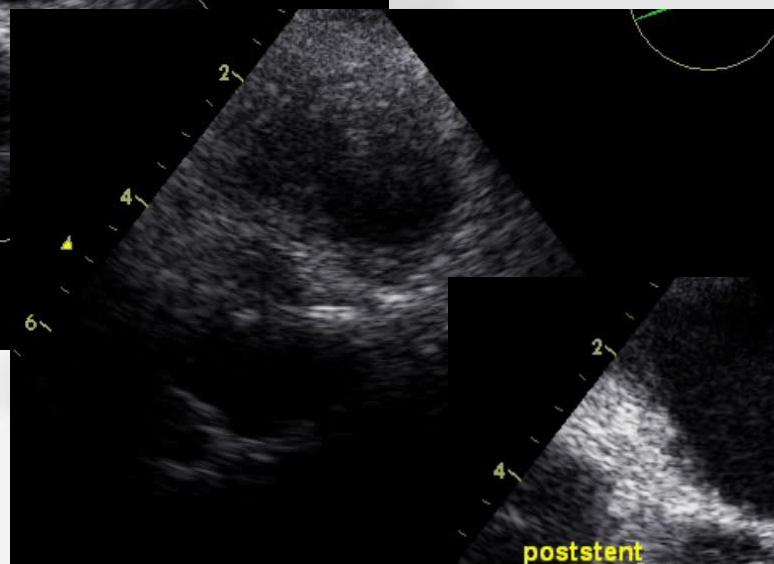
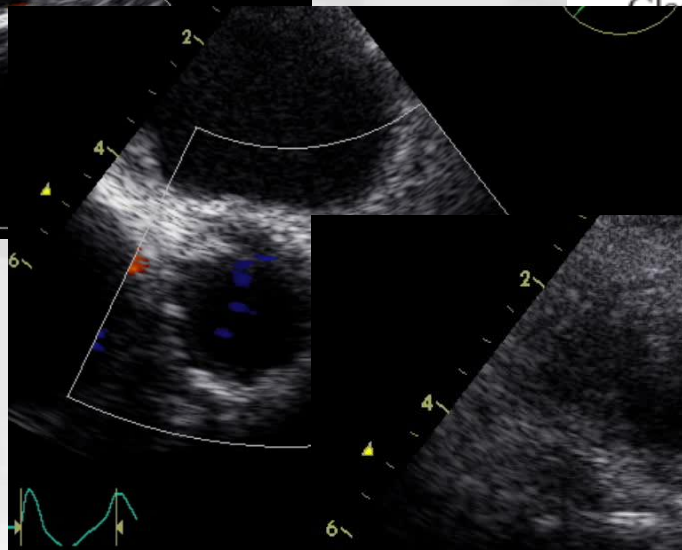
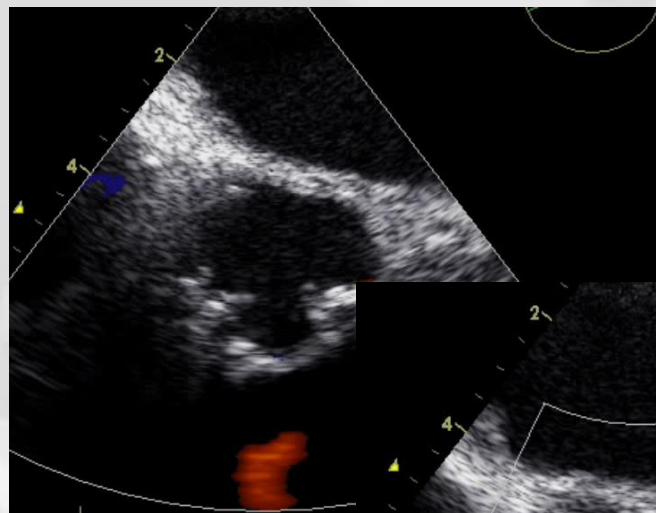


Post

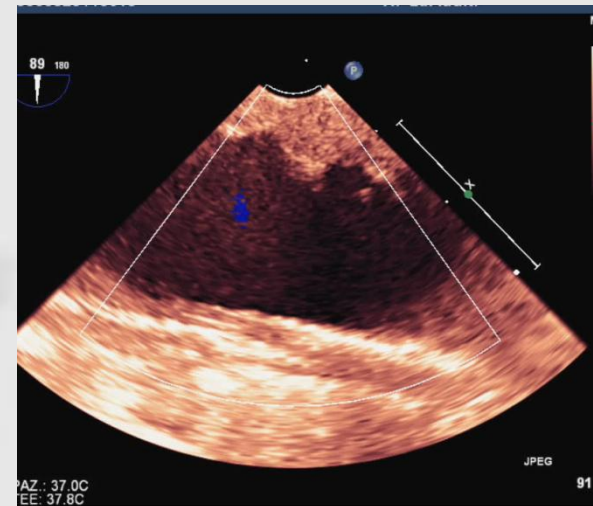
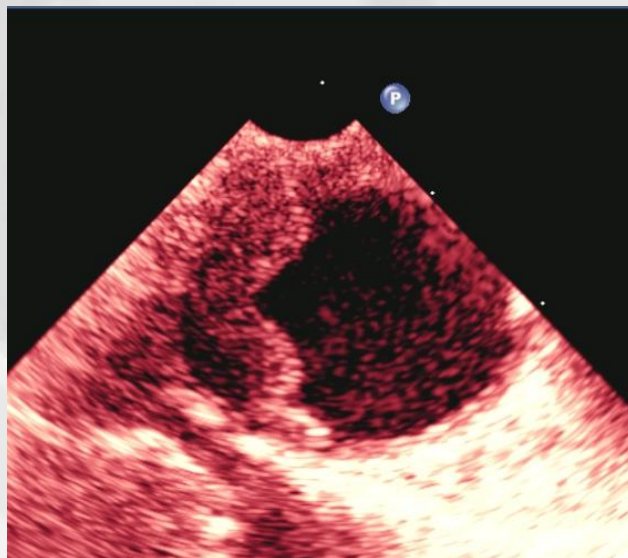


Left Main Coronary Artery Occlusion After Percutaneous Aortic Valve Implantation

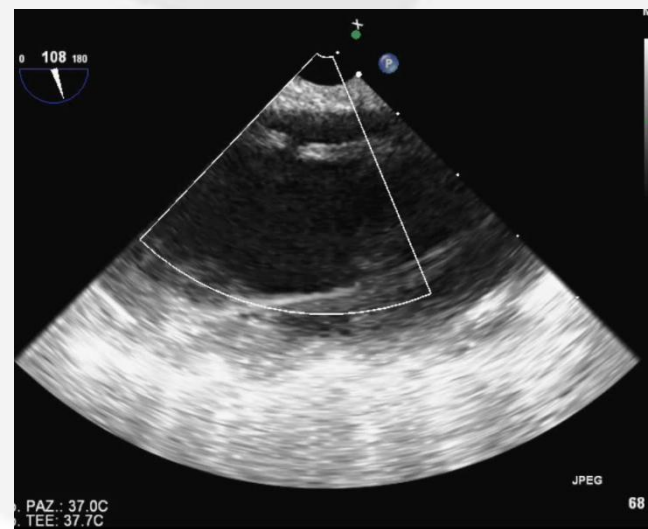
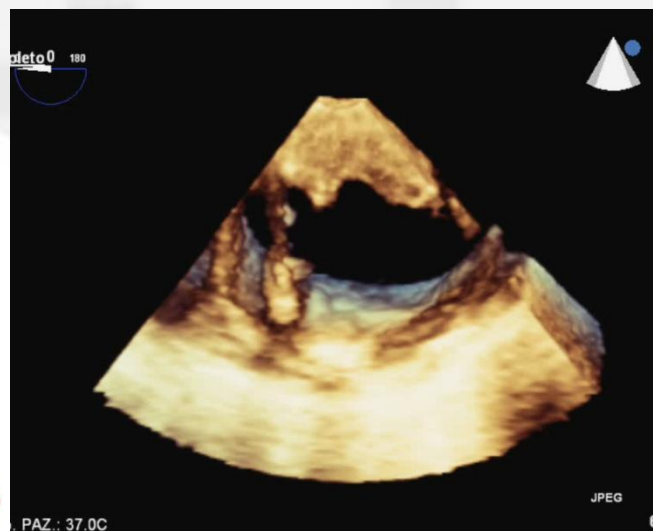
Antonio L. Bartorelli, MD, FESC, FACC,
Daniele Andreini, MD, Erminio Sisillo, MD,
Claudia Tamborini, MD, Melissa Fusari, MD, and
Giovanni Biglioli, MD

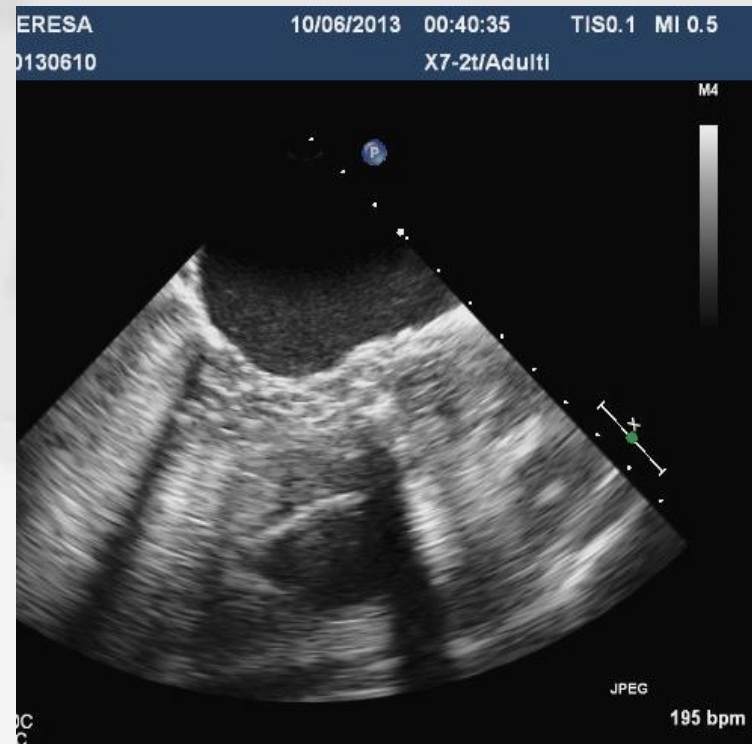
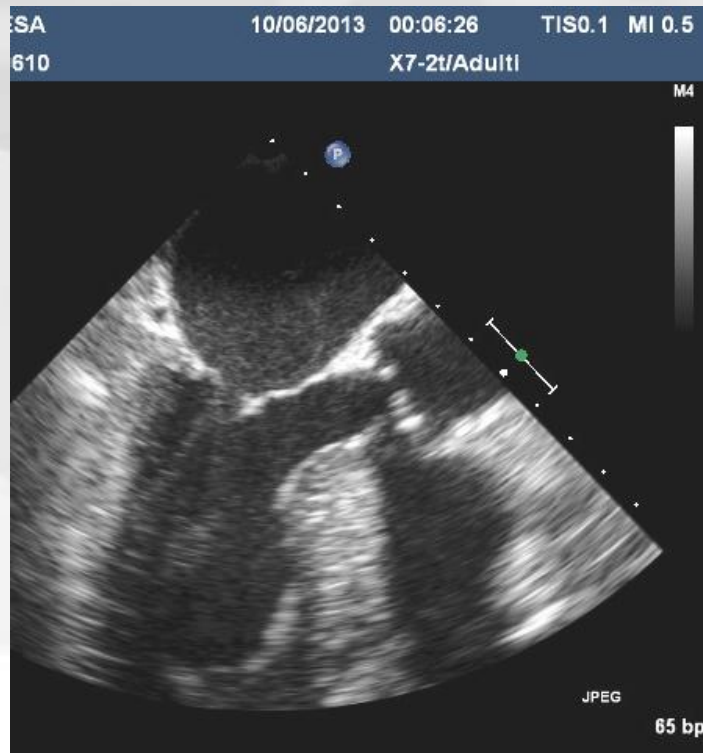
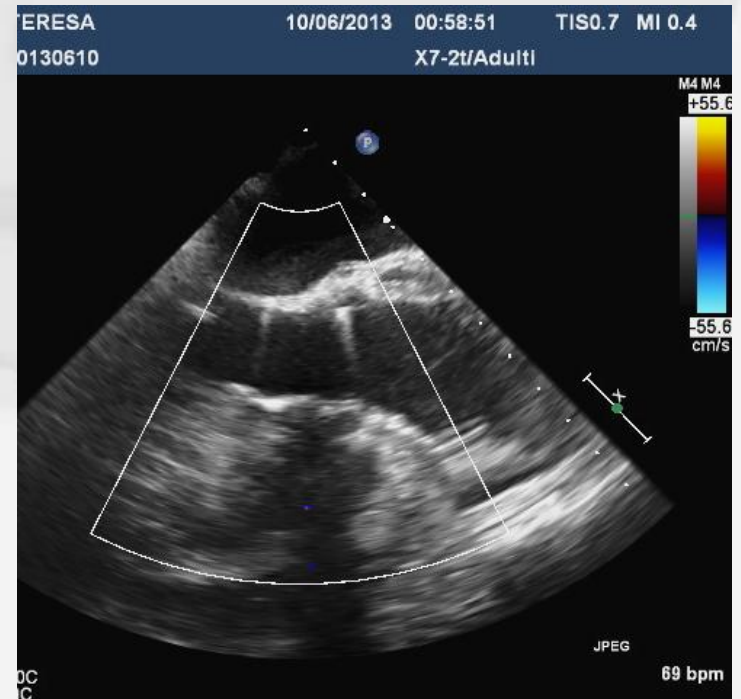
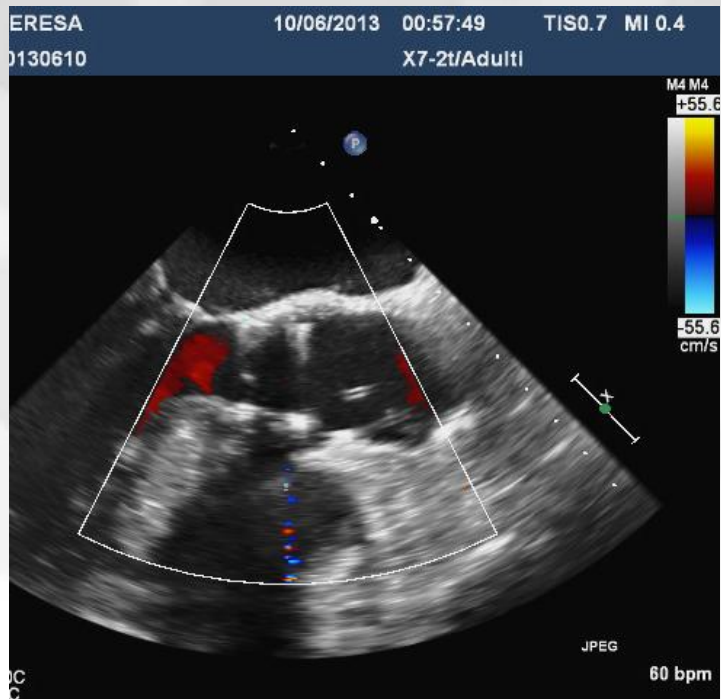
Preop

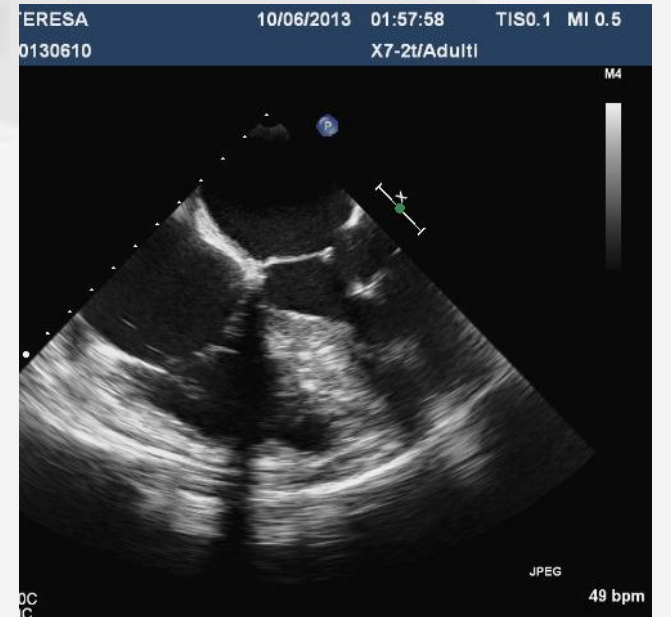
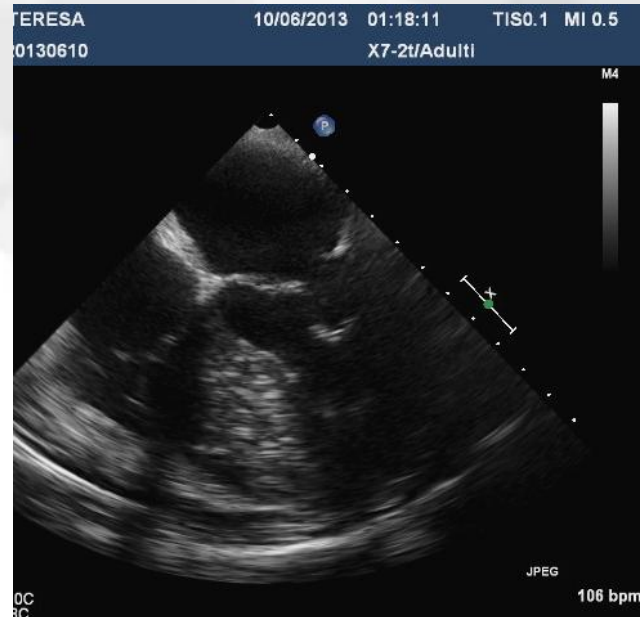
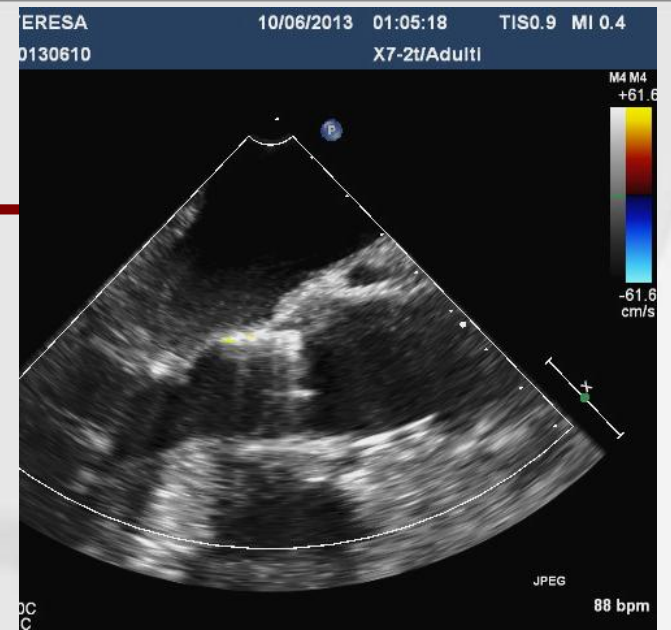
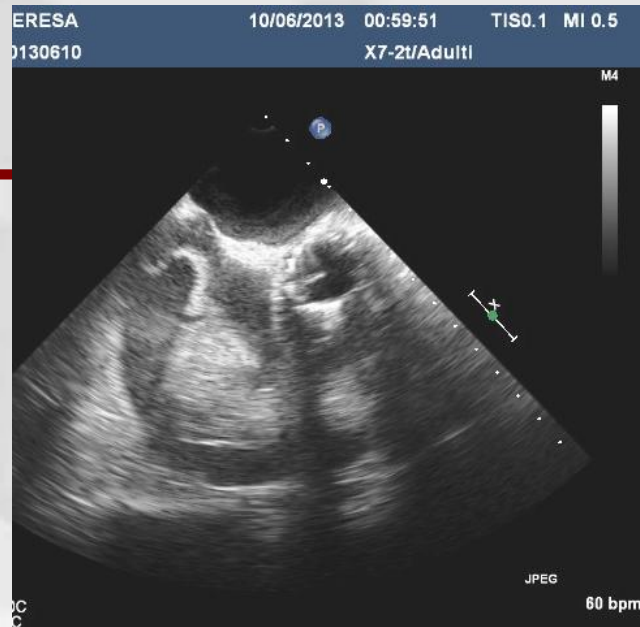

Postop









Procedura eco-guidata

✓ *Valutazione preoperatoria*

✓ *Monitoraggio intraoperatorio*

✓ *Valutazione del risultato*

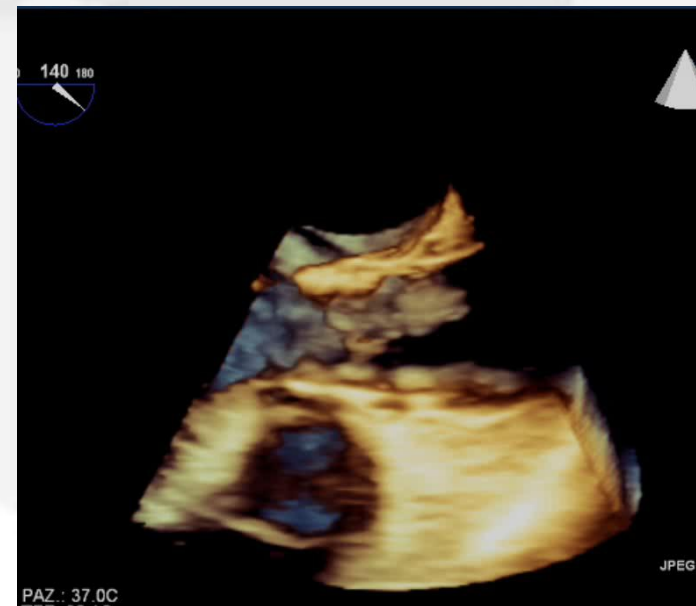
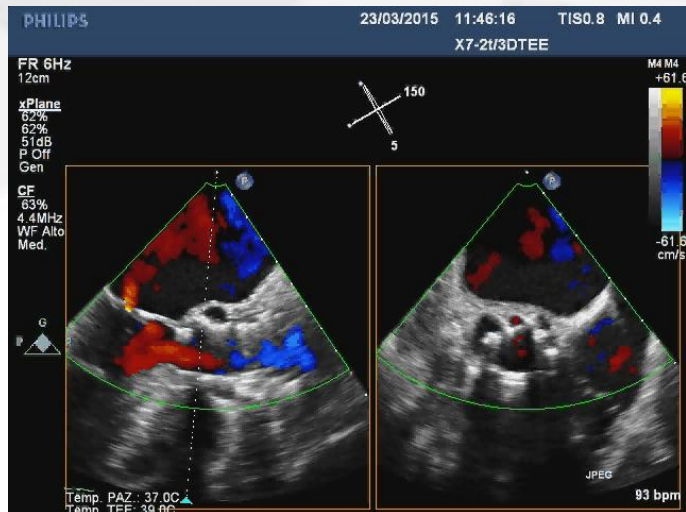
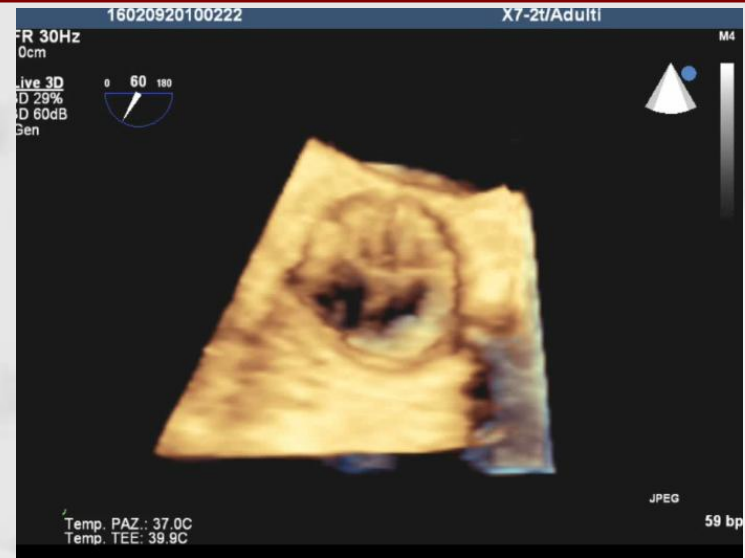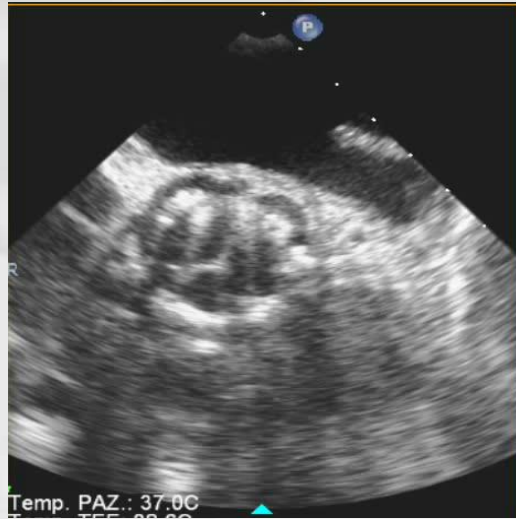Procedura eco-guidata

✓ *Valutazione preoperatoria*

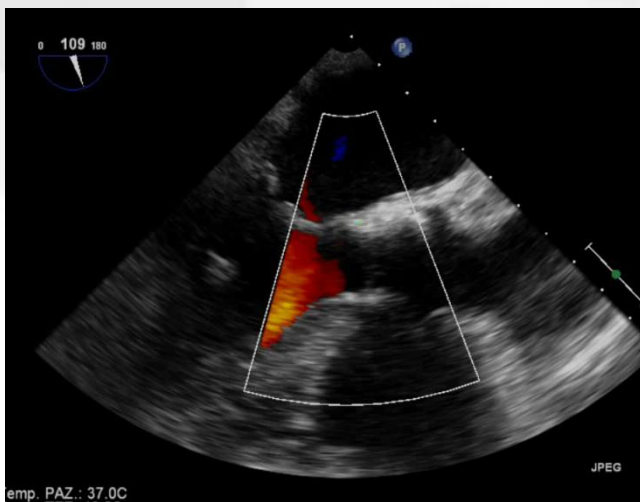
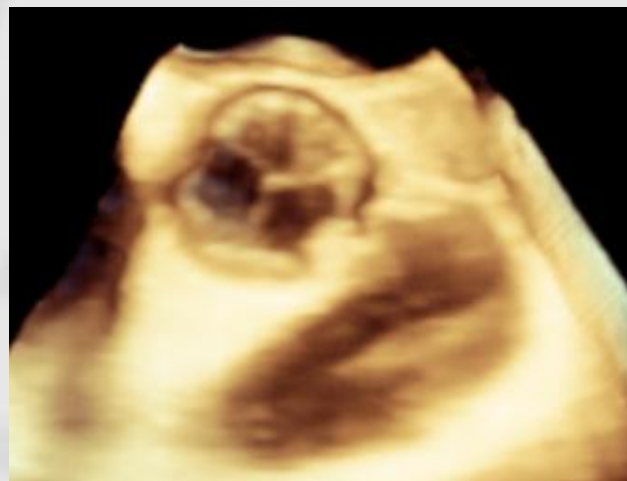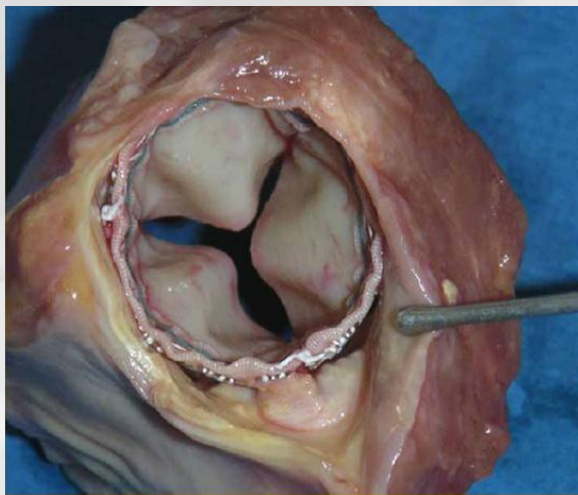
✓ *Monitoraggio intraoperatorio*

✓ *Valutazione del risultato*

Morfologia della protesi dopo l'impianto



Valòutazione del Leak paraprotésico




Trivial or mild regurgitation ≈ 80

Mild to moderate $\approx 15\%$

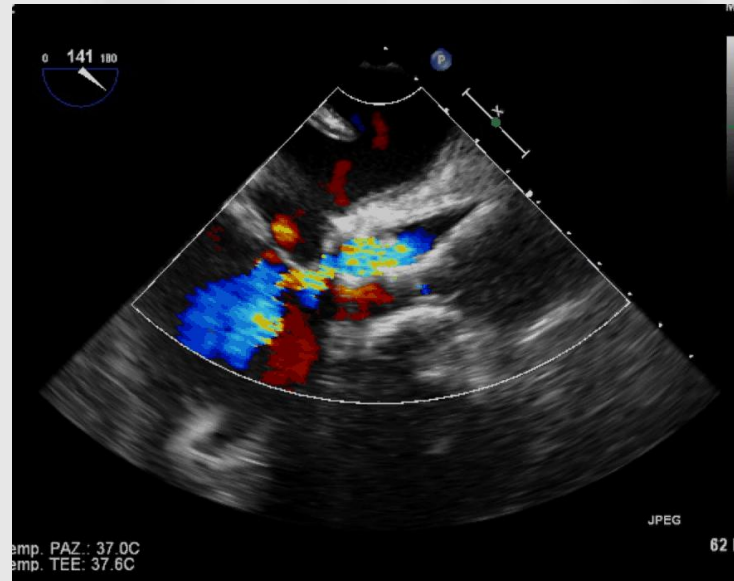
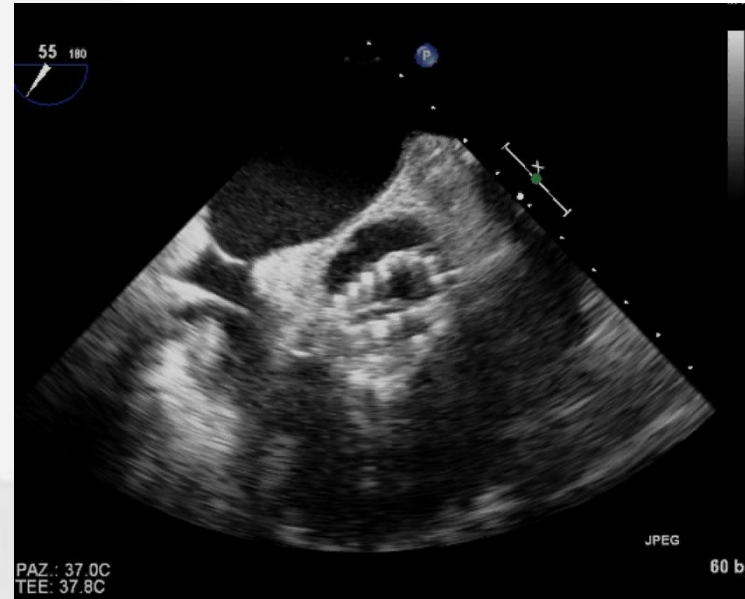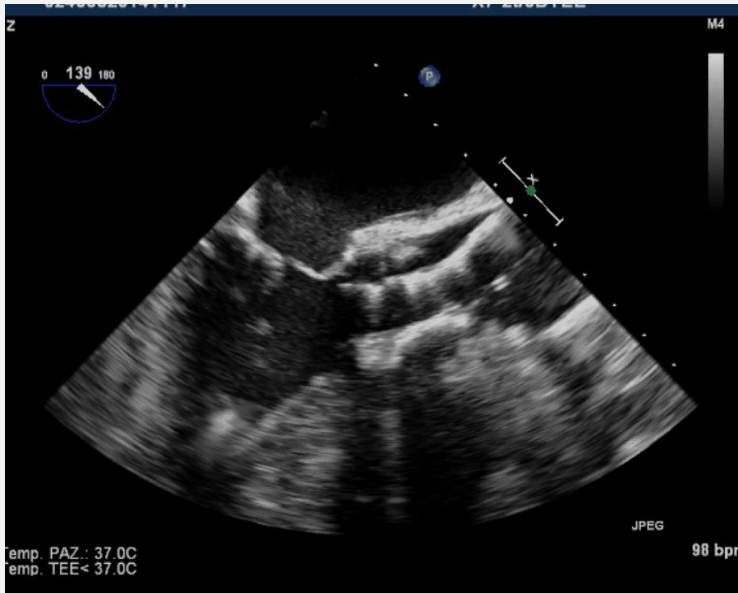
Moderate to severe $\approx 5\%$



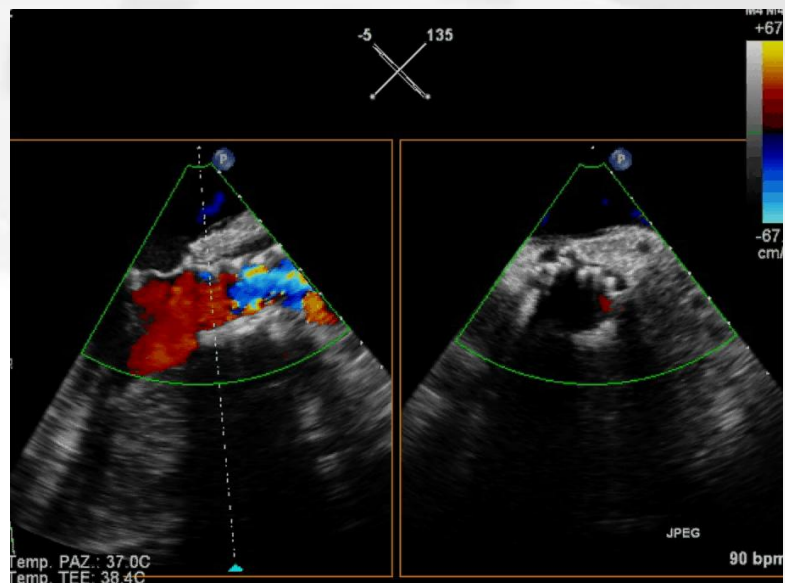
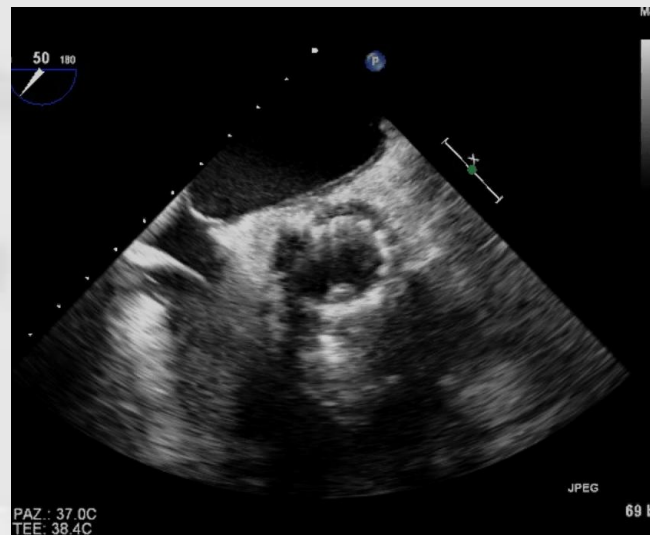
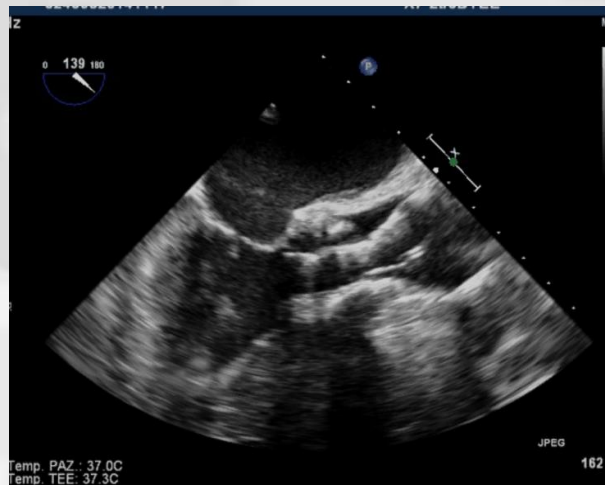
Morfologia della protesi e leak



Centro Cardiologico
Monzino

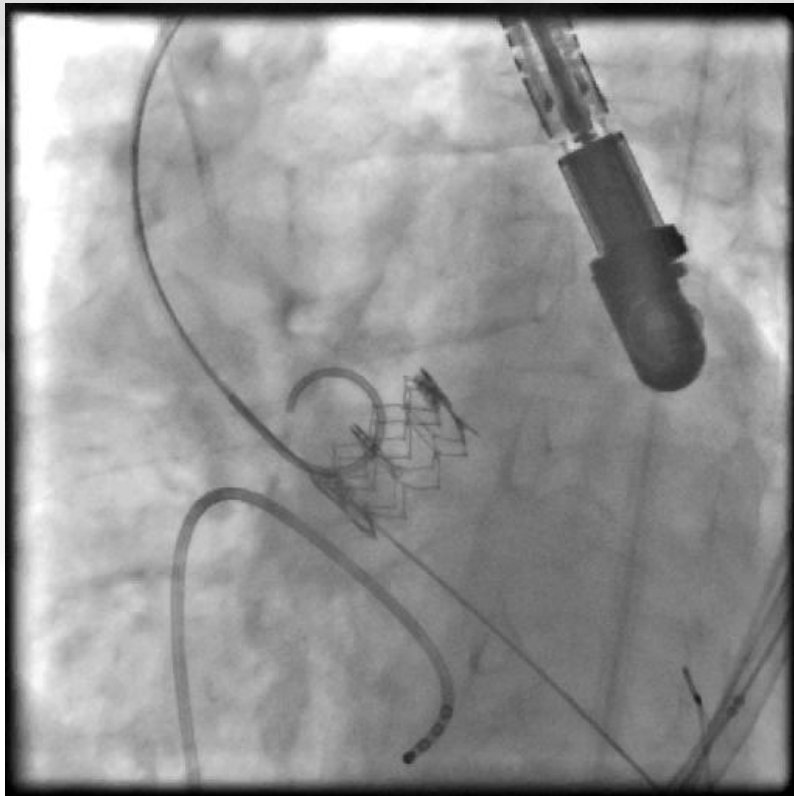


Morfologia della protesi e leak

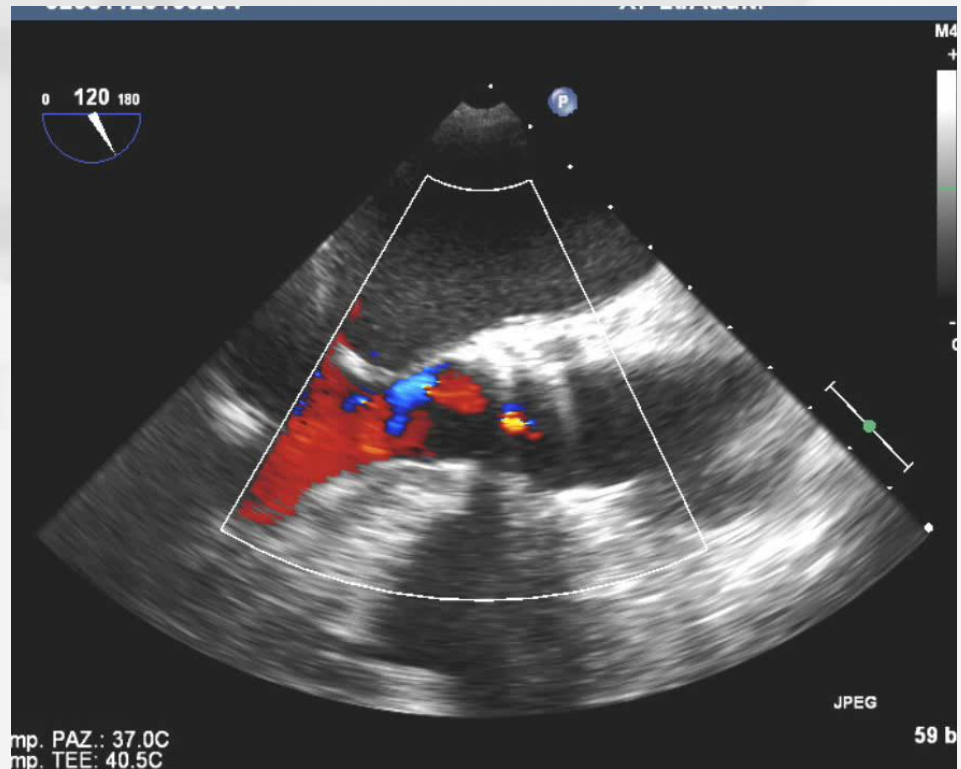


TEE Monitoring: insufficienza para e centroprotesica

- Quanto è il rigurgito?
- Che fare?



Angiografia

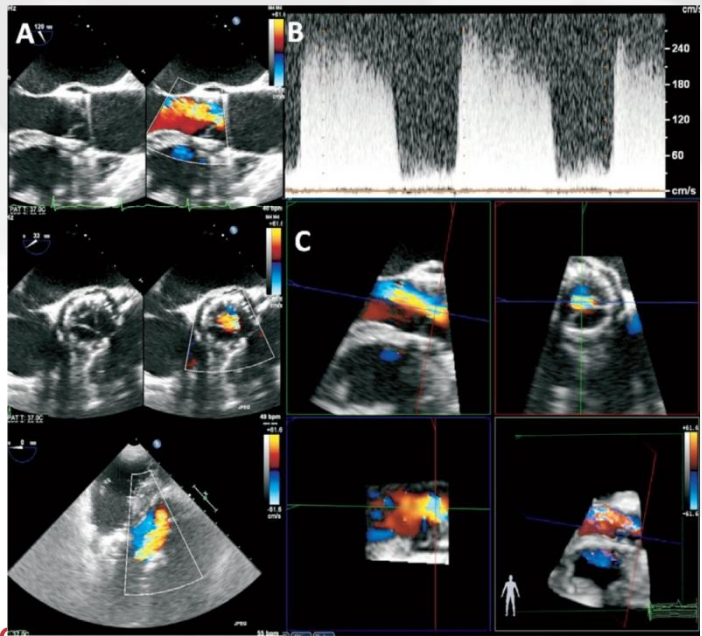


TEE

TEE Monitoring: insufficienza centropotesica

Table 2. Recommended criteria for aortic regurgitation (paravalvular and transvalvular) after transcatheter aortic valve implantation.

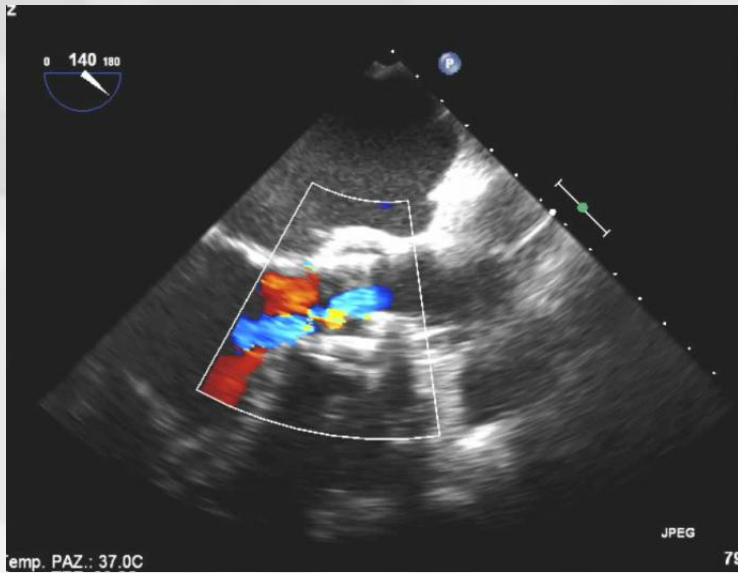
Parameter	Mild	Moderate	Severe
Valve structure and motion	Usually normal	Usually abnormal	Usually abnormal
Left ventricular size	Normal	Normal/mildly dilated	Dilated
Doppler parameters (qualitative or semi-quantitative)			
Jet width in central jets (%LVOT): colour ^a	≤25%	26-64%	≥65%
Jet density: continuous-wave	Incomplete or faint	Dense	Dense
Jet deceleration rate (PHT, ms): continuous-wave ^b	Slow (>500 ms)	Variable (200-500 ms)	Steep (<200 ms)
LVOT versus pulmonary flow: pulsed-wave	Slightly increased	Intermediate	Greatly increased
Diastolic flow reversal in descending aorta: pulsed-wave	Absent or brief early diastolic	Intermediate	Prominent/holodiastolic



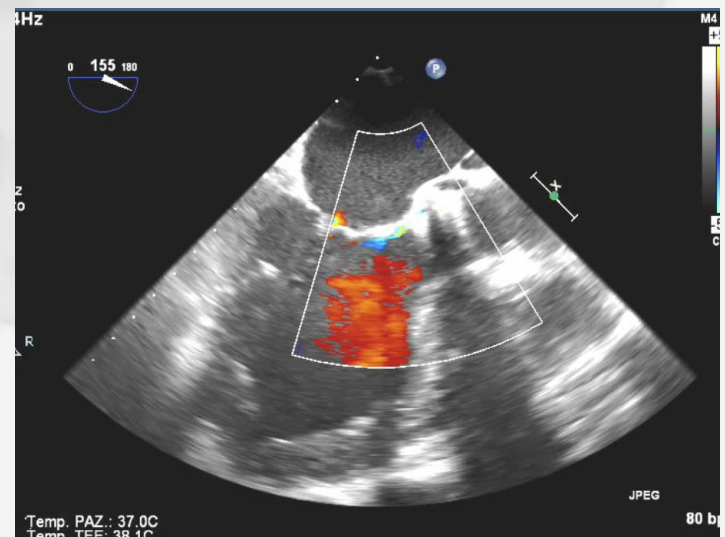
Imaging and quantification of AR after TAVI

See Hooi Ewe, Victoria Delgado, Jeroen J. Bax. EuroIntervention 2012

TEE Monitoring: insufficienza centropotesica



Post TAVI



Post valve in valve

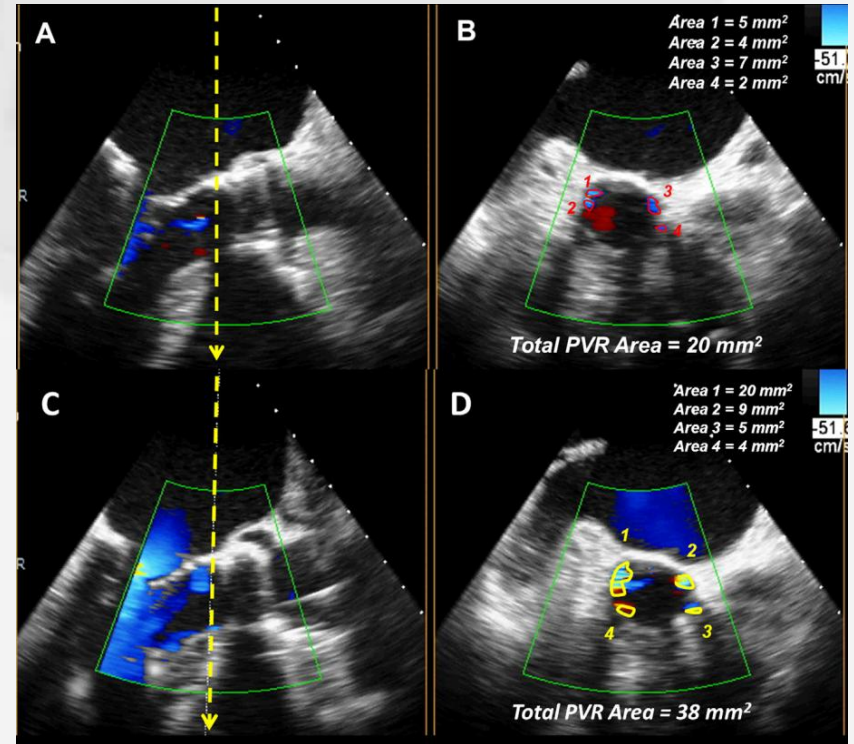
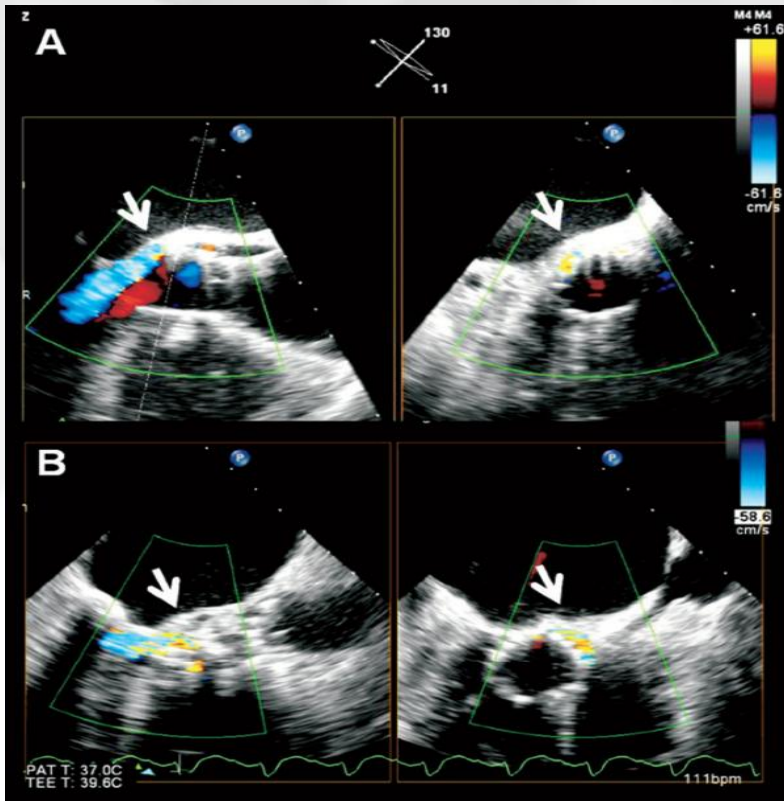


TEE Monitoring: insufficienza paraprotetica

Circumferential extent (%)

- Mild <10 %
- Intermediate 10-20 %
- Severe >20 %

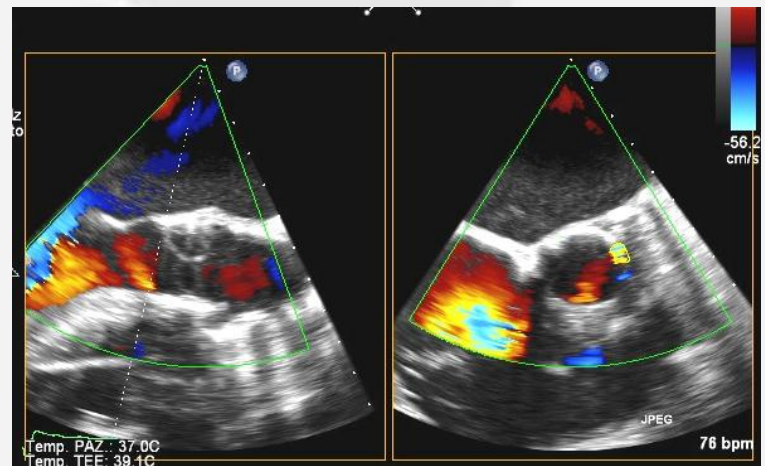
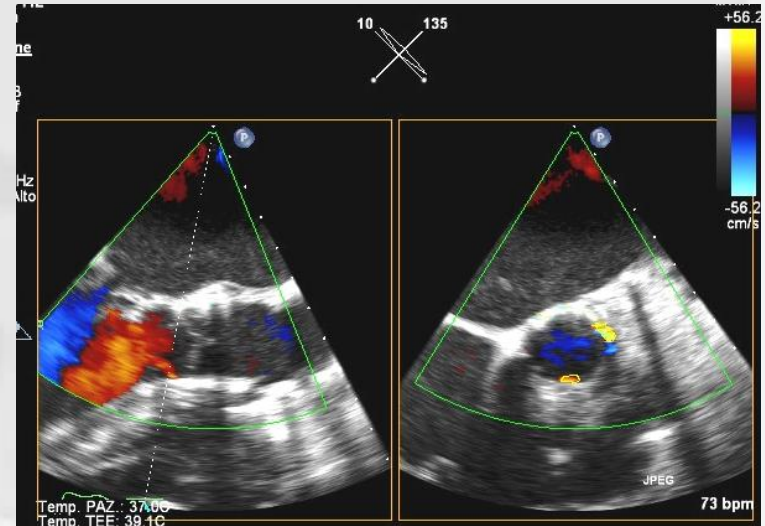
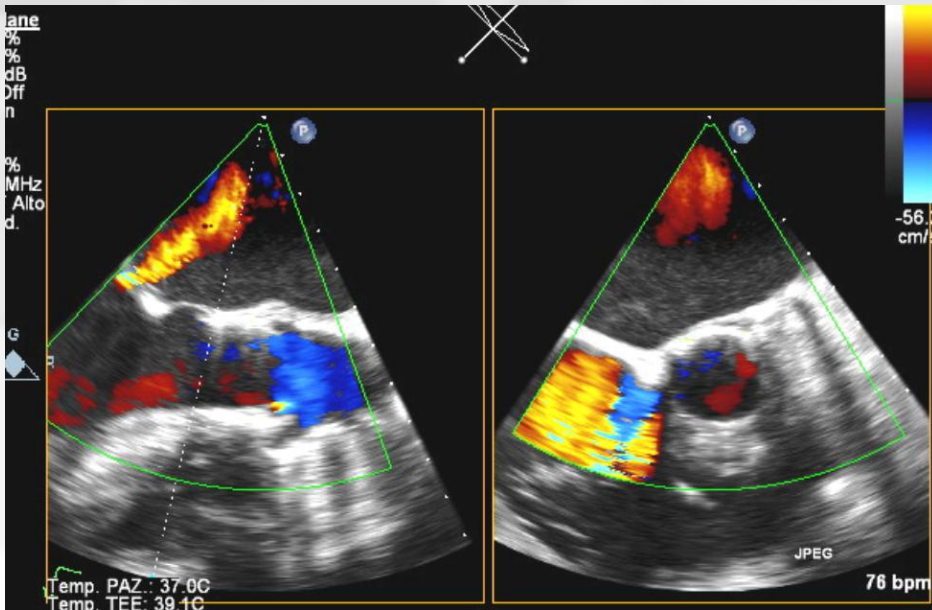
a PVR area cutoff of >29 mm² was chosen to indicate more than mild PVR (the mean + 1 SD for no post-dilatation).



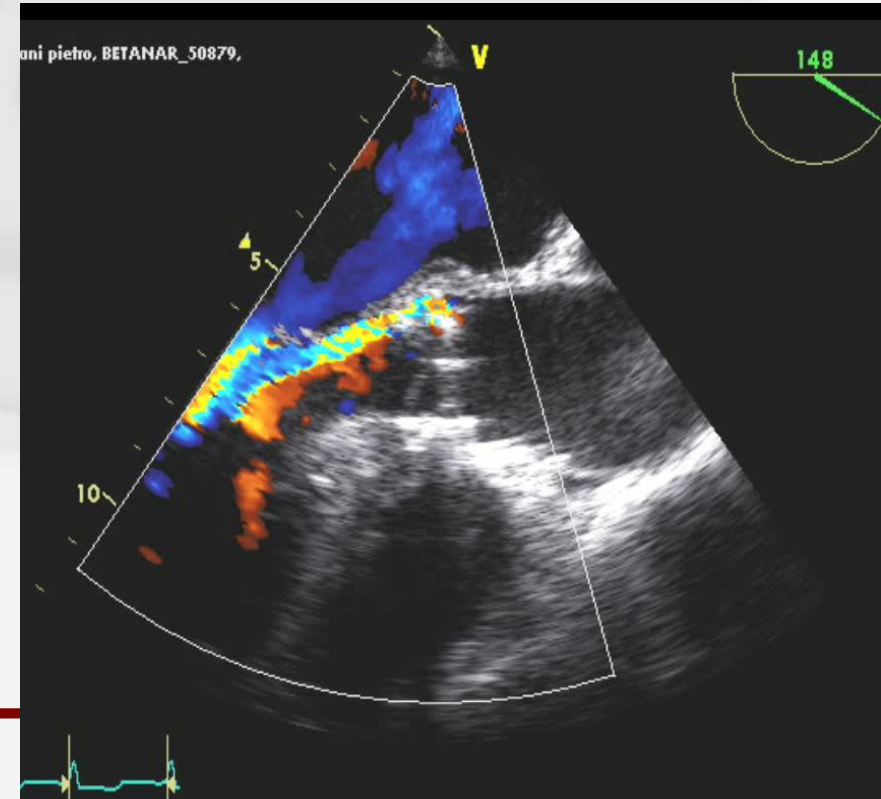
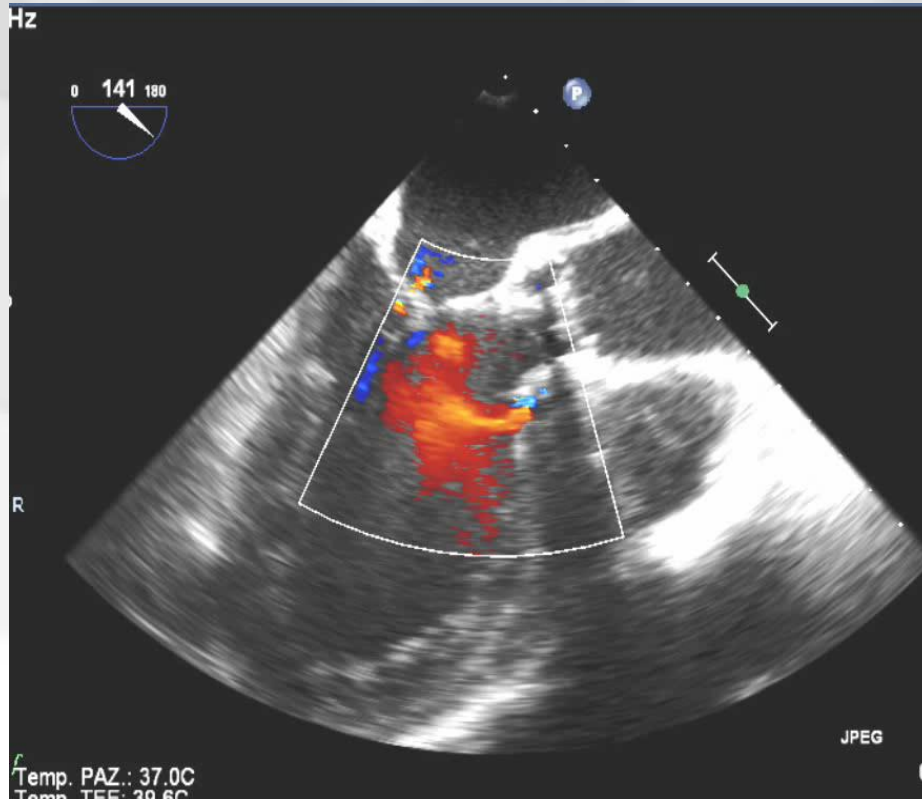
Hahn R et al. Jase 2013

TEE Monitoring: insufficienza paraprotetica

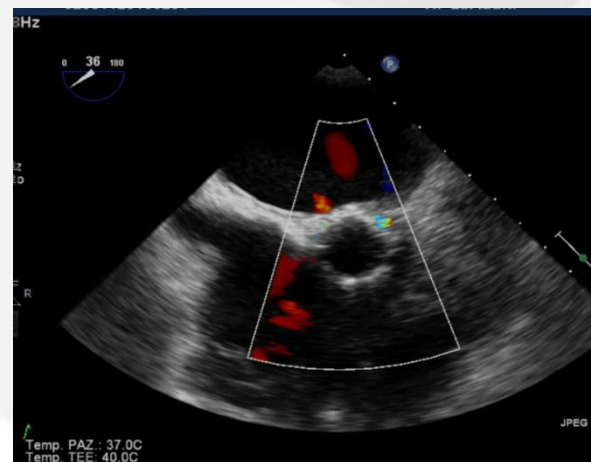
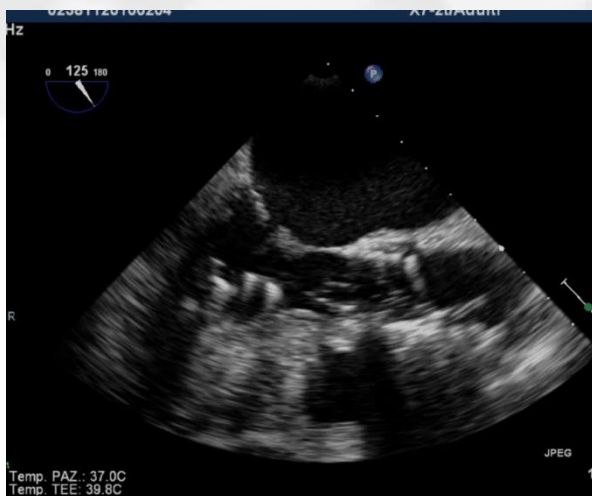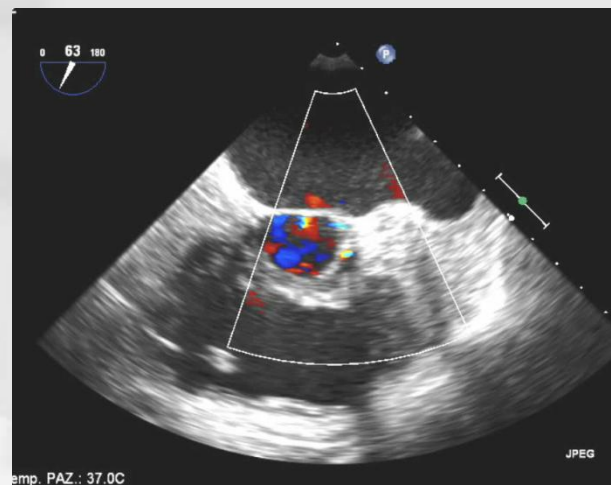
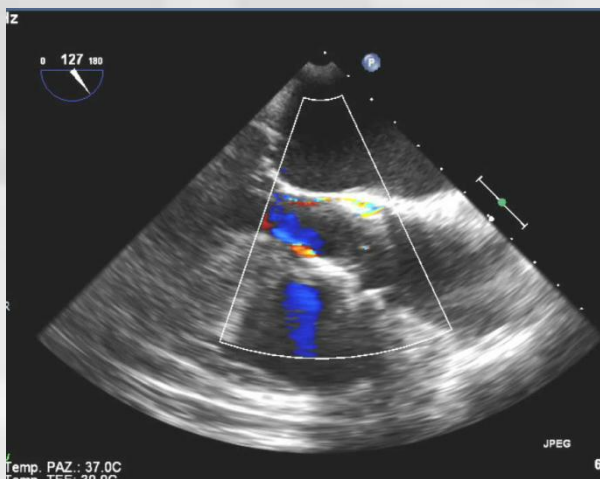
➤ X plane



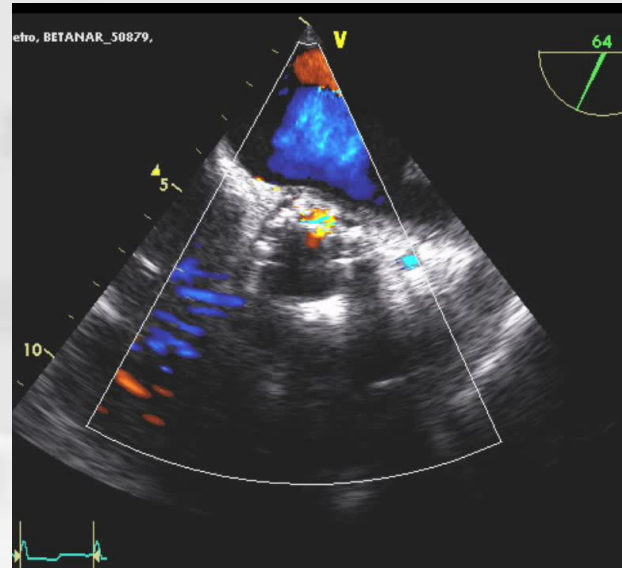
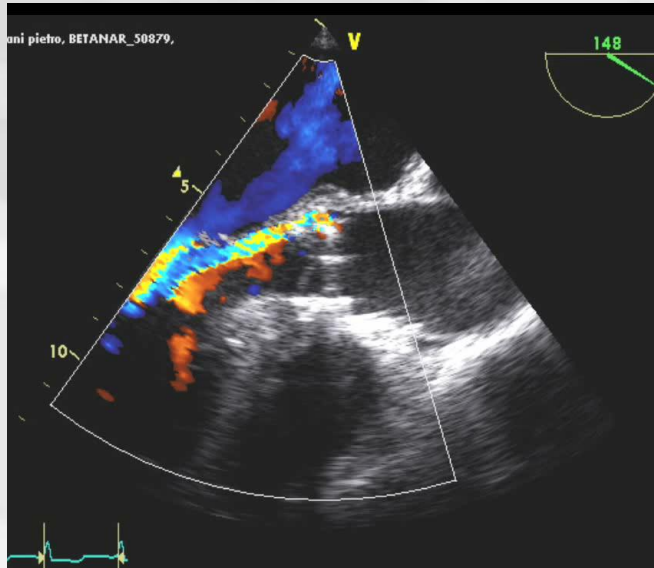
TEE Monitoring: insufficienza paraprotetica



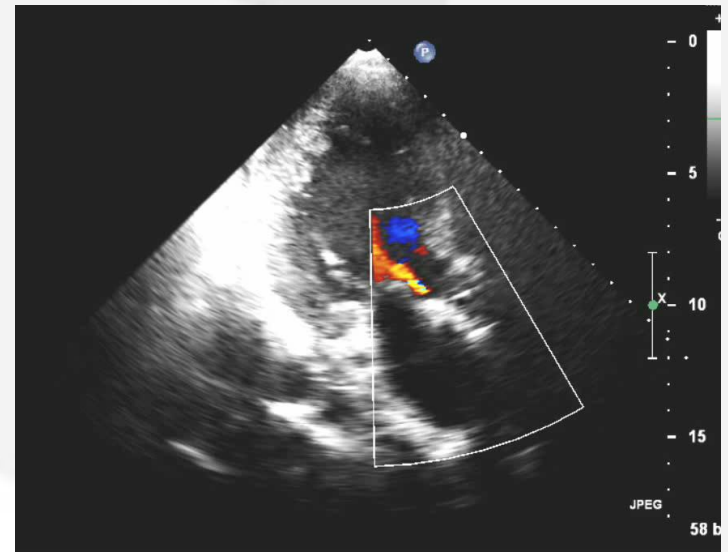
TEE Monitoring: insufficienza paraprotetica: Caso 1



TEE Monitoring: insufficienza paraprotetica Caso 2



1 year later



Recommendations for Comprehensive Intraprocedural Echocardiographic Imaging During TAVR



Rebecca T. Hahn, MD,* Stephen H. Little, MD,† Mark J. Monaghan, PhD,† Susheel K. Kodali, MD,* Mathew Williams, MD,§ Martin B. Leon, MD,* Linda D. Gillam, MD, MPH||

Transcatheter aortic valve replacement (TAVR) has become an accepted alternative to surgical intervention in patients with severe, symptomatic aortic stenosis who are inoperable or at high risk for surgical valve replacement (1-4). Numerous consensus papers and guidelines suggest that echocardiography is important in the pre-procedural, intraprocedural, and post-procedural evaluation of patients undergoing TAVR (5-8). Recent studies suggest that intraprocedural transesophageal echocardiographic (TEE) imaging may not be necessary for the safe placement of the transcatheter heart valve (THV) (9-13). These reports come from experienced, high-volume sites however and may not be generalizable to new programs or low-volume sites. Although no direct comparison between these techniques has been

made, Greif et al. (9) reported a combined safety endpoint by VARC (Valve Academic Research Consortium) criteria of 12.8% and a 30-day mortality rate of 5% in an intermediate risk group of patients (log EuroSCORE of 16 ± 14) in whom fluoroscopy alone was used for TAVR. These results however fall short of the 30-day mortality of 3.7% in the high risk (log EuroSCORE 29 ± 16) as-treated transfemoral population of the PARTNER (Placement of AoRTic TraNscathetER Valves) IA trial (14), in which intraprocedural TEE was typically performed, raising the possibility that intraprocedural echocardiography may contribute to improving outcomes. Although one barrier to universal intraprocedural TEE is the perceived need for general anesthesia, the risks associated with general anesthesia (15) and TEE imaging (16,17) are low and may