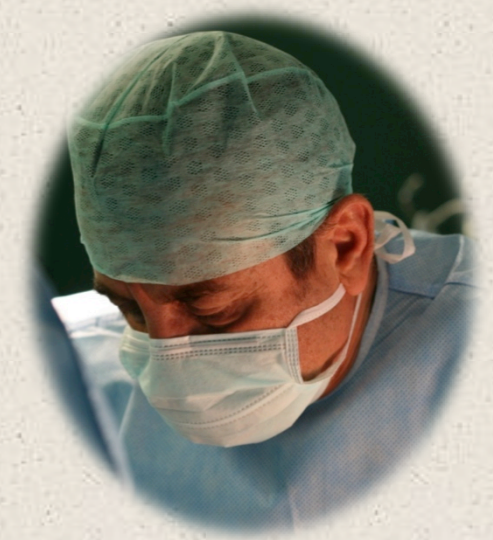

7 May 2014

IL **SAM** DOPO PLASTICA DELLA MITRALE: QUANDO ASPETTARSELO, COME PREVENIRLO, COME CURARLO

Prof. Francesco Alamanni

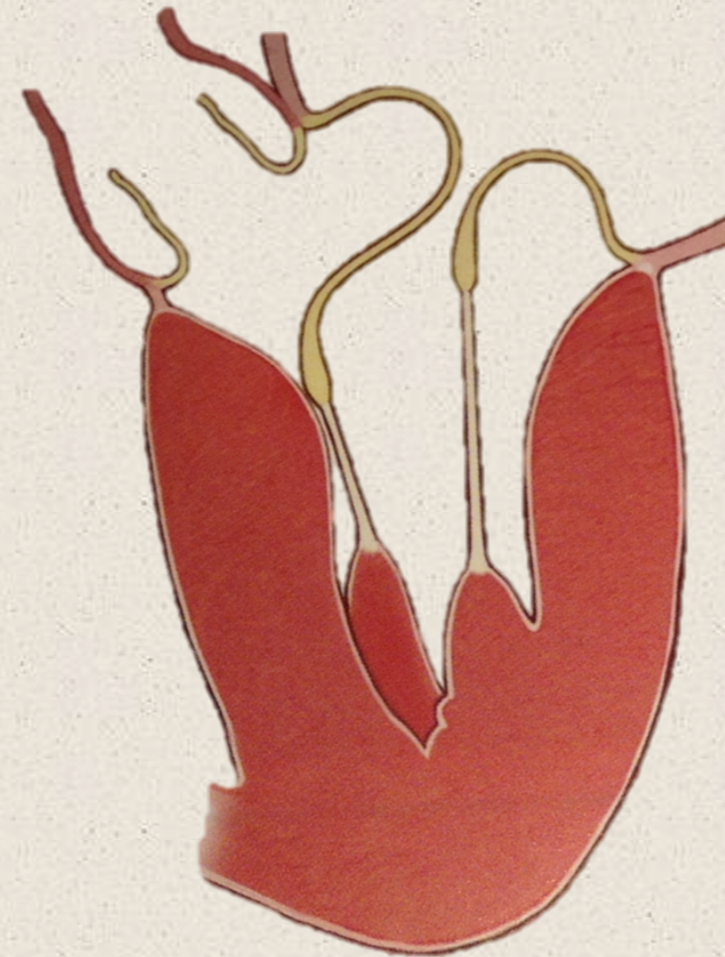

VII CONGRESSO DI ECOCARDIOCHIRURGIA

SAM is defined as a systolic displacement of the distal portion of the anterior leaflet of the mitral valve (MV) towards the outflow tract of the left ventricle

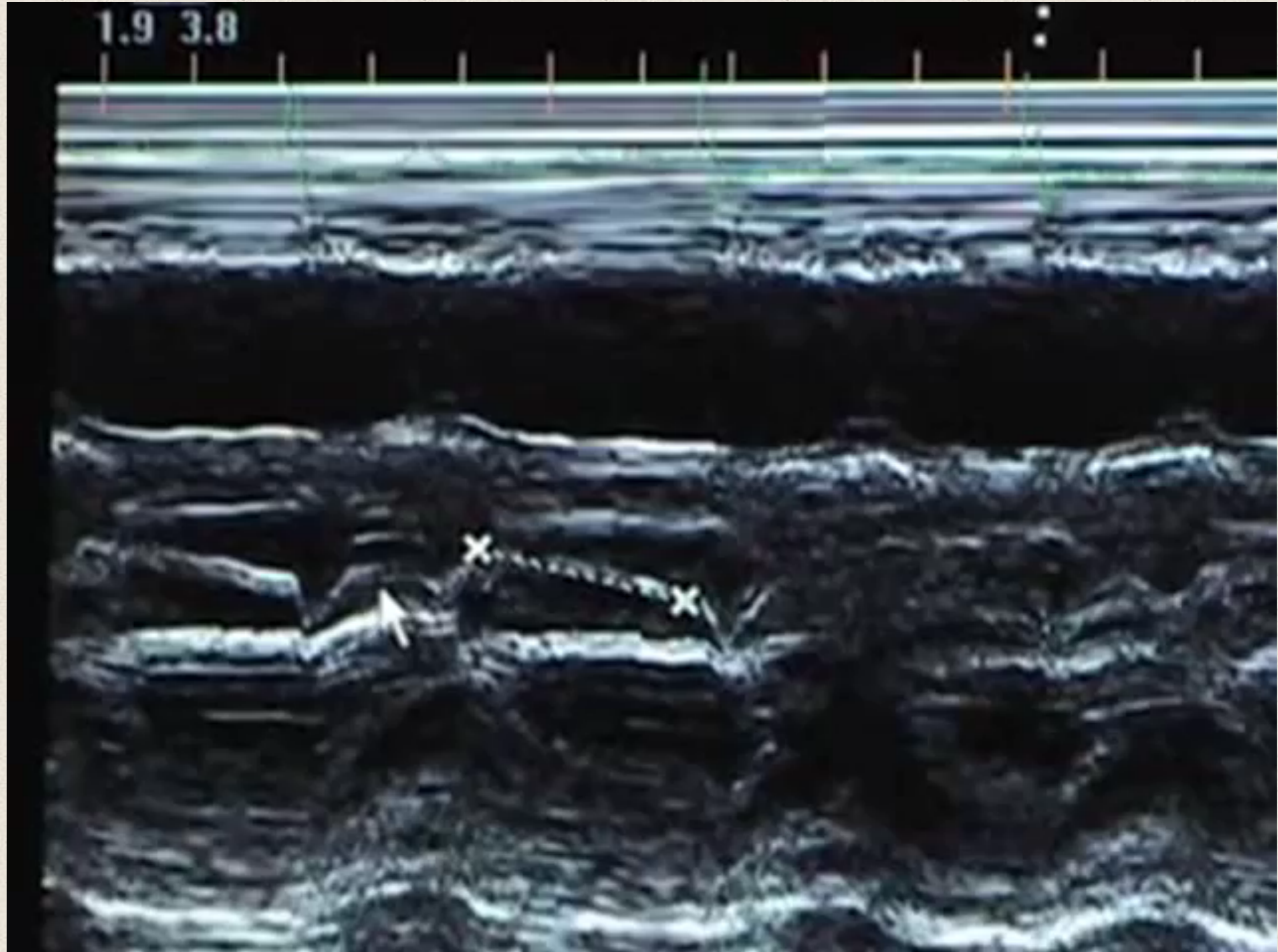


Diastole

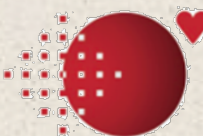
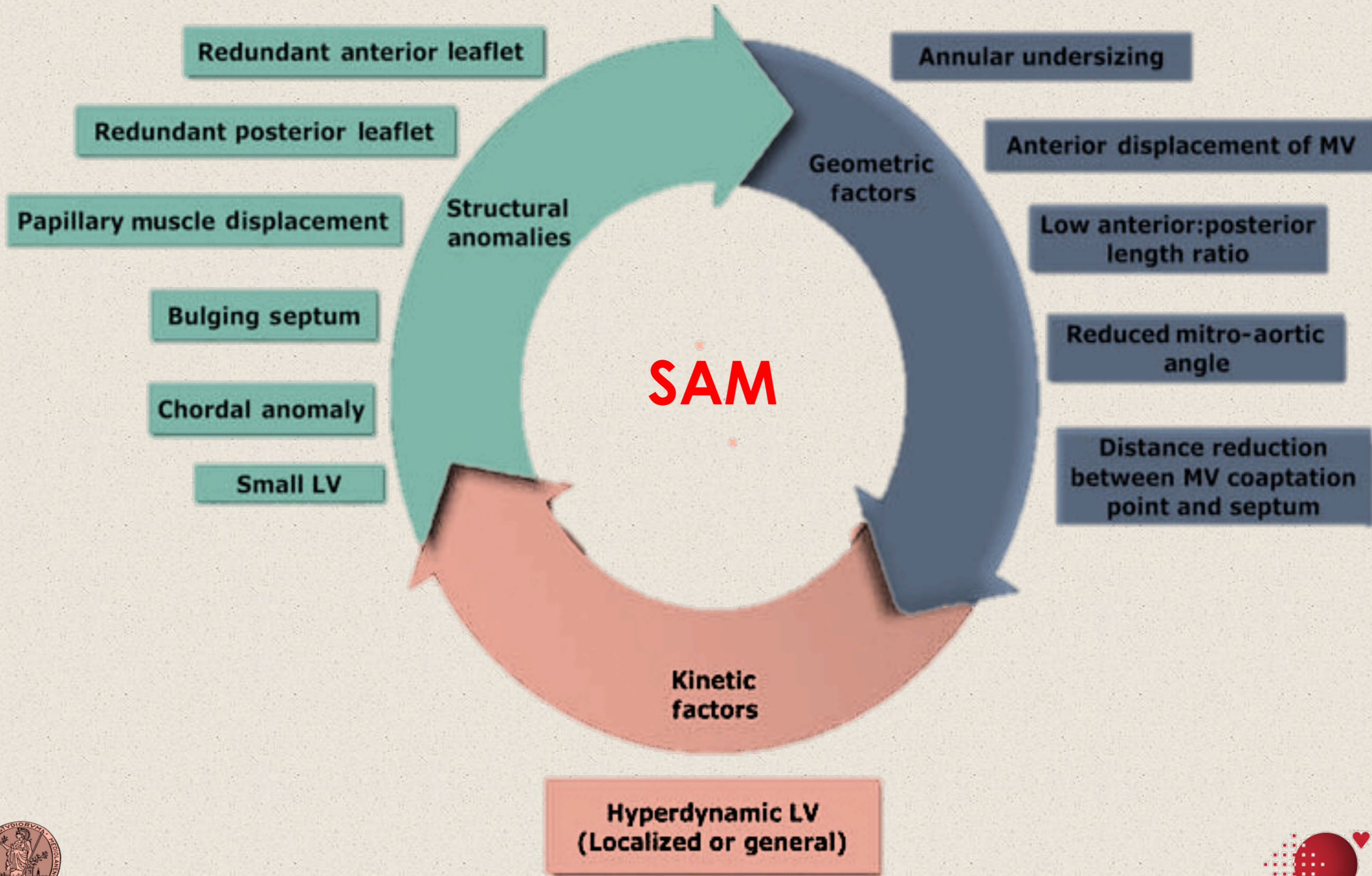


Sistole

Systolic Anterior Motion



Systolic Anterior Motion Causes



PRE-operative

Reduced mitro-aortic angle

Redundant anterior leaflet

Redundant posterior leaflet

Papillary muscle displacement

Structural anomalies

Bulging septum

Chordal anomaly

Small LV



The Mitro-aortic angle

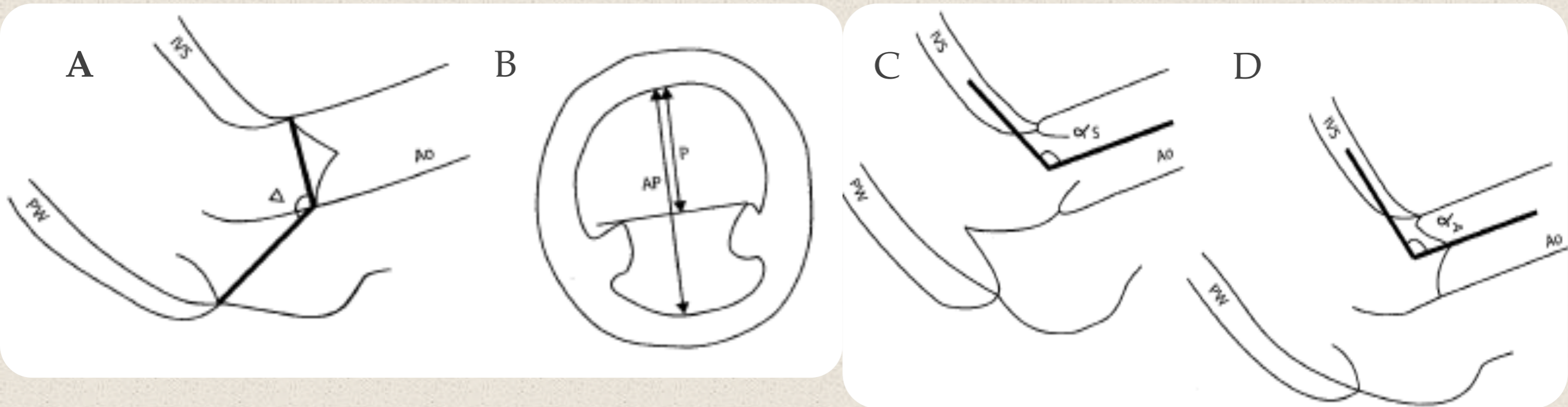


Table 3 Baseline echocardiography

	SAM (n = 23)	no SAM (n = 77)	no SAM LVO+ (n = 20)	no SAM LVO- (n = 57)
LV EDD (mm)	45 ± 4†	47 ± 5*	45 ± 5†	48 ± 5
LV ESD (mm)	25 ± 4†	28 ± 6*	26 ± 4†	29 ± 6
IVS (mm)	11 ± 2	11 ± 2	10.9 ± 2	10.9 ± 2
PW (mm)	9 ± 1	9 ± 1	9 ± 1	9.1 ± 1
LV ejection fraction (%)	73 ± 6	69 ± 10	73 ± 9	68 ± 6
LV mass (g/m ²)	85 ± 15	90 ± 20	85 ± 21	92 ± 19
Anterior mitral leaflet (mm)	22 ± 2	21 ± 3	20.4 ± 3	21.3 ± 3
Posterior mitral leaflet (mm)	16 ± 3†‡	13.5 ± 3*	13.1 ± 3	13.5 ± 2.5
Mitral annular diameter (mm)	27 ± 2†	28 ± 3	27 ± 3†	29 ± 3
Papillary p/APx	0.54 ± 0.04	0.56 ± 0.04	0.54 ± 0.04	0.56 ± 0.05
LVOT (mm)	20 ± 1	20 ± 2	20 ± 2	20.5 ± 1
Mitroaortic angle (°)	124 ± 7†	130 ± 7*	127 ± 7	131 ± 8
Diastolic α IVS-Ao (°)	103 ± 11	107 ± 10	105 ± 10	108 ± 9
Systolic α IVS-Ao (°)	109 ± 11†	115 ± 10*	114 ± 10	118 ± 9

Ao, Aorta; EDD, end-diastolic diameter; ESD, end-systolic diameter; IVS, interventricular septum; LV, left ventricle; LVO, LV obstruction; LVOT, LV outflow tract; p/AP, distance from both papillary muscles to septum (p)/distance from septum to posterior wall (AP); PW, posterior wall; SAM, Systolic anterior motion of mitral valve.

* $P < .05$ vs SAM; † $P < .05$ vs no SAM LVO-; ‡ $P < .05$ vs no SAM LVO+.

Anterior and/or posterior leaflet redundant

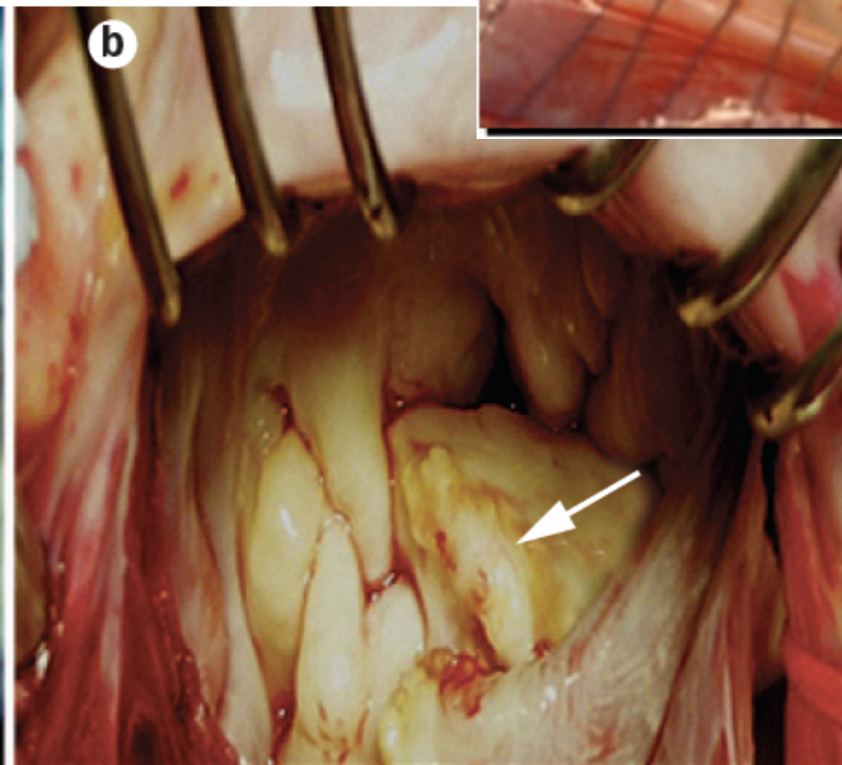
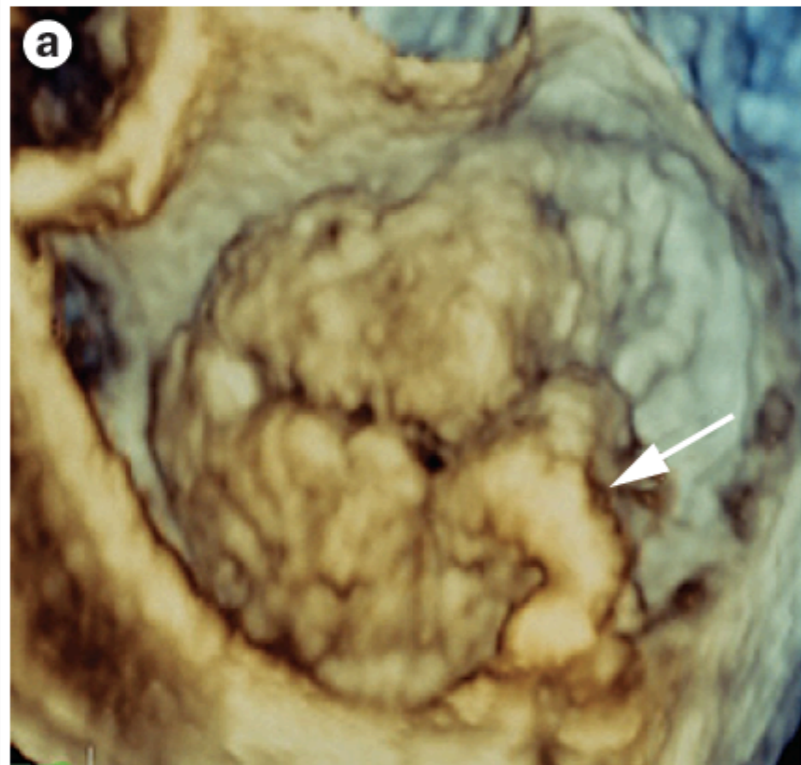
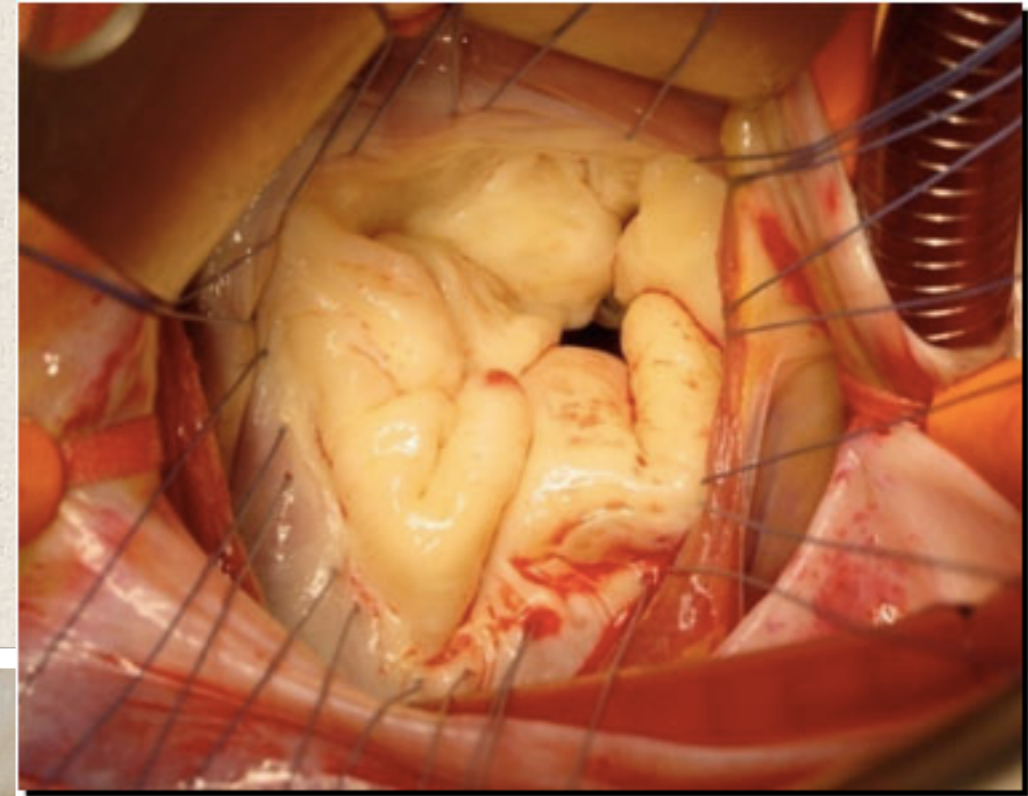
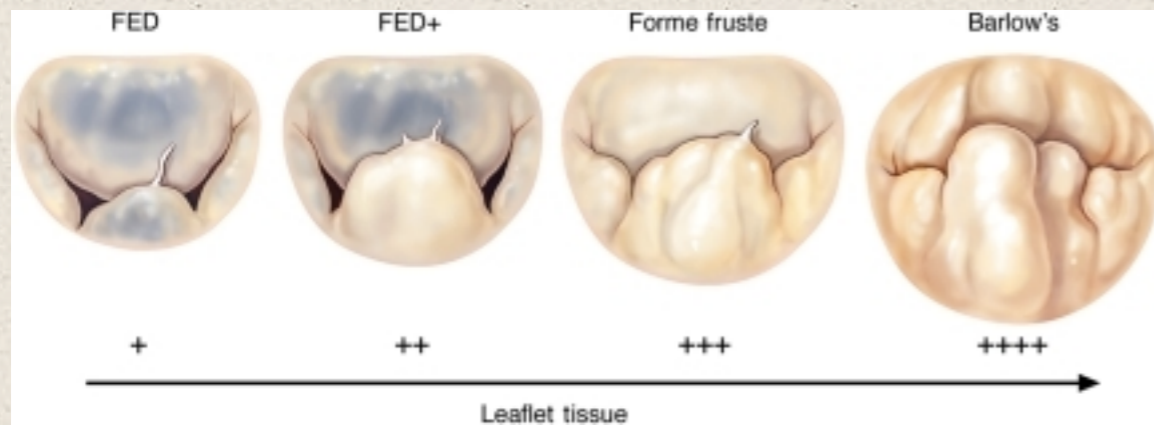
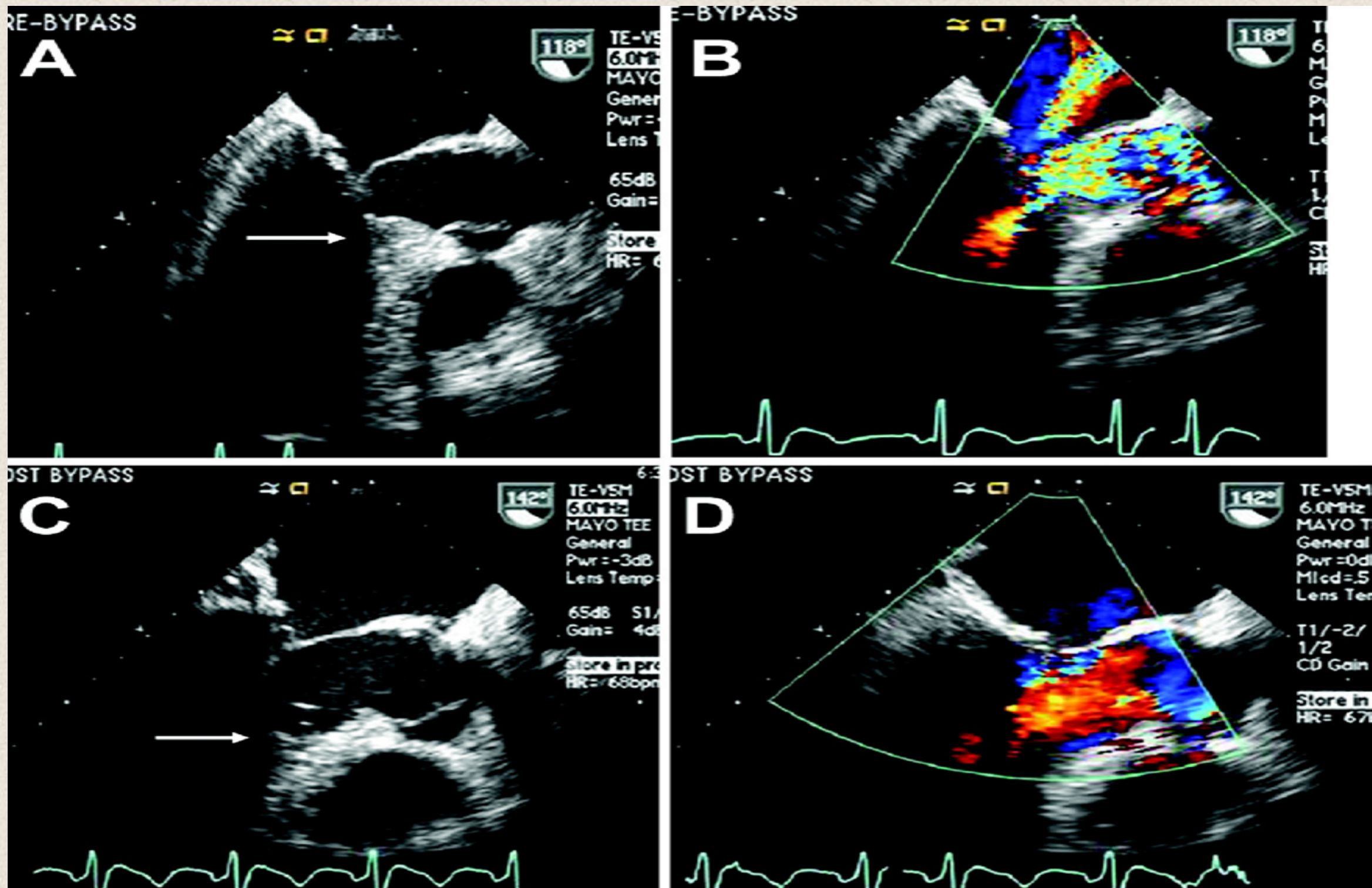


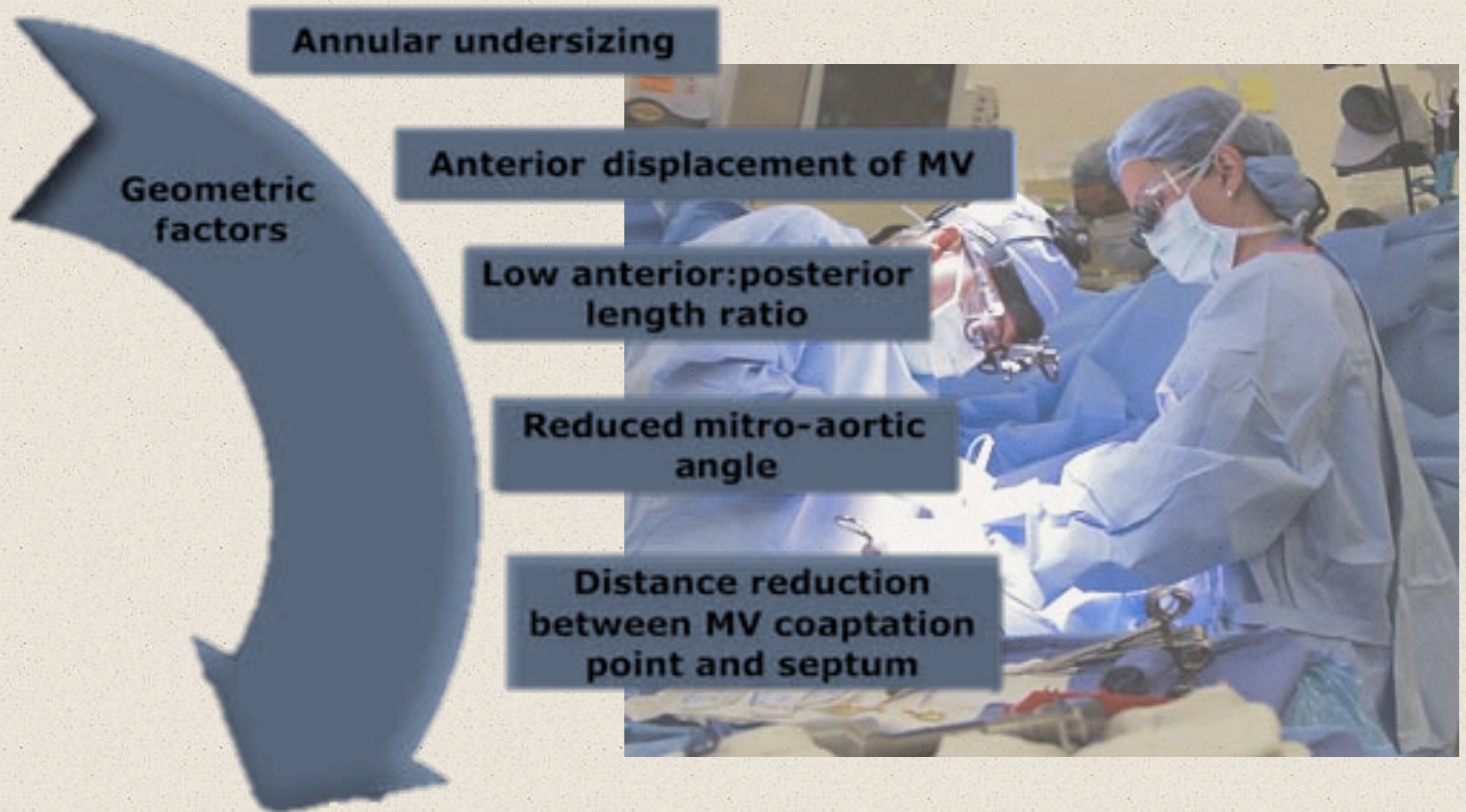
Figure 4 | Barlow disease with calcific degeneration (arrow) involving the posterior leaflet. **a** | Imaged by real-time 3D transesophageal echocardiography. **b** | As observed during surgery.

Prominent septal bulge



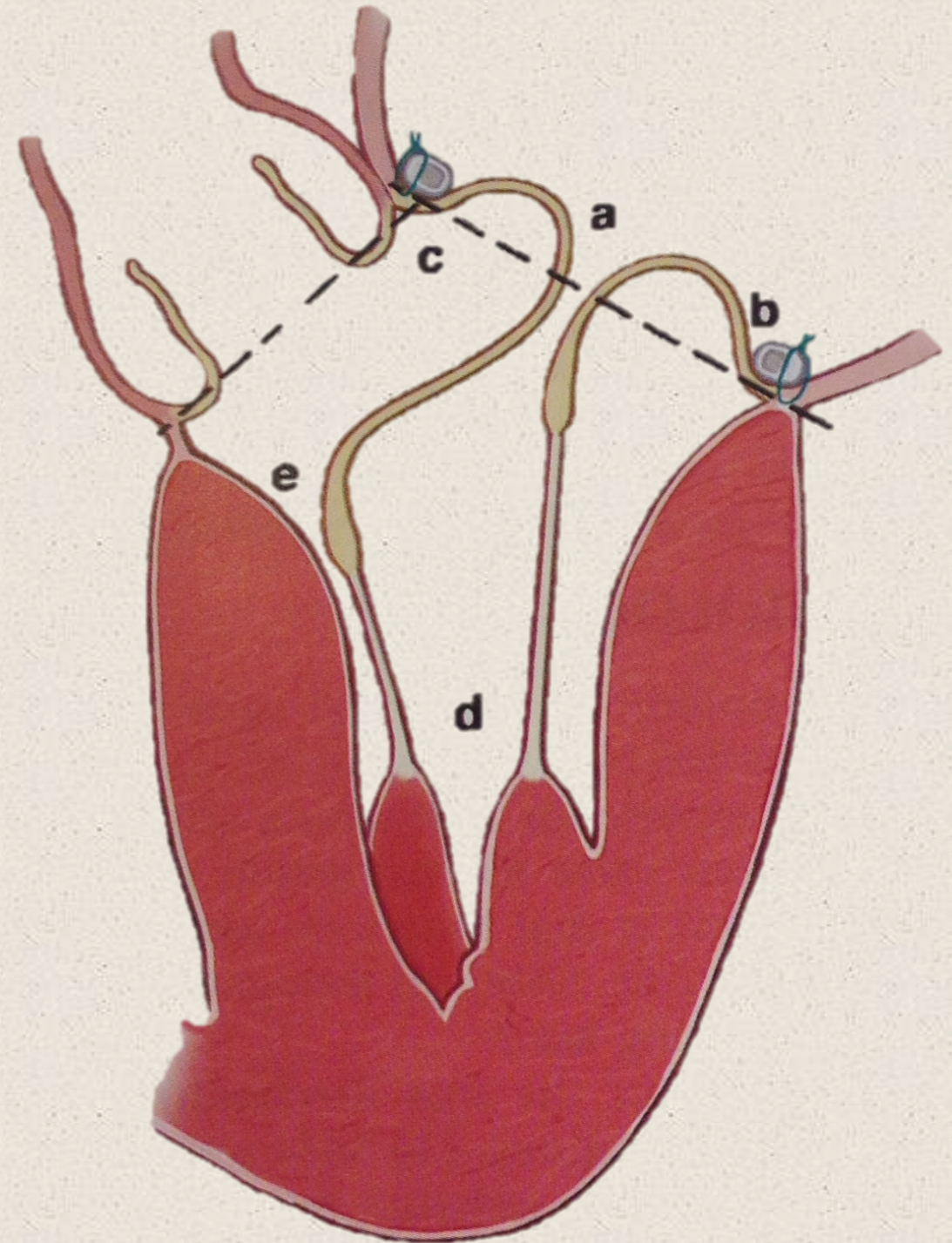
Intraoperative transthoracic echocardiography (TEE) of a patient (A) Severe systolic anterior motion (SAM) with prominent septal bulge (white arrow) before by-pass. (B) Severe SAM with severe mitral valve regurgitation (MR) and severe left ventricular outflow tract (LVOT) obstruction before bypass. (C) After septal myectomy (white arrow), no evidence of SAM was found when LVOT was opened wide. (D) Postseptal myectomy TEE with no SAM, widely opened LVOT, and minimal MR.

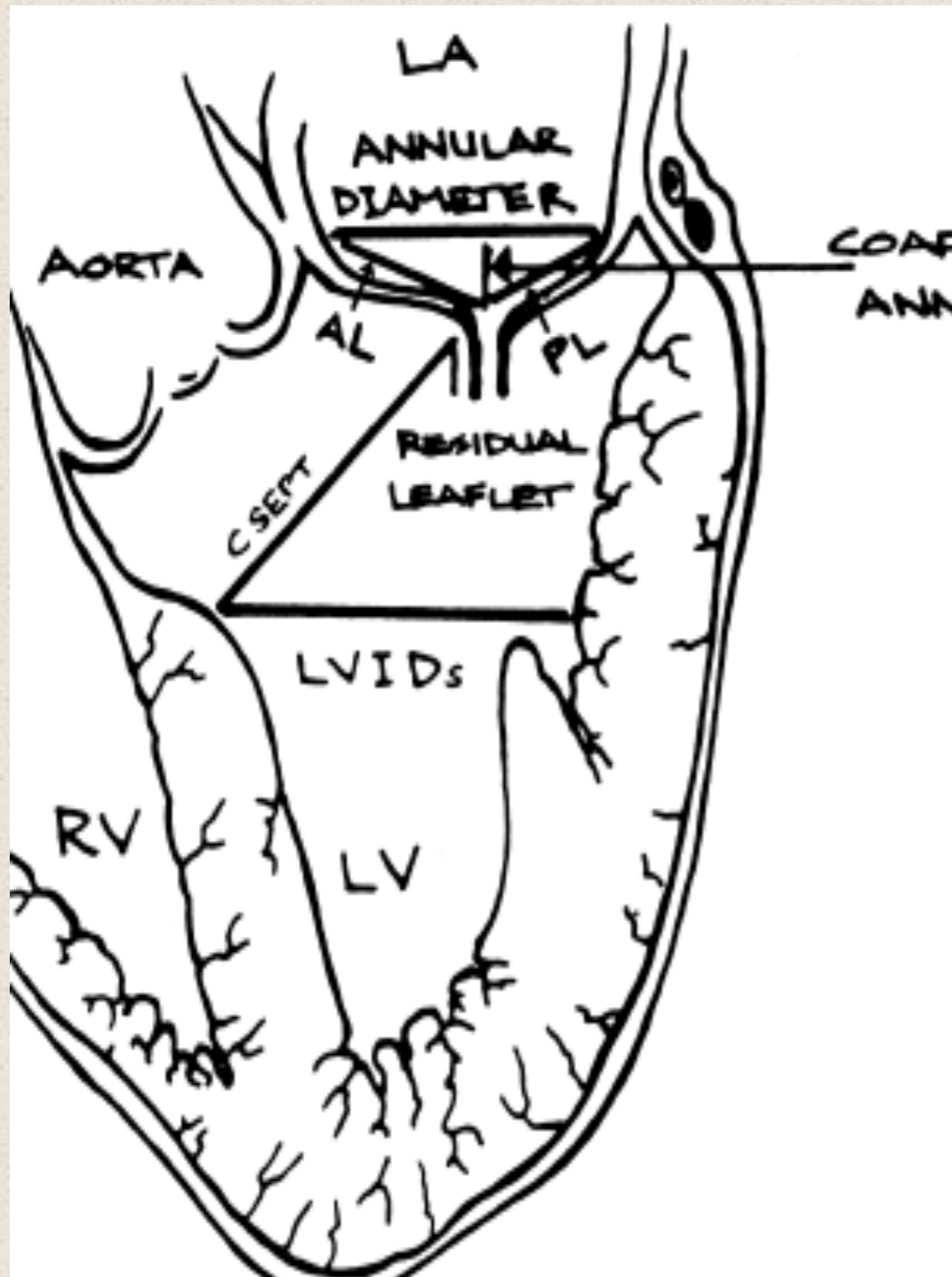
INTRA-operative



RISK FACTOR for SAM after MVR:

- **Excess of leaflet tissue (a)**
++LPM
- **Undersized ring (b)**
- Narrow mitro-aortic angle (c)
- Small hyperkinetic ventricle (d)
- Abnormal configuration of the LAM (e)



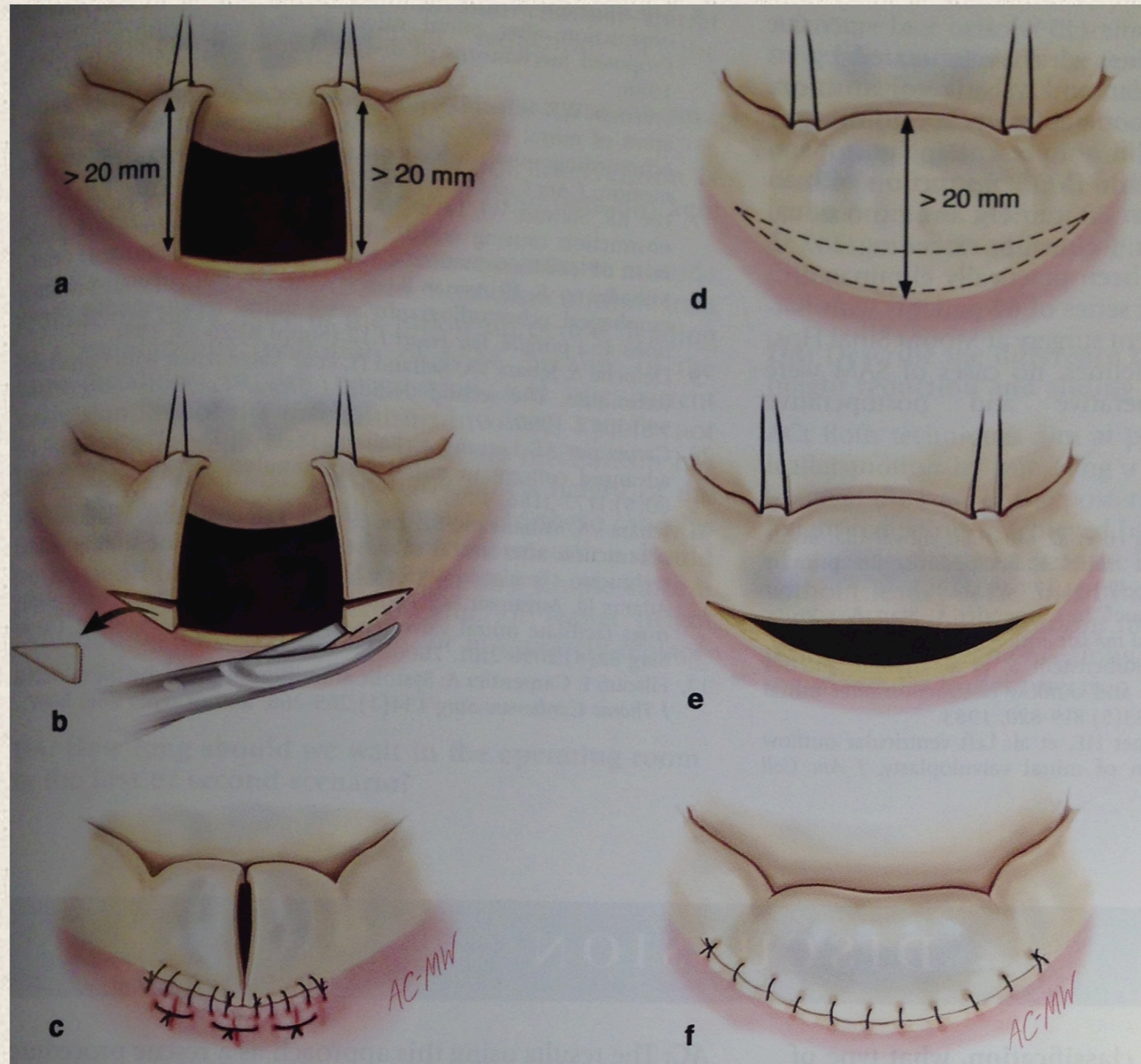


- greater reduction in the posterior leaflet height if the prerepair **AL/PL ratio** is 1.3 or lower
- Importance of the **distance from mitral coaptation point to annular plane** (2.5 cm or less)

AL : anterior leaflet length; Ann Diam: annular diameter; CoaptAnn: distance from the mitral coaptation point to the annular plane; CSept: distance from the mitral coaptation point to the septum; LVIDs : left ventricular internal diameter in systole; PL: posterior leaflet length.

HOW to prevent SAM

pay attention to: **1. Height of the PLM**



The importance of the correct anuloplasty **Mitral Ring**



C-E Classic Ring

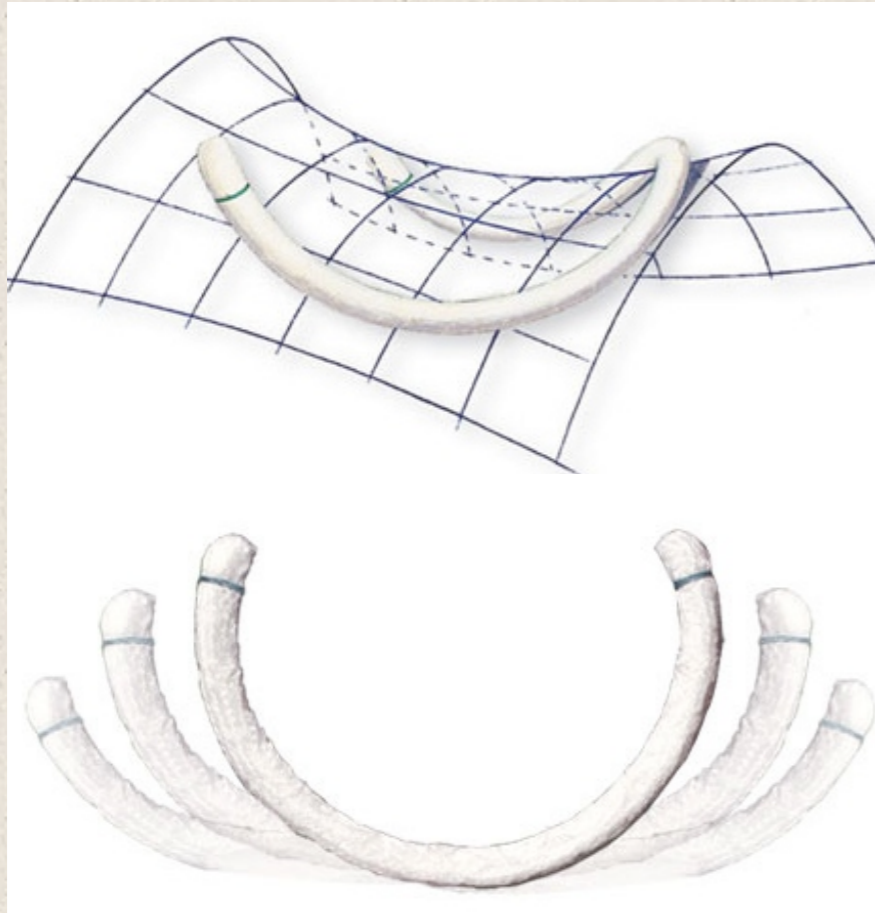


C-E Physio Ring

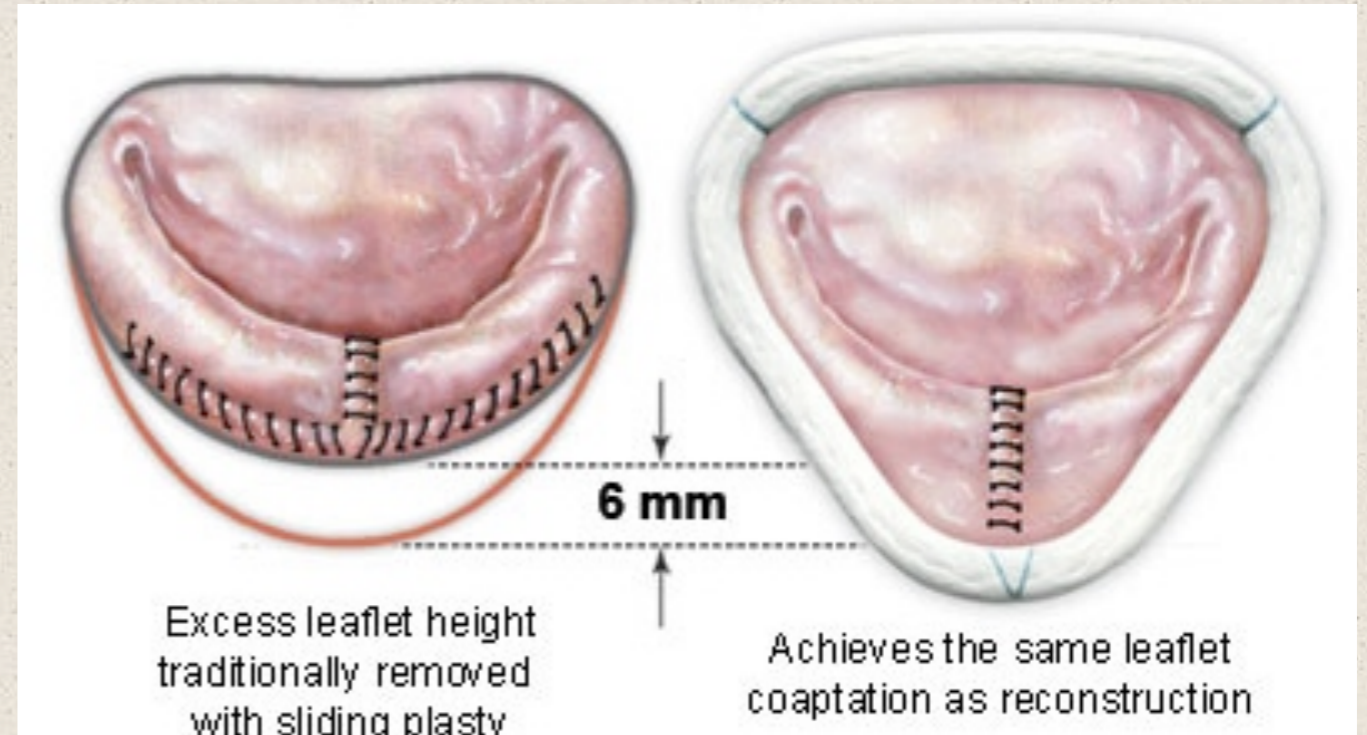


C-E Physio II Ring

The importance of the correct anuloplasty **Mitral Ring**



Cosgrove-E Ring

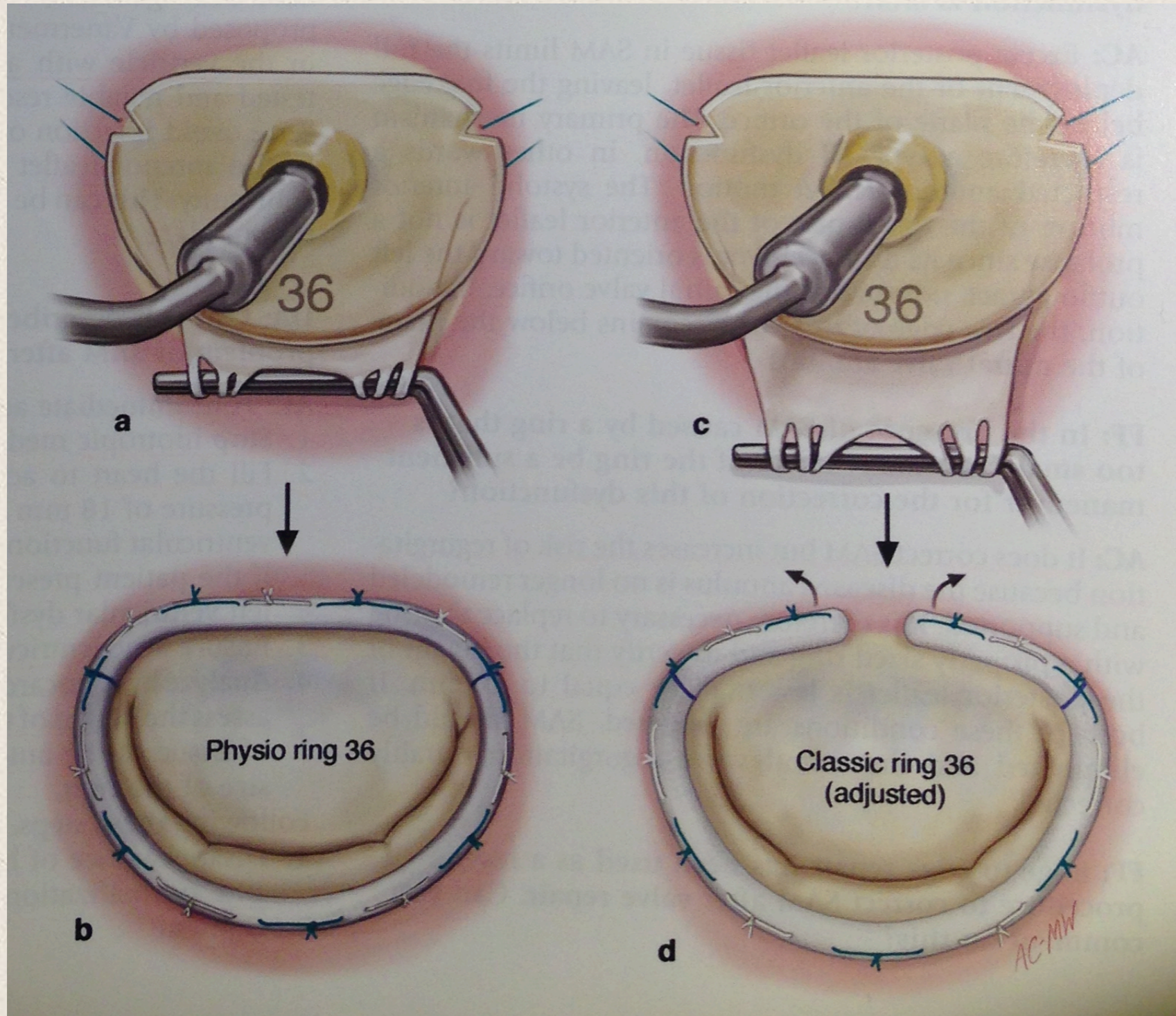


Myxo ETlogix



HOW to prevent SAM

pay attention to: **2. Sizing of the LAM** (not only the surface but also the height)





*C-E Physio II seems to reduce risk of SAM

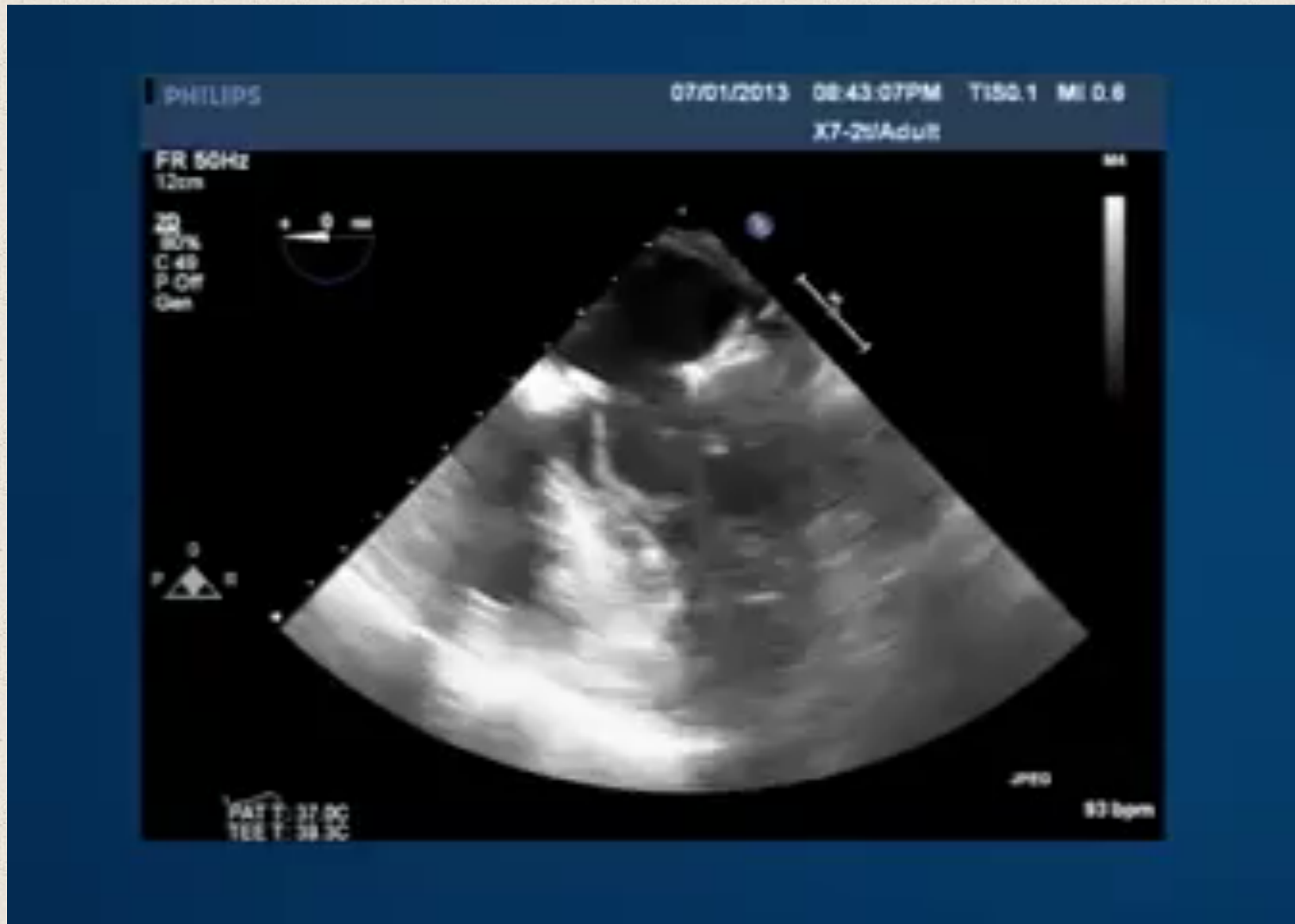
Systolic Anterior Motion MV repair



VII CONGRESSO DI ECOCARDIOCHIRURGIA

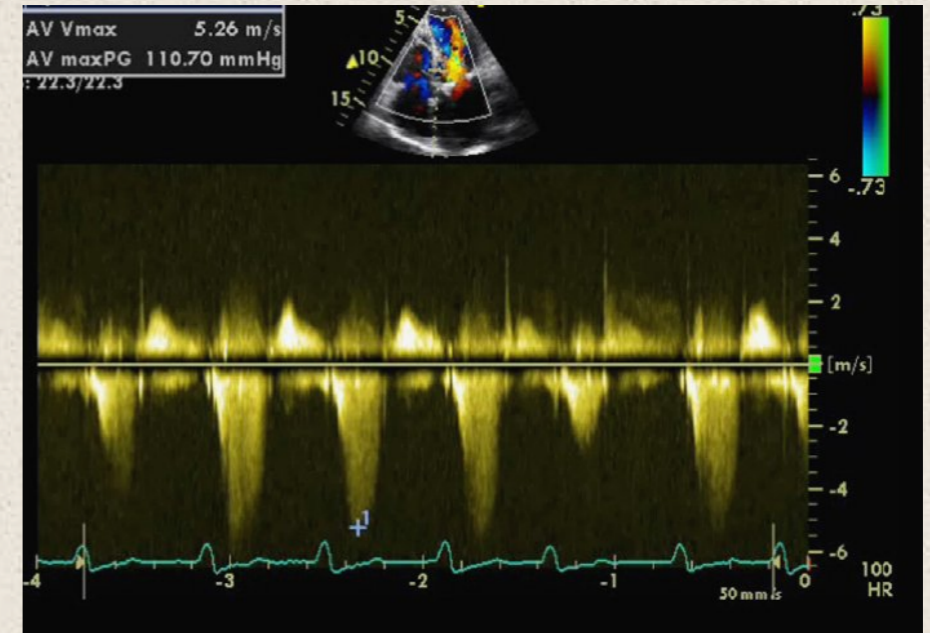


Systolic Anterior Motion



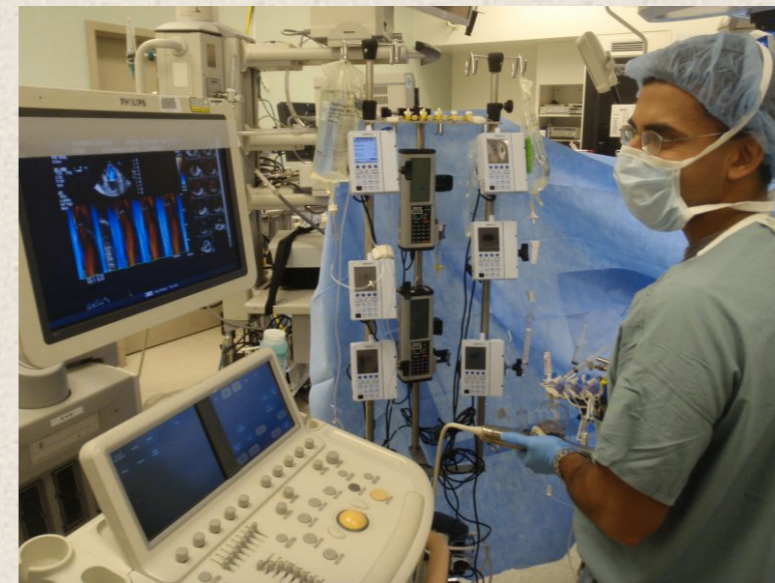Classification:

- **Mild** SAM (LVOT grad <50 mmHg and/or less than mild MR)
- **Significant** SAM (LVOT grad >50 mmHg and/or mild MR or greater)



Intraoperative classification (Crescenzi et al.):

- **Easy-to-revert** SAM (disappeared after intravascular volume expansion, discontinuation of inotropic drugs)
- **Difficult-to-revert** SAM (disappeared increasing afterload and with B-blockers administration)
- **Persistent** SAM (did not disappear with conservative management)



WHAT TO DO ?

MITRAL VALVE PROLAPSE

Management of systolic anterior motion after mitral valve repair: An algorithm

Robin Varghese, MD, MS, FRCSC, Anelechi C. Anyanwu, MD, MSc, FRCS, Shinobu Itagaki, MD, Federico Milla, MD, Javier Castillo, MD, and David H. Adams, MD

Brown et al

Objective: To evaluate the effectiveness and outcomes of an intraoperative and postoperative algorithm for managing systolic anterior motion (SAM) after mitral valve repair (MVRr).

Systolic anterior motion after mitral valve repair: Is surgical intervention necessary?

Morgan L. Brown, MD,^a Martin D. Abel, MD,^b Roger L. Click, MD,^c Ronald G. Morford, MD,^d Joseph A. Dearani, MD,^a Thoralf M. Sundt, MD,^a Thomas A. Orszulak, MD,^a and Harzell V. Schaff, MD^a




Earn CME credits at <http://cme.ctscnetjournals.org>

Objective: The natural history and management of patients with systolic anterior motion after mitral valve repair are uncertain.

Management and decision-making strategy for systolic anterior motion after mitral valve repair


Giuseppe Crescenzi, MD,^a Giovanni Landoni, MD,^a Alberto Zangrillo, MD,^a Fabio Guarracino, MD,^c Concetta Rosica, MD,^a Giovanni La Canna, MD,^b and Ottavio Alfieri, MD^b



Correct:


1. Suboptimal ventricular filling
2. Atrioventricular asynchrony
3. Hypercontractility of the ventricle

- *keeping the left ventricle expanded to allow reasonable LVOT opening*



crystalloid and colloid solutions

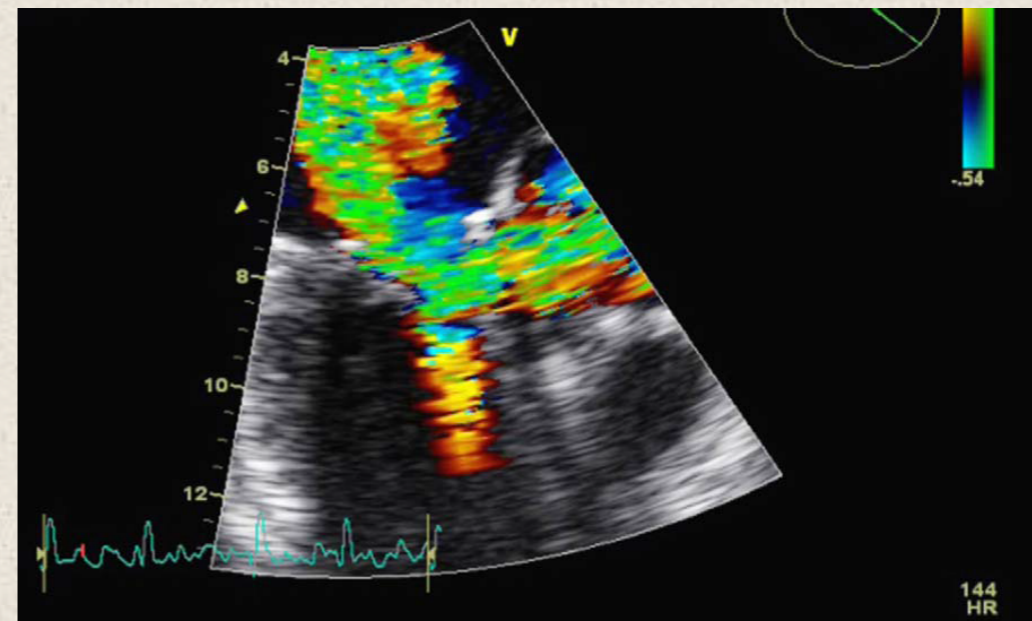
- *Heart rate should be stabilized to maximize diastolic time.*



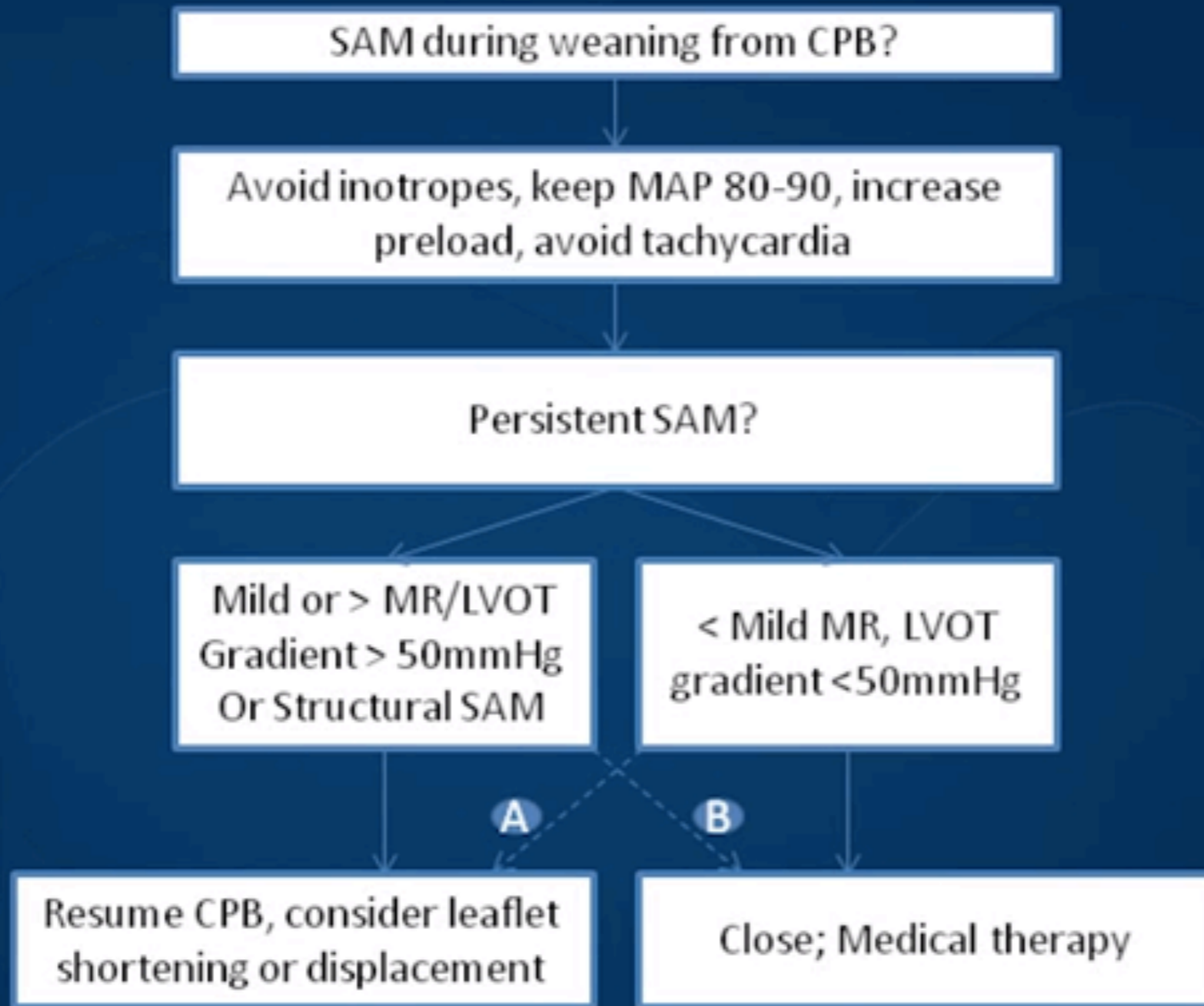
beta-blockers

- *Increase afterload*

- **Positive inotropes (epinephrine etc.) should be discontinued or used with caution**



“Identification and proper treatment with B-blockade and avoidance of afterload-reducing medications are usually successful, and re-repair is rarely necessary”



Modified from Varghese et al. **Management of systolic anterior motion after mitral valve repair: An algorithm.** JTCVS 2012.143;4: S2-S7. <http://dx.doi.org/10.1016/j.jtcvs.2012.01.063>

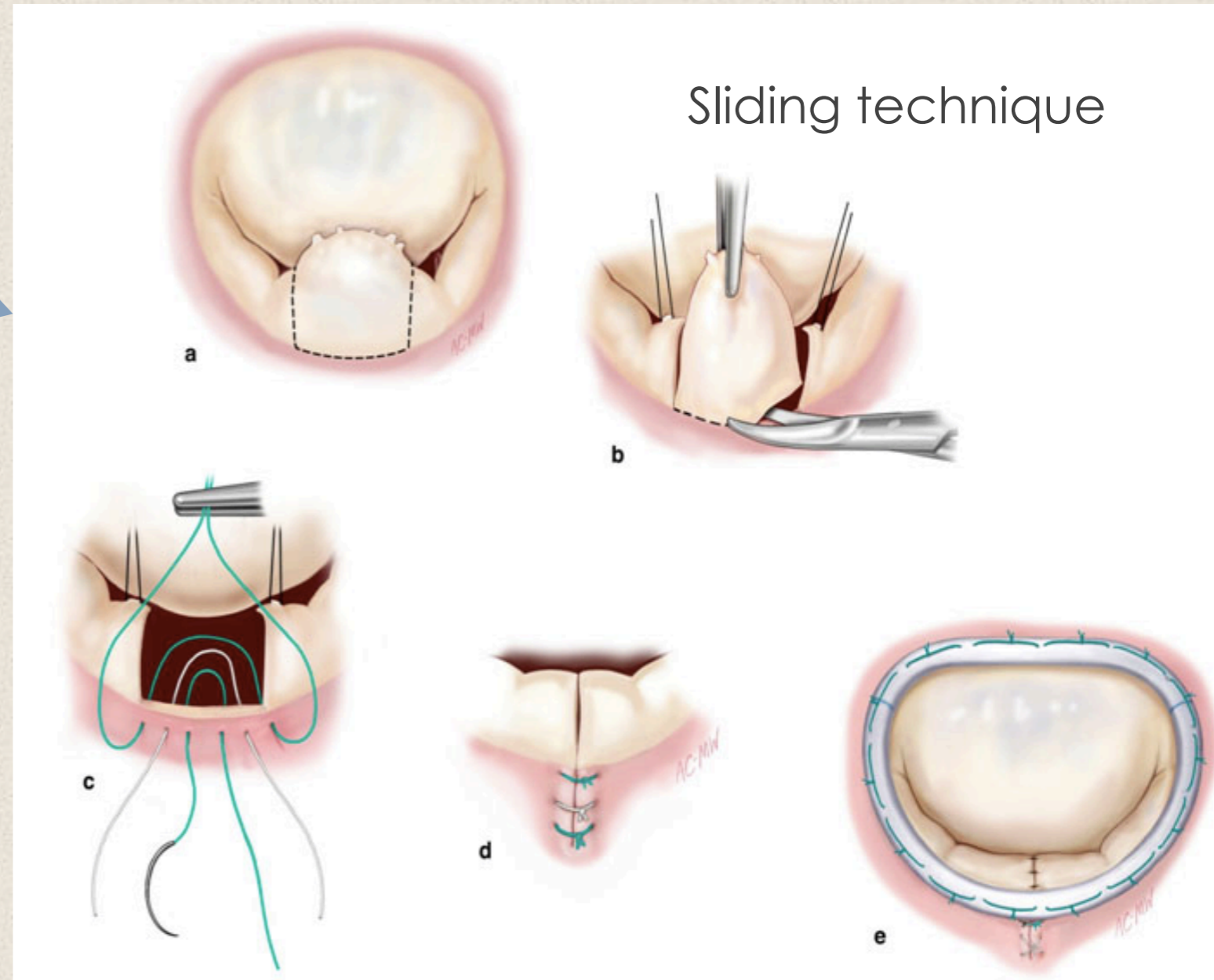
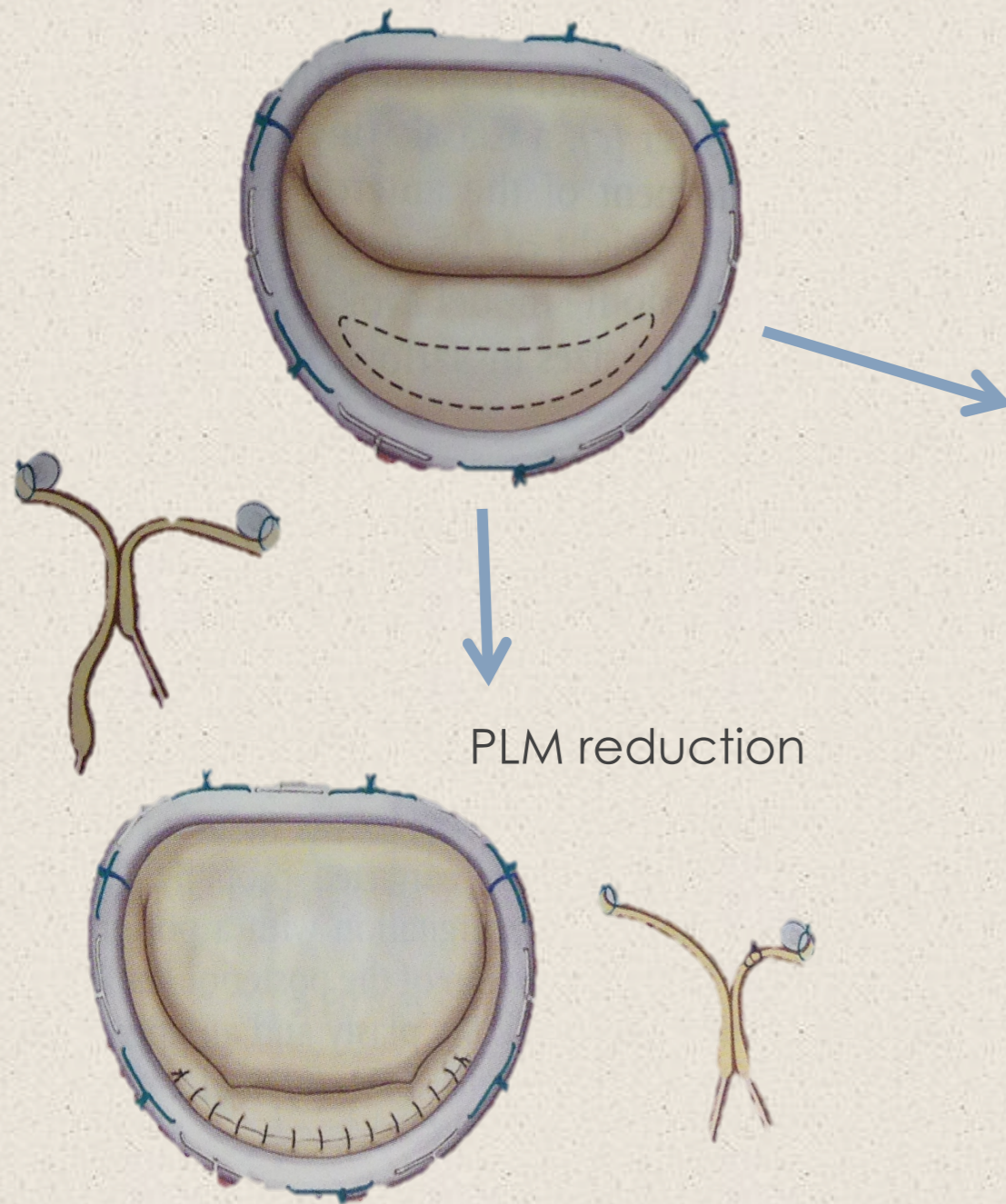
Persistent SAM: how to correct it?

- **Sliding plasty**
- **Artificial neo-chords**
- **Mitral ring substitution** (different size++/type)
- **Resection of LAM** (reduction of the height of LAM)
 - *Elliptical excision at the base of LAM*
 - *Plication of PLM*
 - *Transposition of secondary chordae into LAM*
 - *Alfieri's edge-to-edge suture*
 - *Asymmetric Alfieri's stitch*
 - *Papillary muscle-to-anterior anulus stitches*
 - *Paradoxycal artificial chords*



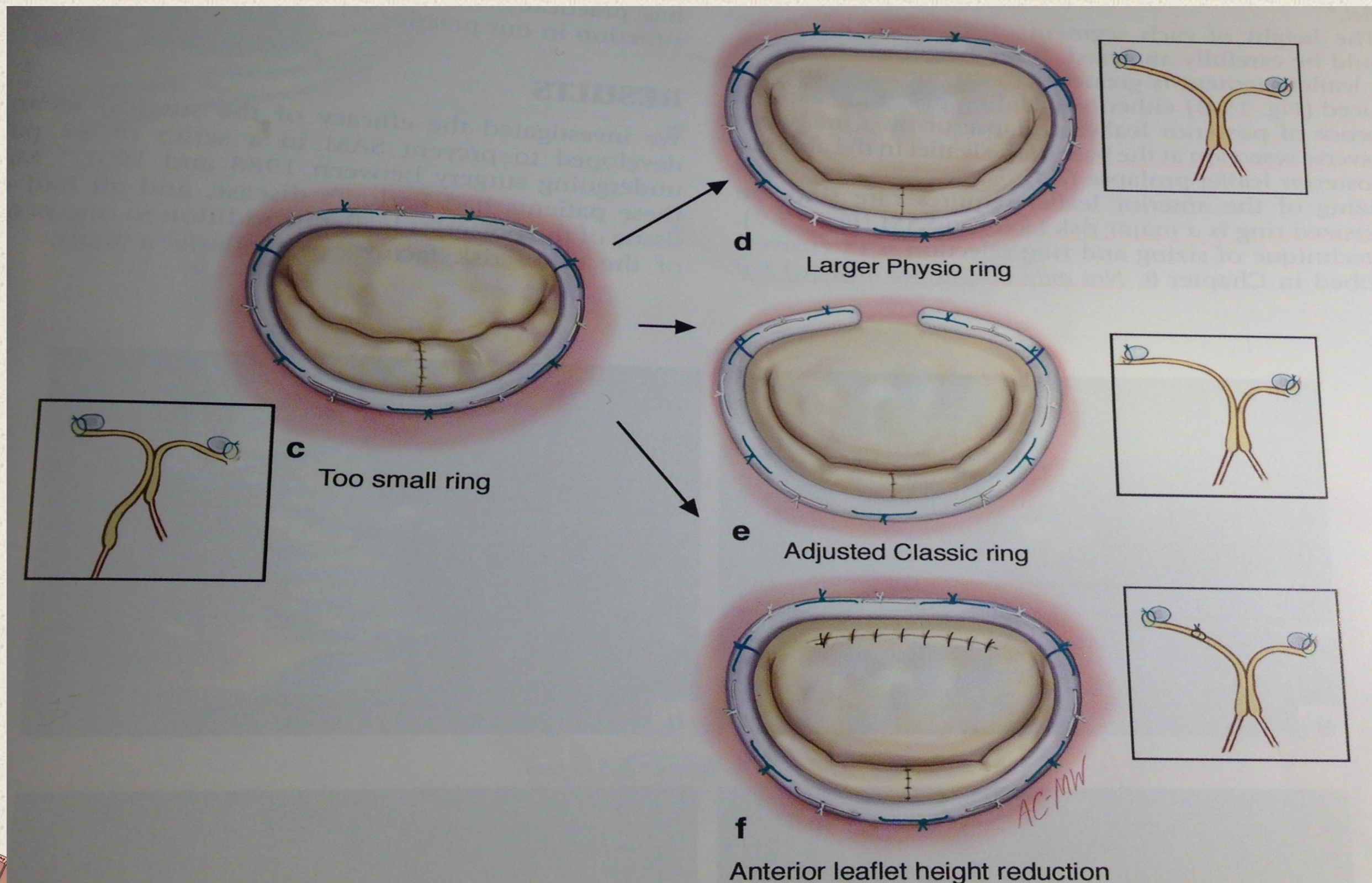
Persistent SAM: how to correct it?

Excess tissue of LPM



From Carpentier A, Adams DH, Filsoufi F. Carpentier's Reconstructive Valve Surgery. Saunders (Elsevier), 2010

Persistent SAM: how to correct it?



Systolic Anterior Motion Clinical case 1

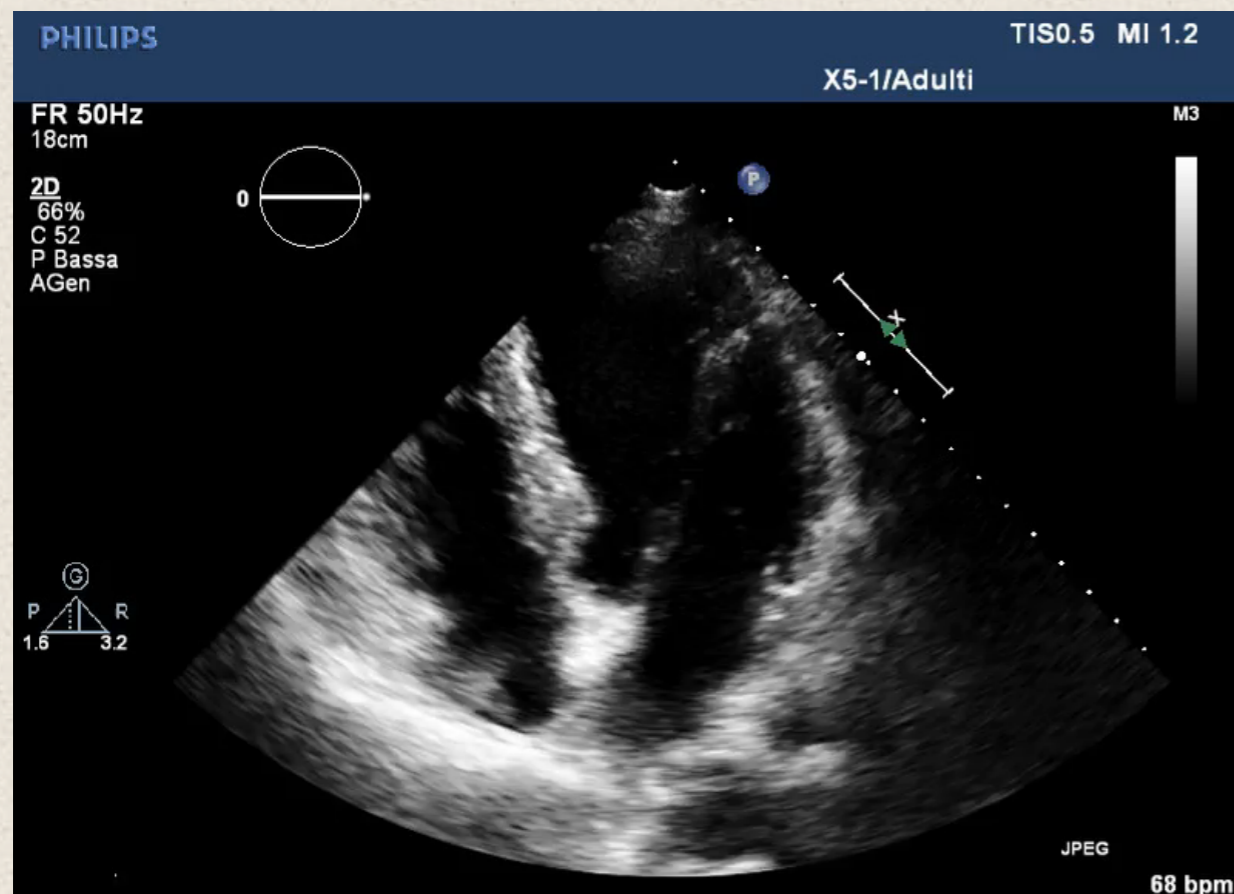


VII CONGRESSO DI ECOCARDIOCHIRURGIA

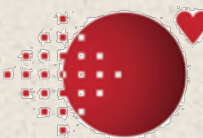
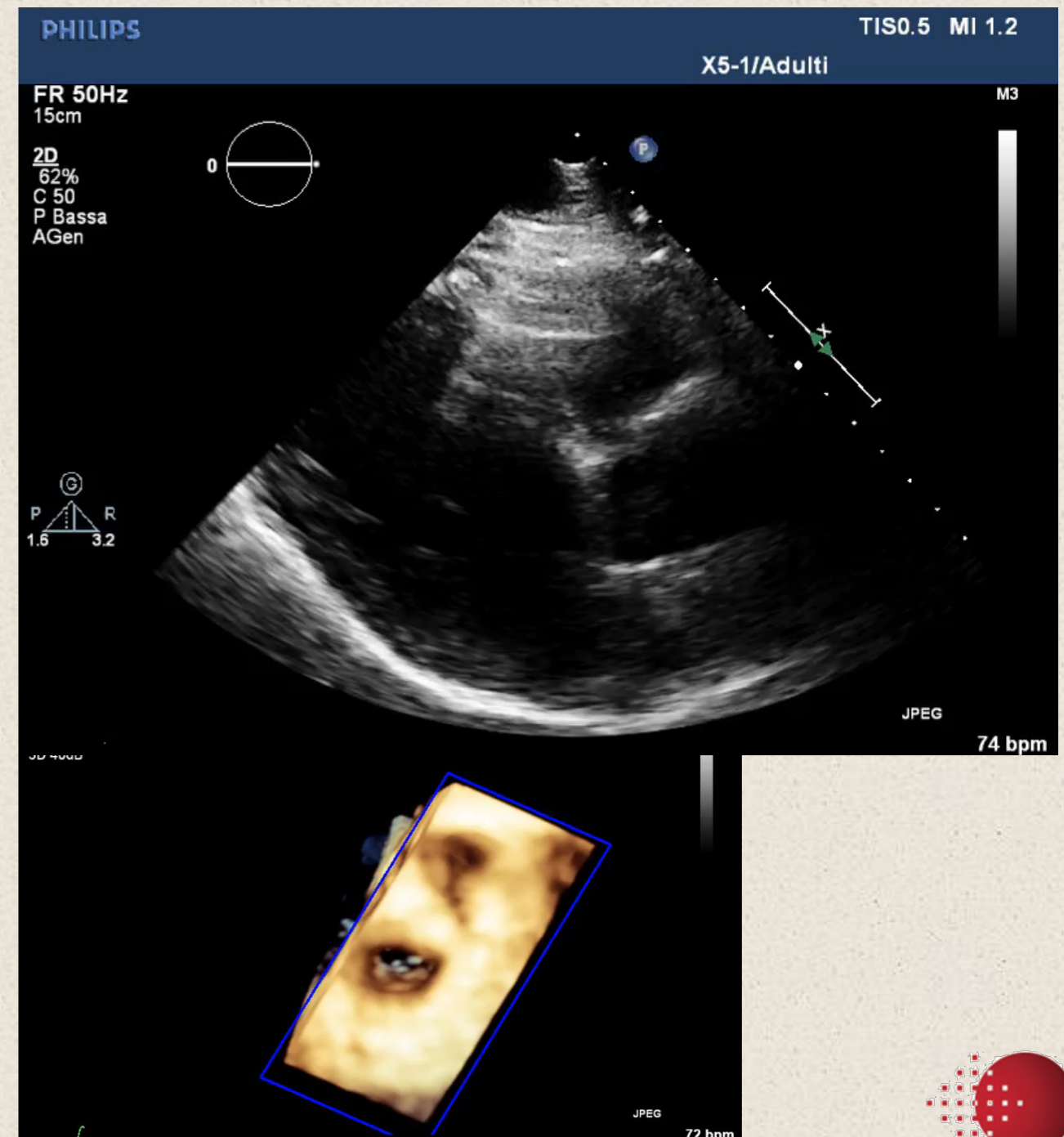
Paziente di 62 aa. , anamnesi positiva per FdR cardiovascolare, IPA in terapia, non patologie maggiori.

ECO TT 3D: dilatazione dell'anello mitralico (39mm) ispessimento dei lembi mitralici, **ampio prolasso di P2 con rottura cordale ed everzione della scallop** che condiziona **rigurgito severo**

(EROA 0,75) direzionato medialmente e anteriormente; dilatazione ventricolare sinistra con normale funzione sistolica; normali dimensioni del settore dx.

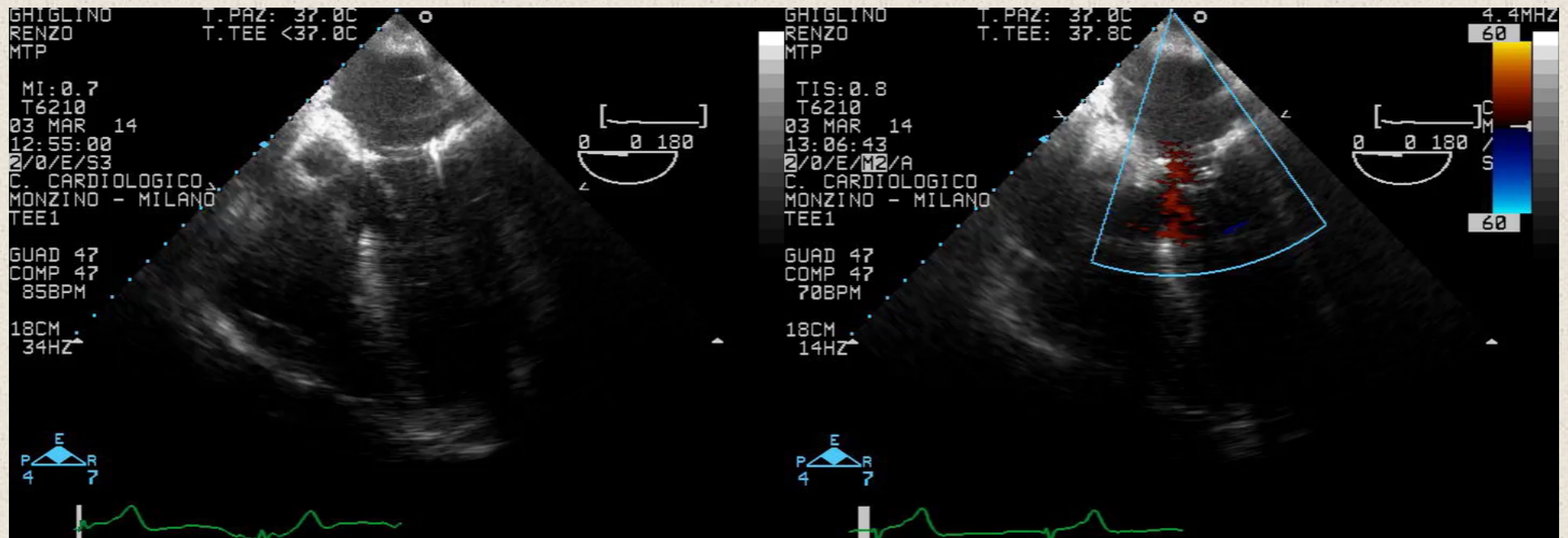


Pre-operative



MVR sternotomia mediana, bypass cardiopolmonare
Resezione quadrangolare P2, Grossi P3, impianto di corda su tendinea su P2, plastica di scivolamento del papillare PM secondo Dreyfuss, impianto Edwards Physio n.32

All'uscita dal bypass CP riscontro di SAM poi risoltosi con terapia conservativa medica (stop inotropi, aumento riempimento ventricolare)

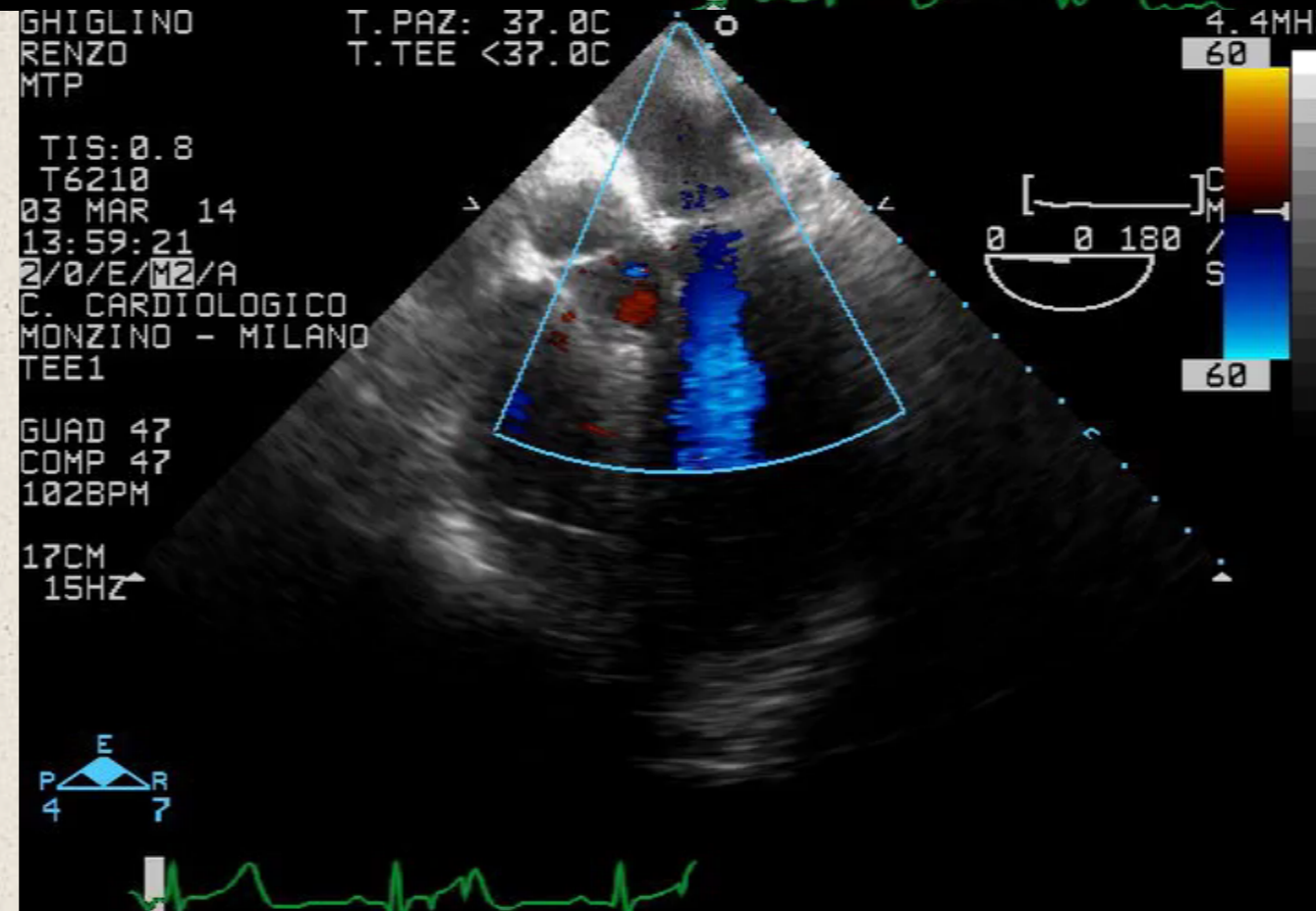
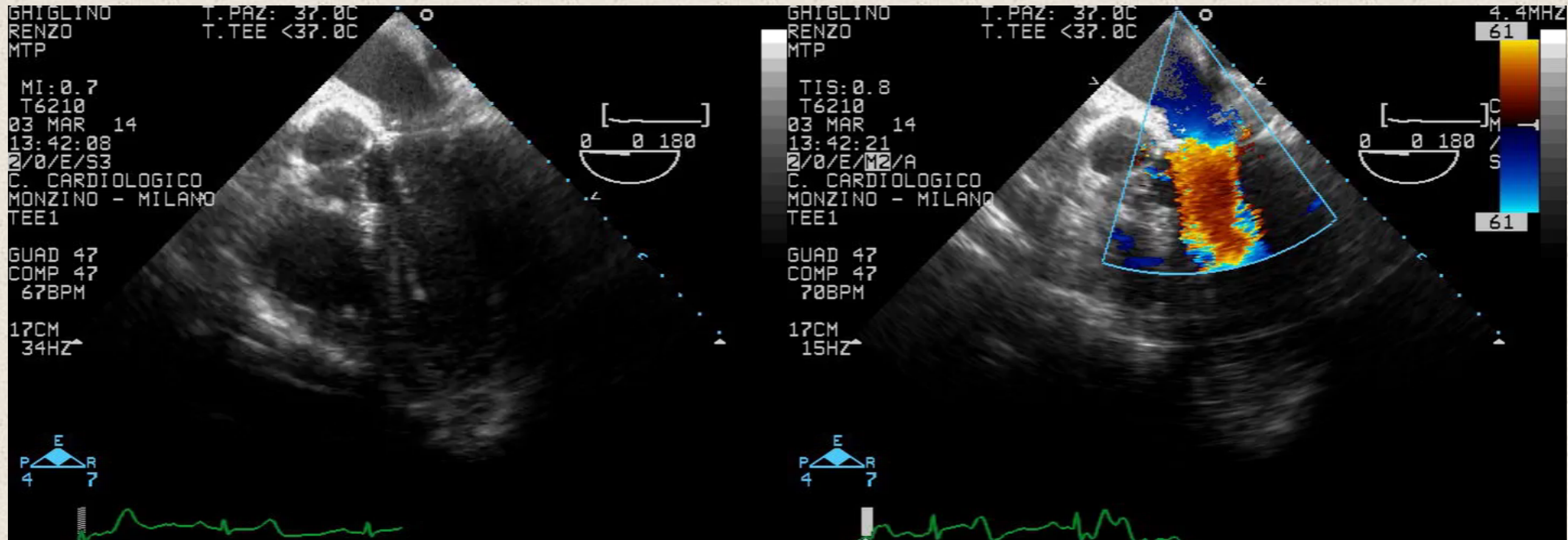


Intra-operative


Systolic Anterior Motion Clinical case 1



VII CONGRESSO DI ECOCARDIOCHIRURGIA



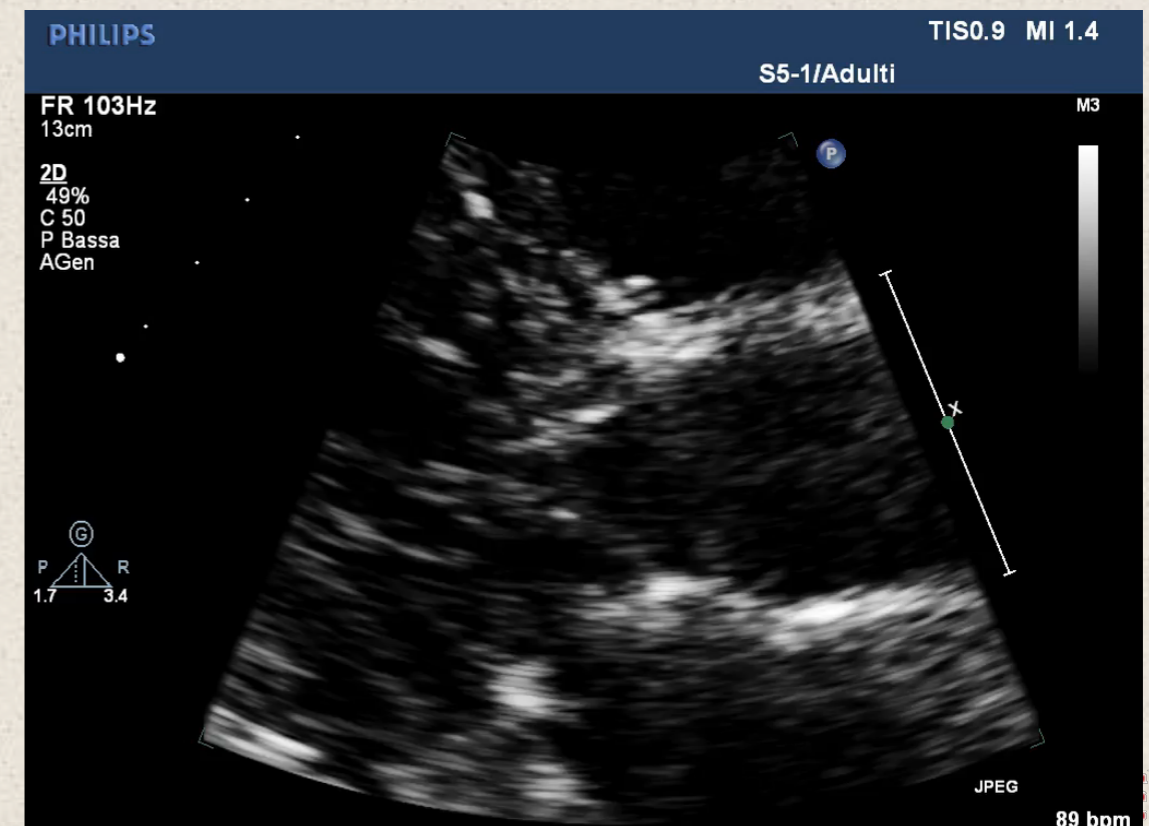
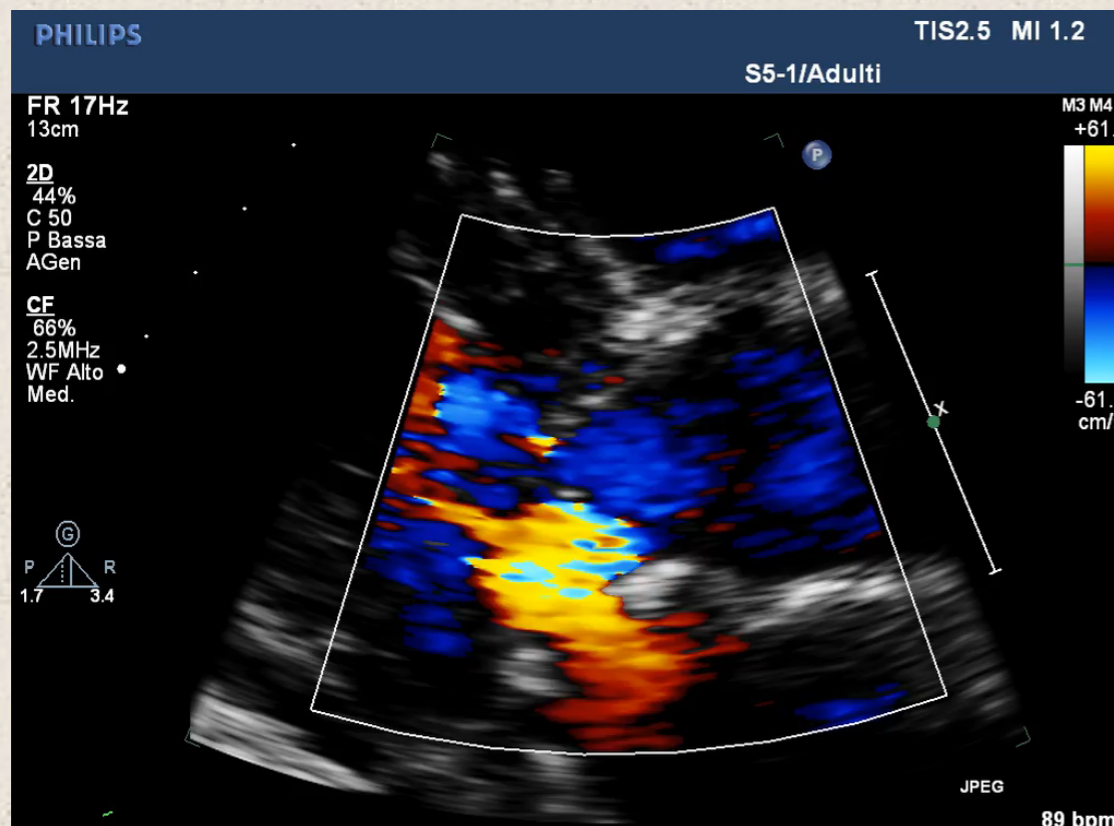
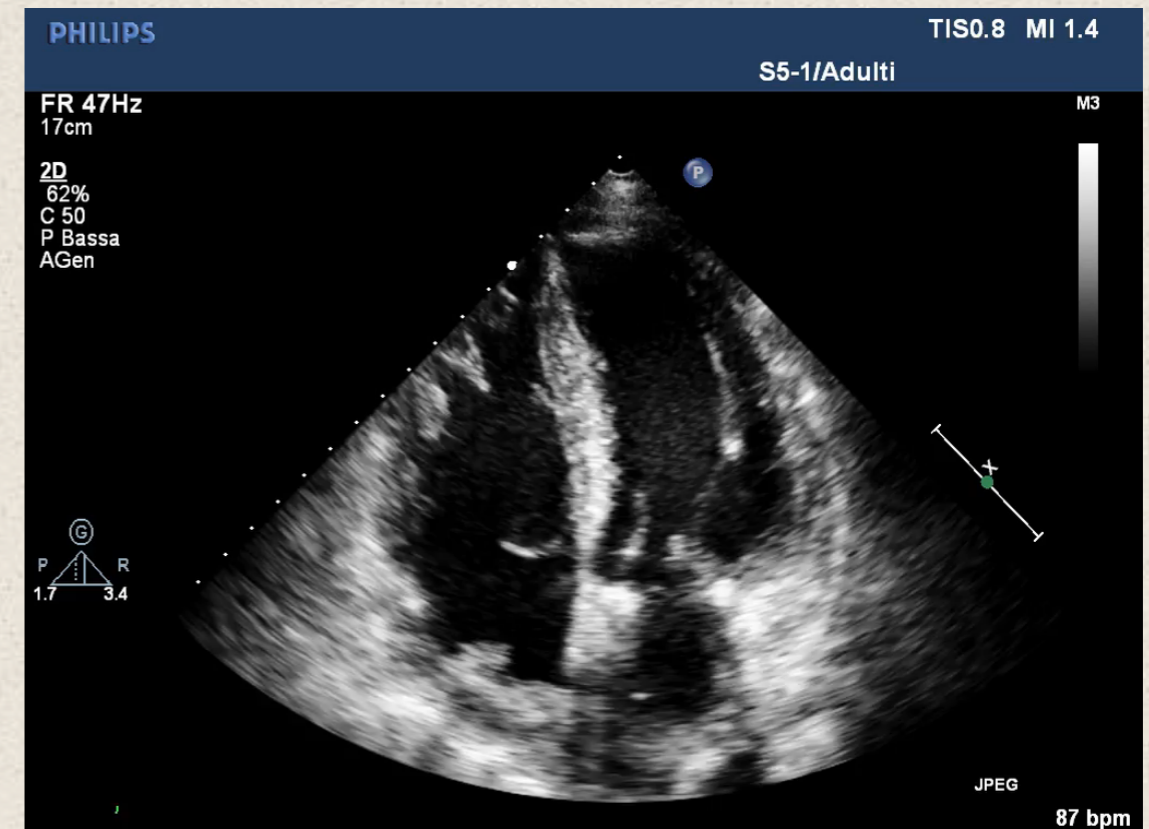
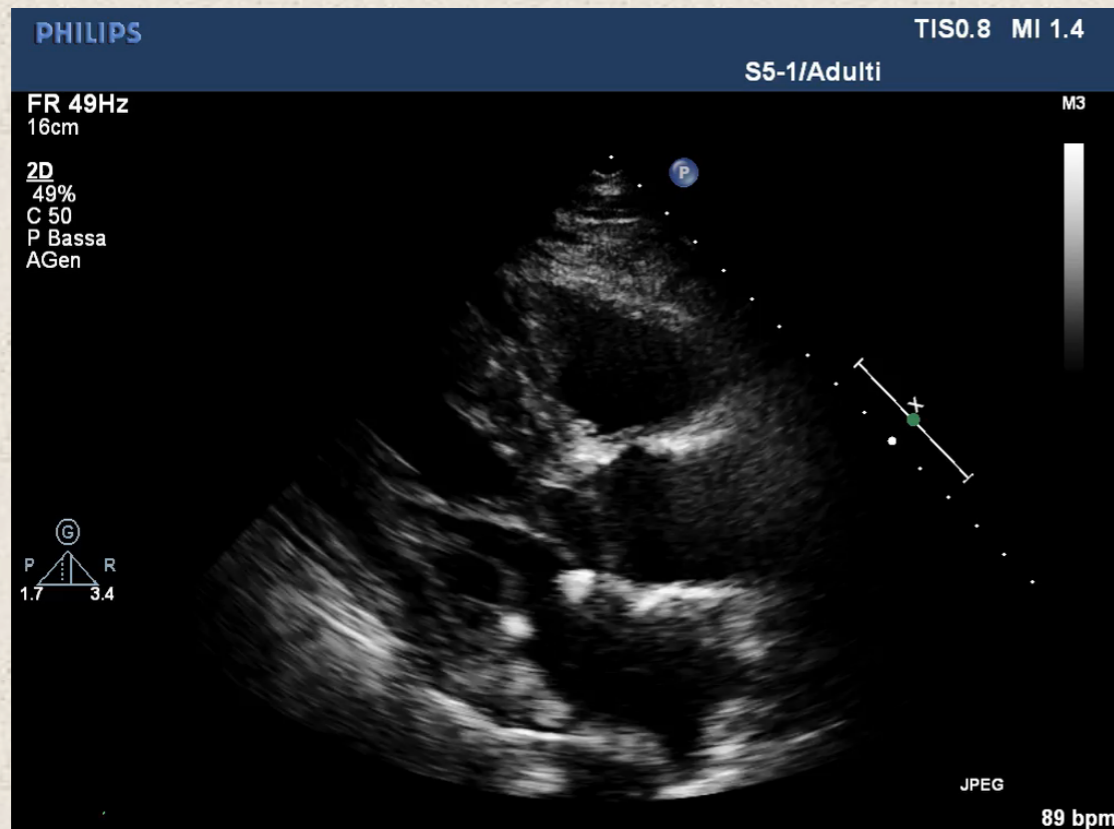
Intra-operative



Systolic Anterior Motion Clinical case 1



At discharge




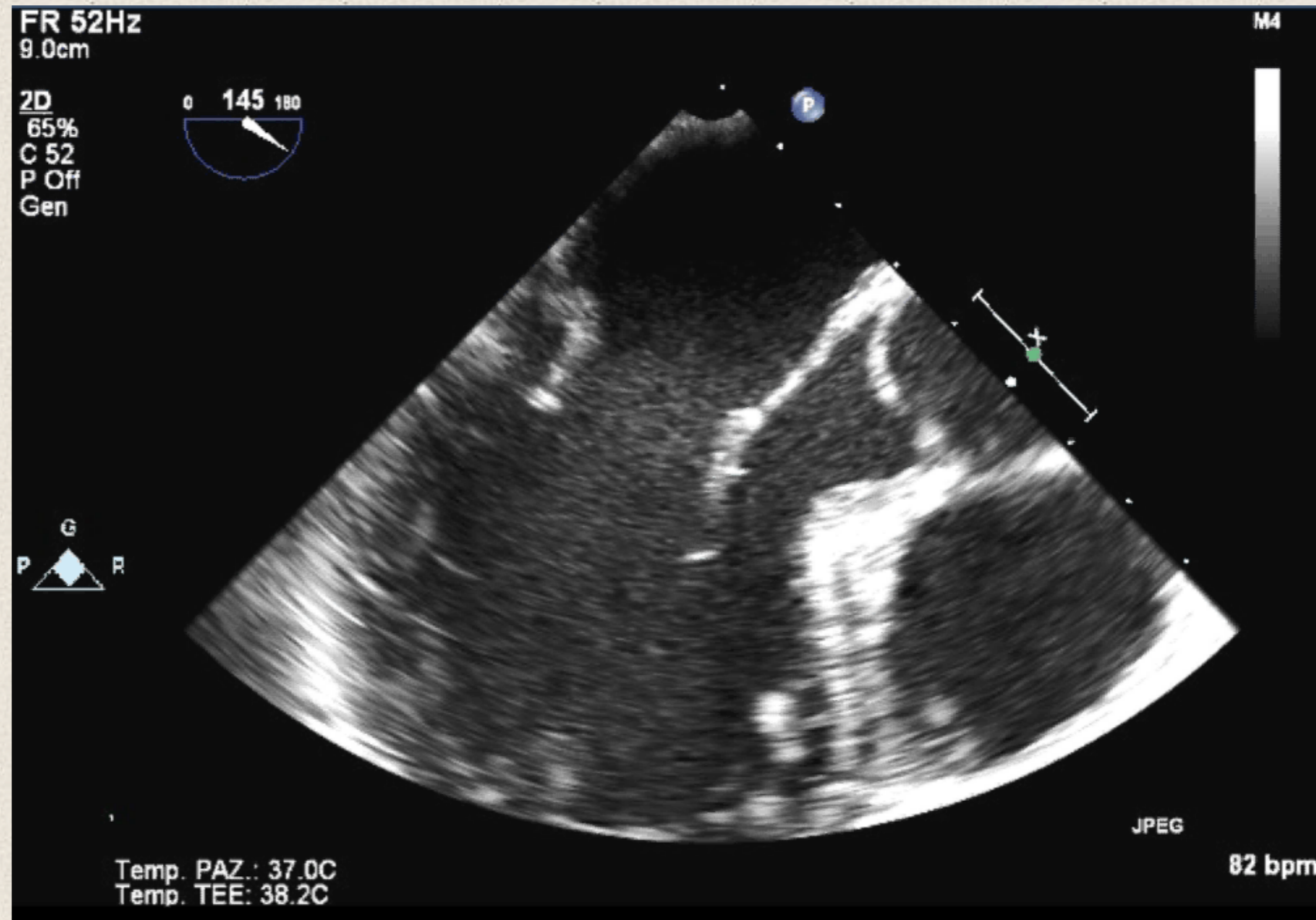
Systolic Anterior Motion Clinical case 2



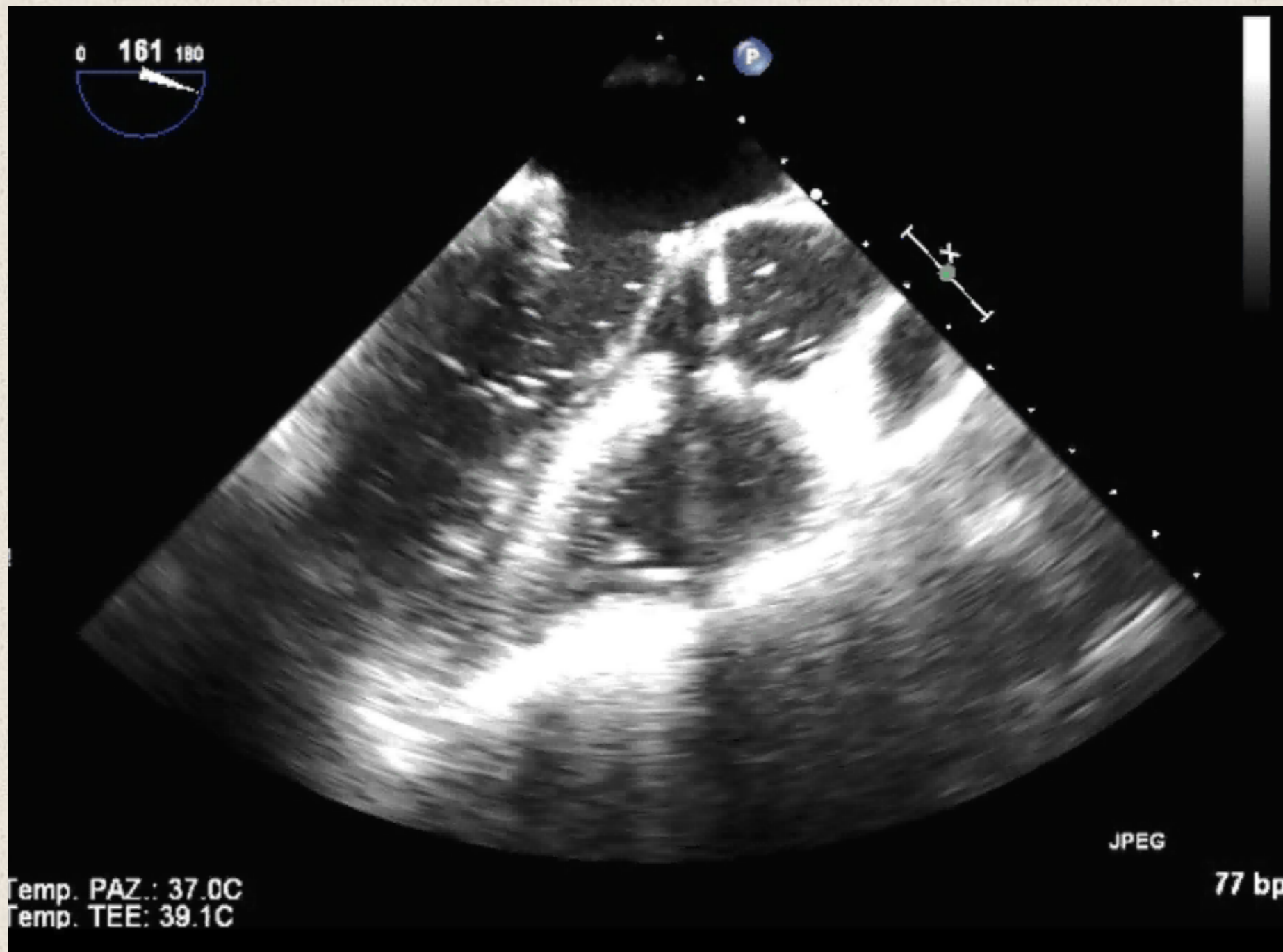
VII CONGRESSO DI ECOCARDIOCHIRURGIA

Paziente di 59 aa. , anamnesi negativa per FdR cardiovascolare, non patologie maggiori, nota per PM.

ECO TT 3D: lieve dilatazione dell'atrio sinistro e dell' anello mitralico (37 x 36 mm), ispessimento dei lembi mitralici, **ampio prolasso del lembo posteriore con piccola rottura cordale ed eversione della scallop P2** che condiziona **rigurgito severo** (EROA 0,5) direzionato medialmente e anteriormente; dilatazione ventricolare sinistra con normale funzione sistolica; normali dimensioni del settore dx.

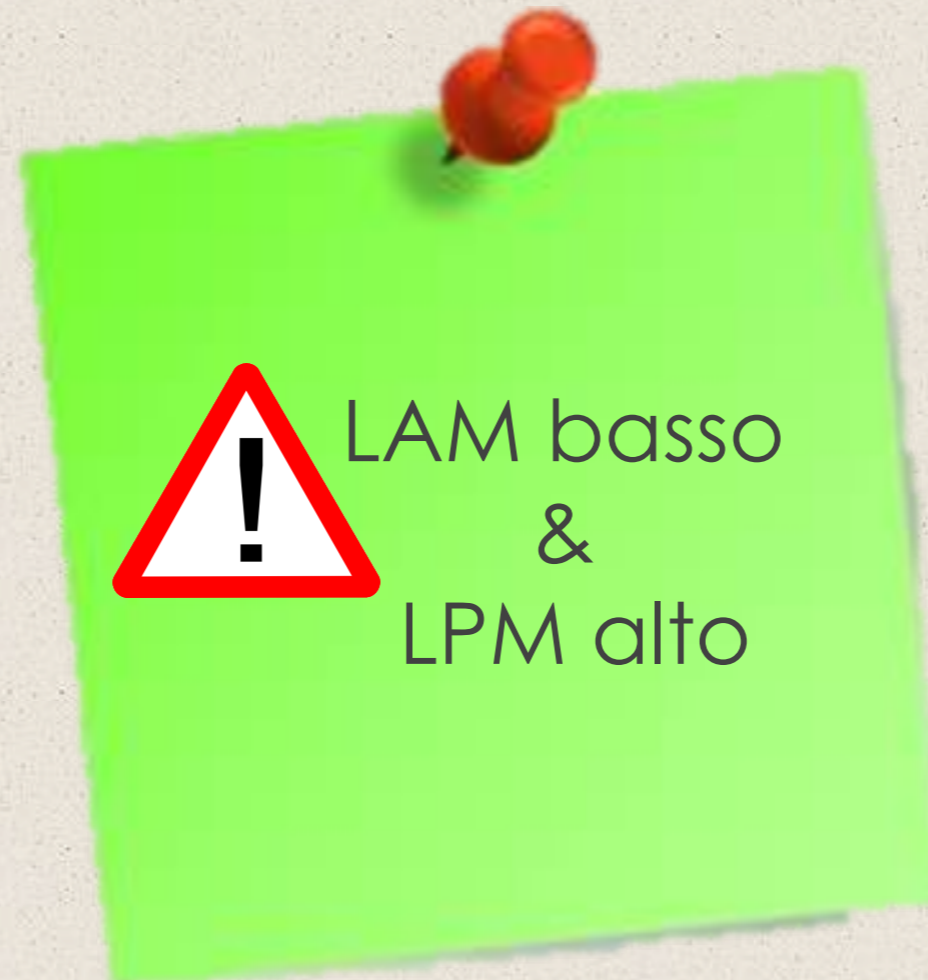

MVR sternotomia mediana, bypass cardiopolmonare con
Resezione quadrangolare P2 con impianto Edwards Physio n.32
All'uscita dal bypass CP riscontro di SAM severo con *necessità di correzione chirurgica.*




how to correct it?

- **Verificare anello:** misura/tipo
- **Plastica del lembo posteriore/corde tendinee** per abbattere LPM
- Valutare la **sostituzione valvolare** in base a:
 - età
 - rischio di prolungamento di CEC

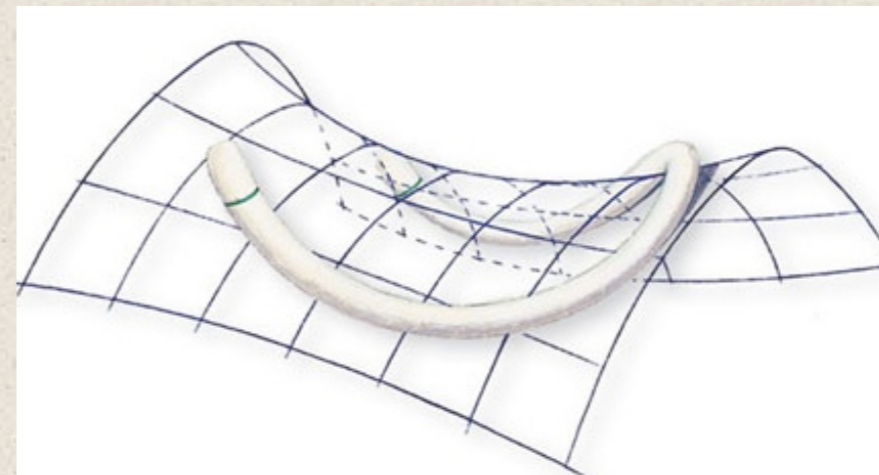
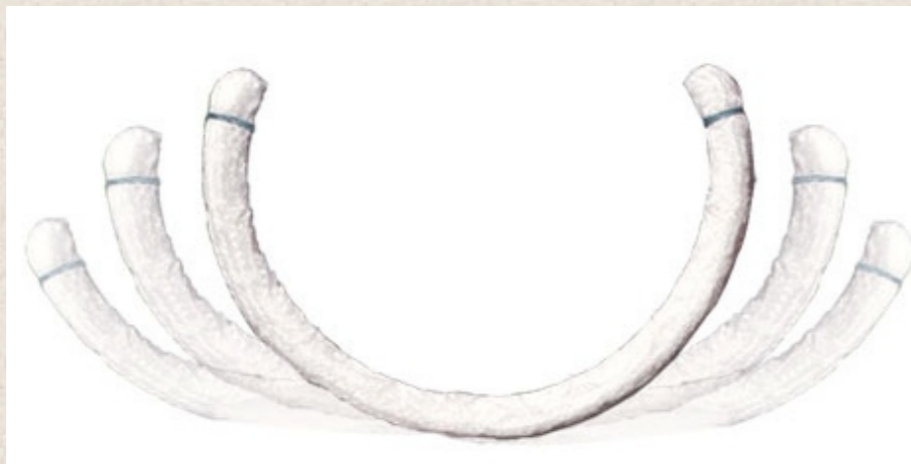

how to correct it?

Rimozione anello protesico completo (C-E Physio n.32)



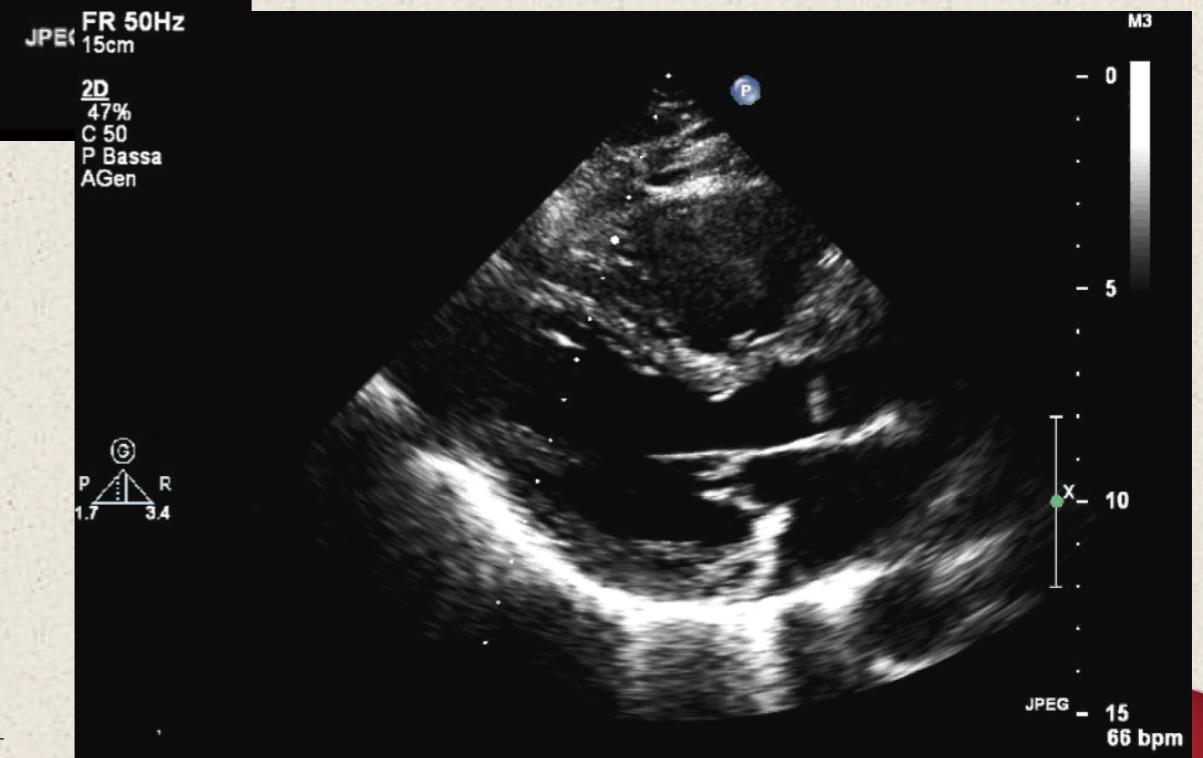
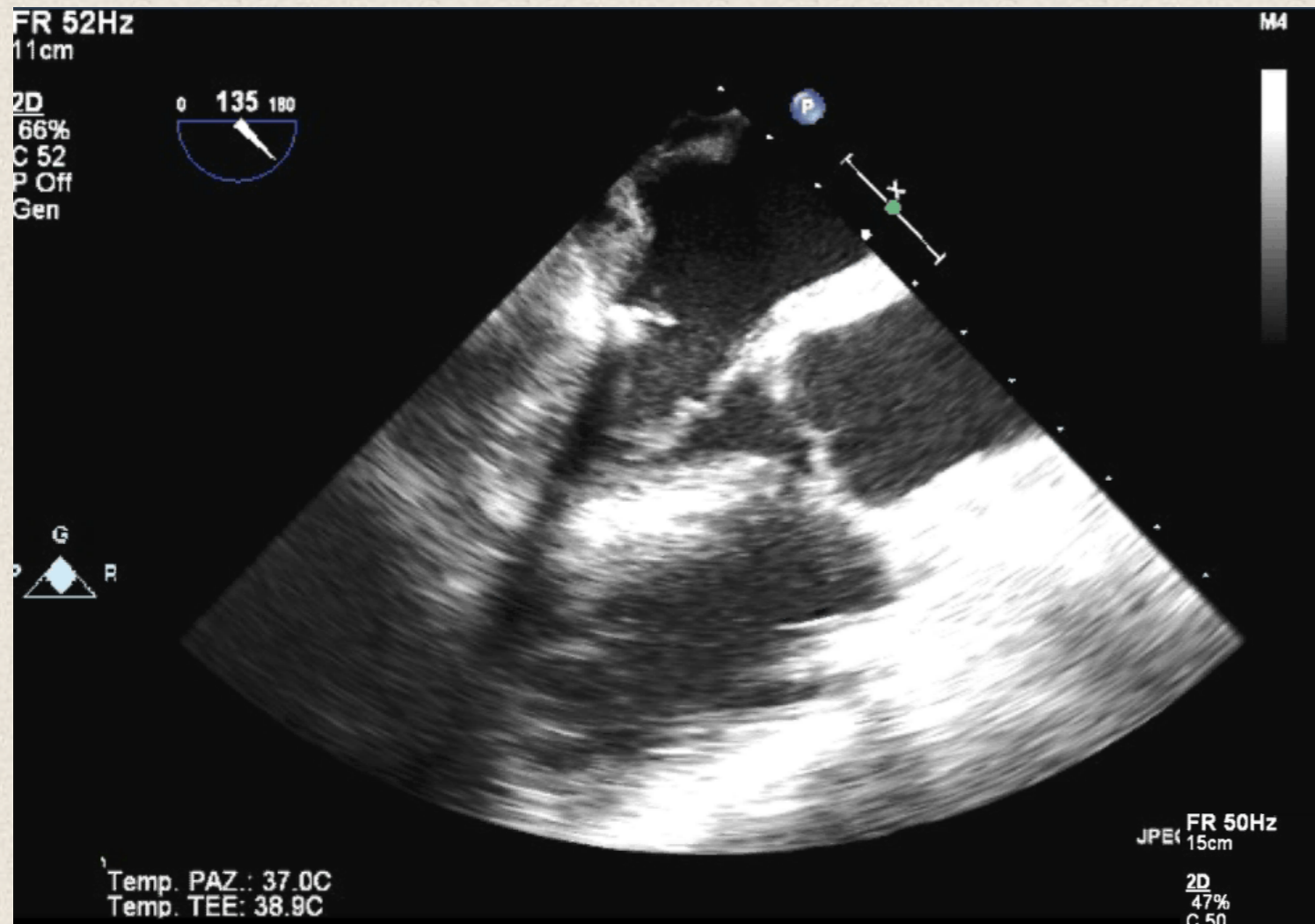
impianto di anello incompleto E-Cosgrove n.32



Systolic Anterior Motion Clinical case 2



Post-operatorio



FU a 3 anni



REAL PROBLEM:

everything OK but evidence of **SAM at the discharge..**



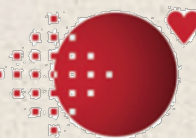
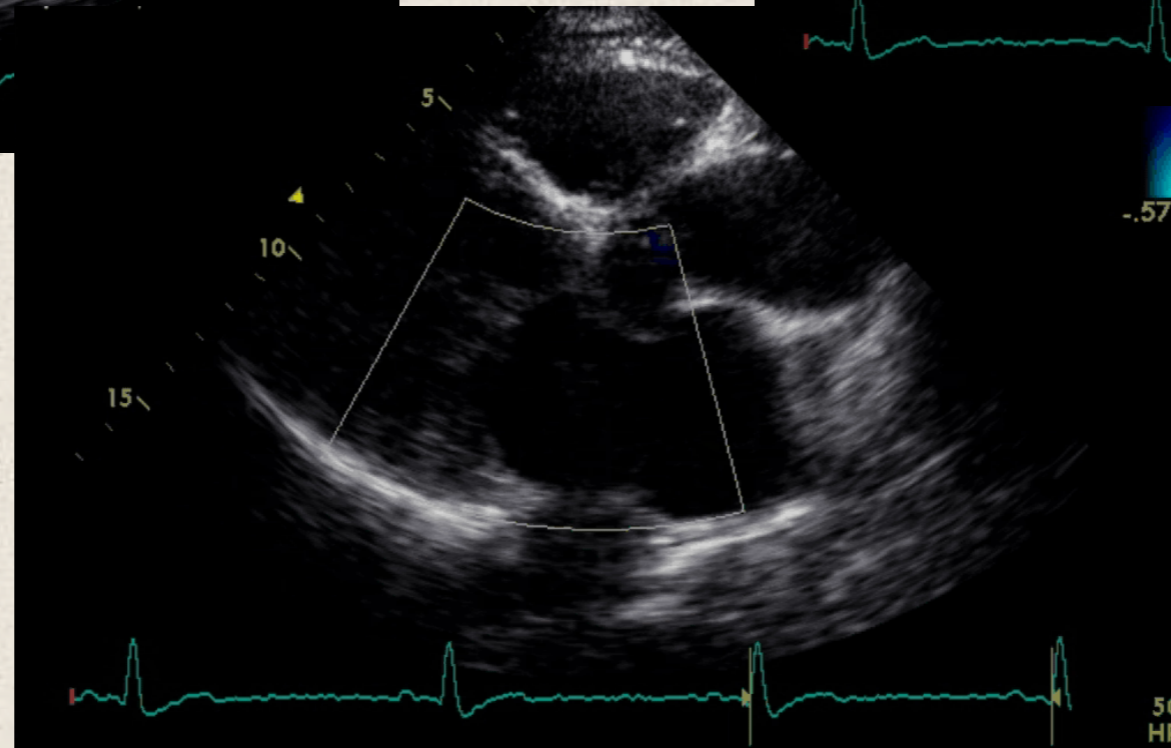
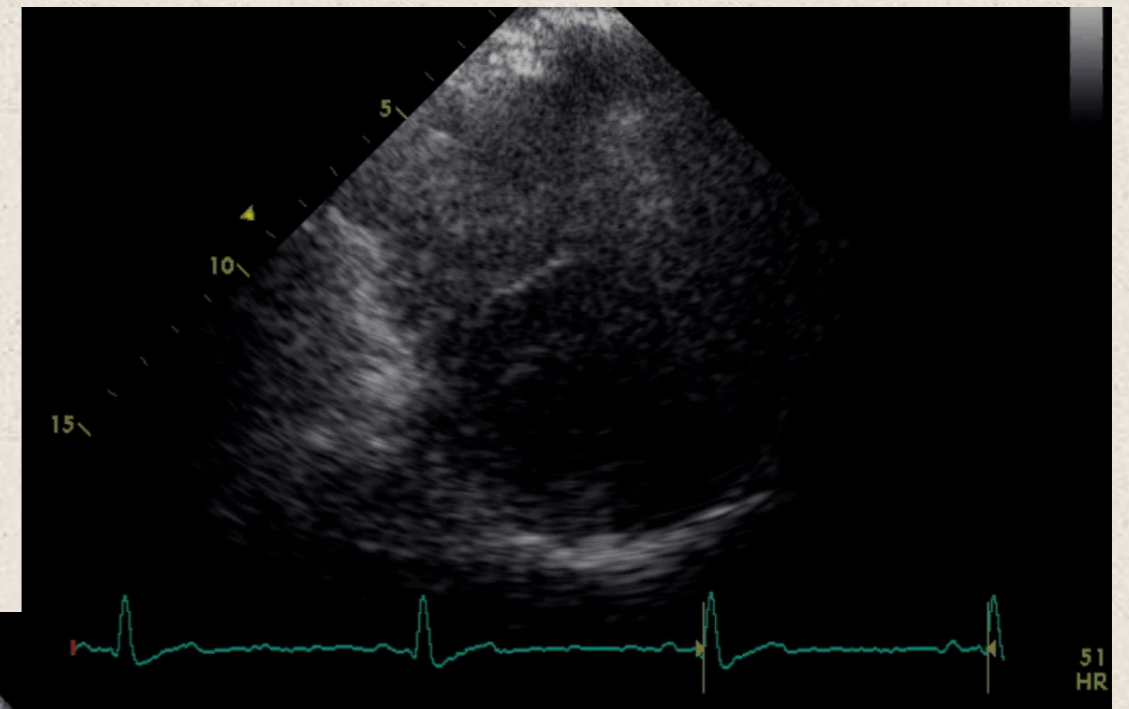
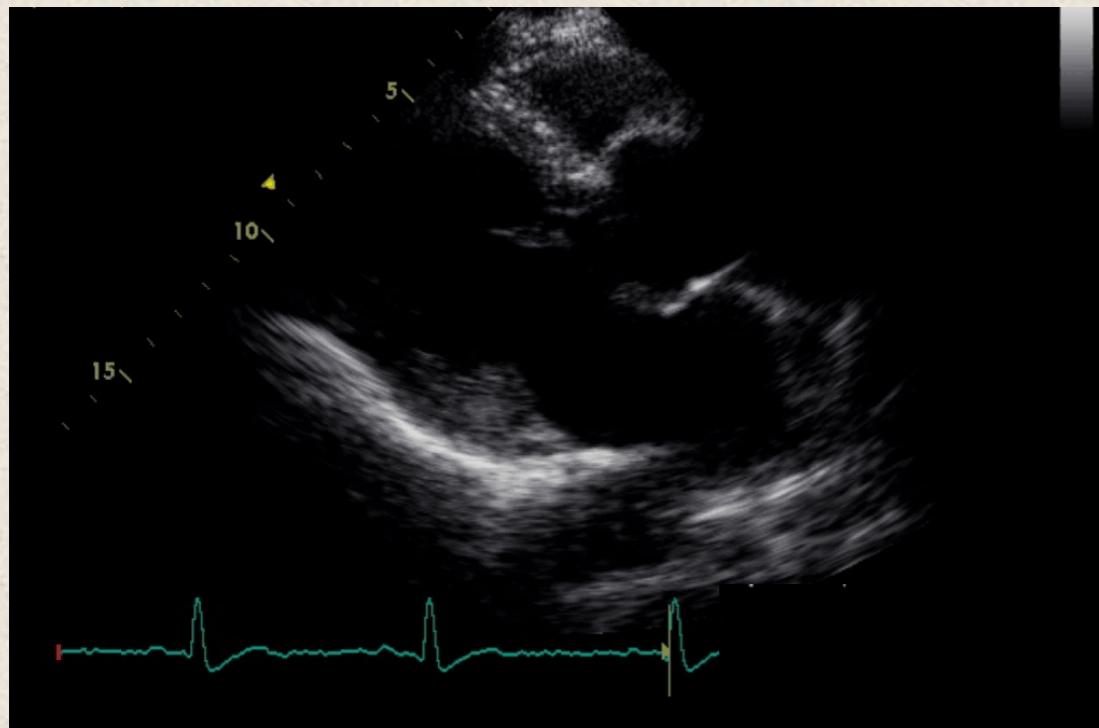
Systolic Anterior Motion Clinical case 3



VII CONGRESSO DI ECOCARDIOCHIRURGIA

Paziente di 70aa., anamnesi negativa per FdR cardiovascolare, cirrosi potus-correlata in presenza di varici esofagee.

ECO TT: valvola mitrale ispessita, mixomatosa; **prolasso dello scallo centrale di entrambi i lembi (P2 e A2), con flail e rottura di piccola corda**, condizionante insufficienza di grado severo (ampia dispersione del jet, EROA 0,6 cm²). Severa dilatazione dell'atrio. FE 69%



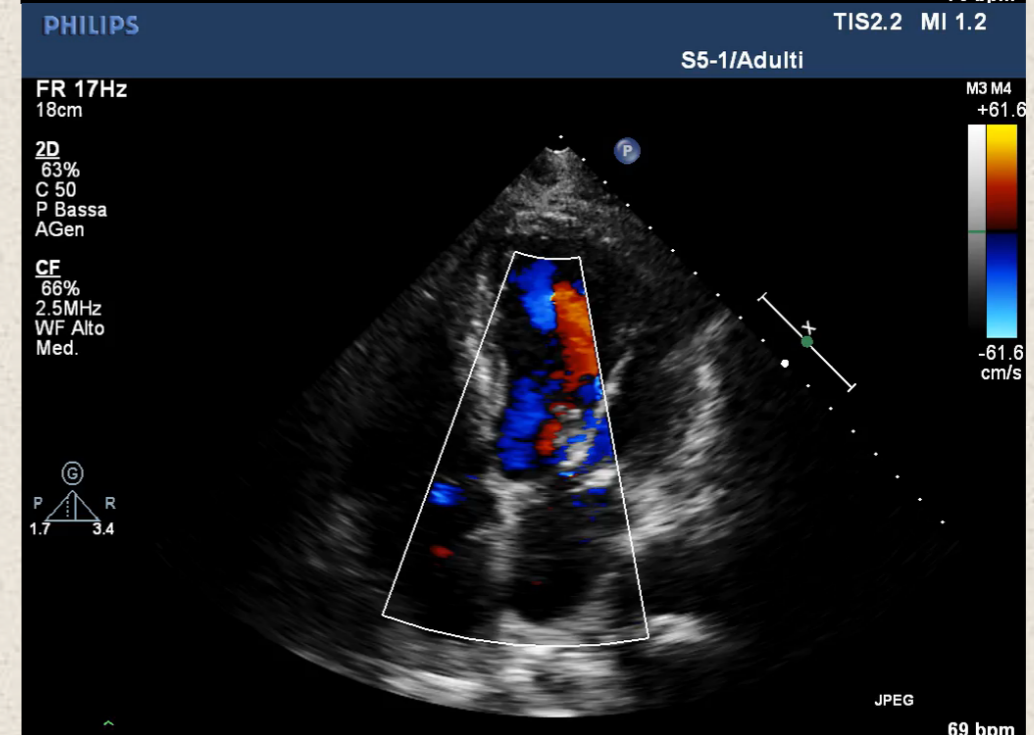
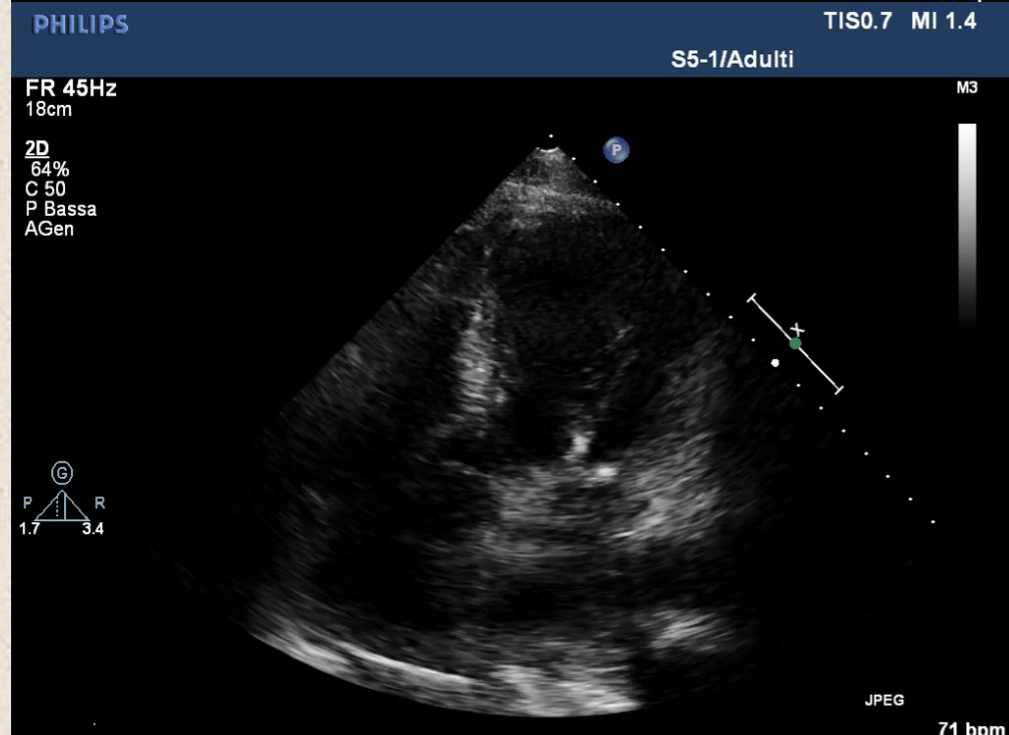
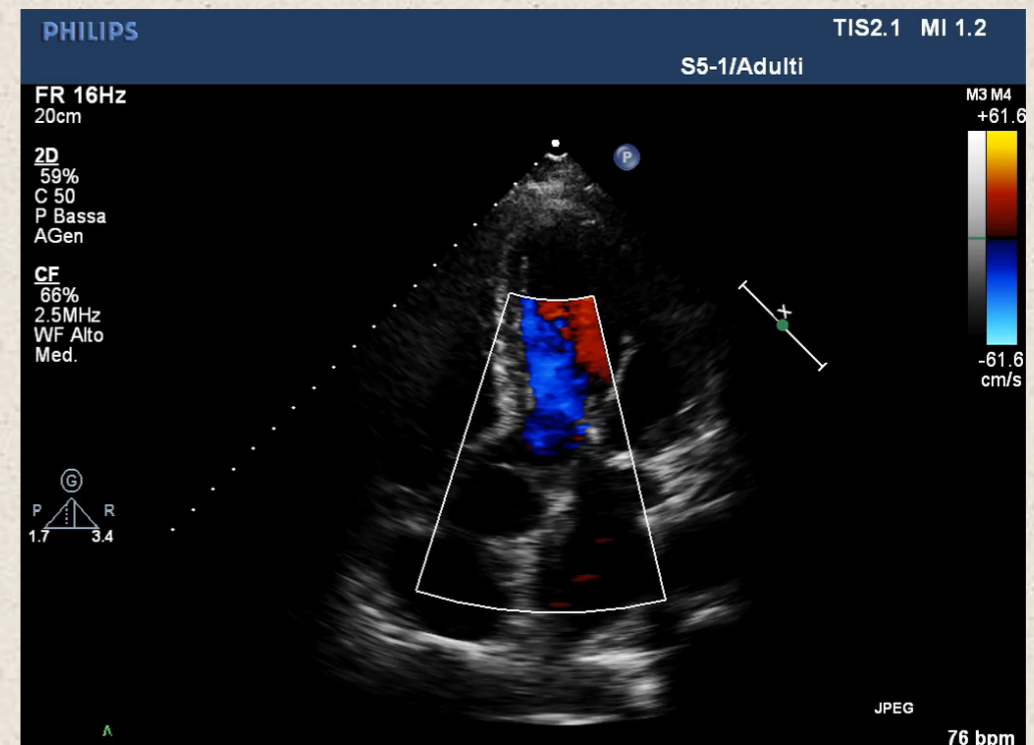
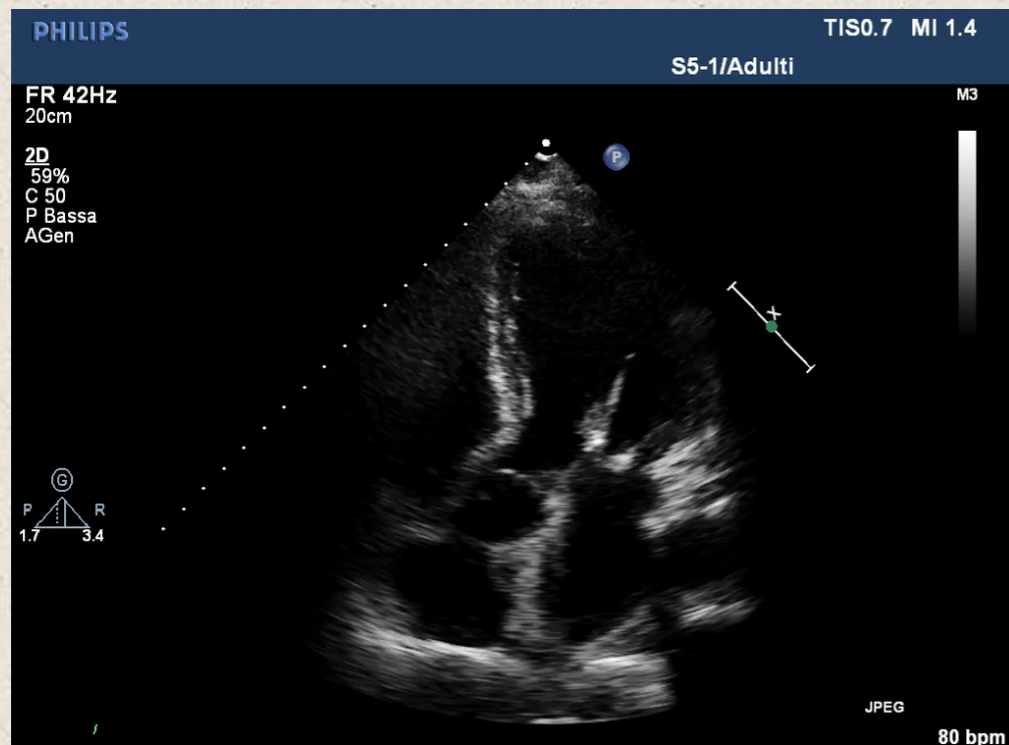
MVRepair:

sternotomia mediana, bypass cardiopolmonare.
Riscontro di prolasso di P2 con rottura cordale.

***Impianto di corda tendinea su P2,
posizionamento Cosgrove Ring n.32***

At the predimission echo:

Riscontro di **SAM del lembo anteriore** (gradiente DP max 13mmHg)
non condizionante significativa ostruzione del LVOT



TAKE HOME MESSAGE

- **Speaking the same language**
(uniformity to highlight risk factors of SAM)
- **Intraoperatively SAM is always around the corner**
(and often it's not the fault of the patient...)
- During MV repair **remember to move coaptation point towards LPM** and pay attention **LAM/LPM ratio**
- **For experienced cardiac surgeon intraoperative SAM is usually easy to correct**, but consider replacement
(not well defined mechanism, risk factors,..)